



## **Hepatic Artery Mycotic Aneurysm and Microabscesses: A Rare Complication of Infective Endocarditis with Classical Quincke's Symptom**

**Fahd Haroon<sup>1</sup>, Shayan Sirat Maheen Anwar<sup>1\*</sup>, Rujmaan Lodhi<sup>1</sup>  
and Syed Mahmood<sup>1</sup>**

<sup>1</sup>Karachi X-rays and CT Scan Centre, M. A. Jinnah Road, Karachi, Pakistan.

### **Authors' contributions**

*This work was carried out in collaboration between all authors. Author RL wrote the draft of the manuscript. Author SSMA managed the literature searches. Author SSMA designed the figures, managed literature searches and contributed to the correction of the draft. Author FH provided the case, the figures and author SM supervised the work. All authors read and approved the final manuscript.*

### **Article Information**

DOI: 10.9734/IJMPCR/2015/16426

#### Editor(s):

(1) Rakesh Kumar Tiwari, Chapman University School of Pharmacy, Chapman University, Harry and Diane Rinker Health Sciences Campus, Irvine, CA, USA.

#### Reviewers:

- (1) Anonymous, Spain.  
(2) Massimo Slavich, Division of Cardiology, San Raffaele University Hospital, Via Olgettina 58, 20100 Milan, Italy.  
(3) Rocio Santos Rancaño, San Carlos Clinic Hospital of Madrid, Complutense University of Madrid, Spain.  
Complete Peer review History: <http://www.sciencedomain.org/review-history.php?iid=886&id=38&aid=8442>

**Case Study**

**Received 1<sup>st</sup> February 2015**  
**Accepted 3<sup>rd</sup> March 2015**  
**Published 13<sup>th</sup> March 2015**

### **ABSTRACT**

Hepatic artery branch mycotic aneurysm causing intrahepatic biliary dilatation and associated with hepatic micro abscesses is a rare complication of infective endocarditis and patient presenting with classical Quincke's symptoms has not been reported in literature so far.

We report a case of 38 years old woman who presented with epigastric pain and obstructive jaundice. She has recently been diagnosed to have infective endocarditis. Hepatic artery pseudoaneurysm causing moderate intrahepatic biliary dilatation and micro abscesses was reported on contrast enhanced computed tomography (CT) scan and immediately conveyed to primary physician which led to successful selective transcatheter arterial embolization of the aneurysm, leading to early stabilization and recovery of the patient.

\*Corresponding author: E-mail: [shayan.sirat@gmail.com](mailto:shayan.sirat@gmail.com);

**Keywords:** *Infective endocarditis; hepatic artery pseudoaneurysm; computed tomography.*

## 1. INTRODUCTION

Hepatic artery mycotic aneurysm is an uncommon vascular complication of bacterial endocarditis, which if neglected can be life threatening. Embolisms are a serious complication of infective endocarditis and occur in some 22%-55% of all episodes [1]. Septic emboli in a viscera cause constant inflammatory process which results in erosion of arterial wall and formation of pseudo aneurysm. The mycotic aneurysm in liver may get large enough to cause obstruction of the biliary ducts and hemobilia. Compression of cystic duct and gall bladder distension can also occur. This abnormality can give classical Quincke's symptom of epigastric pain, obstructive jaundice and hemobilia as described in our case.

## 2. CASE DESCRIPTION

A 38 years old woman presented with complaints of right hypochondriac pain, obstructive jaundice, and fever. She had significant past history of rheumatic heart disease and was suspected to have infective endocarditis. On physical examination, she was anemic with yellow sclera and right subcostal tenderness. She had tachycardia with no definite cardiac murmur. Recent lab investigations showed WBC 14 (4 – 10.0 x 10<sup>9</sup>/L), Hemoglobin 8 (11.7-14.3) gm/dl, Total bilirubin 3.0 (0-1) mg/dl, Direct bilirubin 1.7(0-0.2) mg/dl, Alkaline phosphatase 225 (35-105) U/L, Gamma GT 622 (10-50) U/L. Chest X-ray: no lung pathology. ECG: no acute ischemic changes. Bedside echocardiogram showed large vegetations on mitral valve. No valvular complication documented. Preliminary diagnosis of septic emboli was made and patient immediately underwent contrast enhanced CT abdomen and pelvis. Imaging revealed a large 3.5x3.0 cm mycotic aneurysm arising from right hepatic artery branch, which was projecting in the biliary tree and was causing moderate intrahepatic biliary dilatation. At the same time it was obstructing the cystic duct with gall bladder distension. Multiple micro abscesses were also reported within the liver parenchyma (Fig. 1). Rest of the abdominal viscera were normal. Patient was urgently prepared for selective angiography and embolization under cover of empirical high dose antibiotic. Pseudo aneurysm was identified and successfully embolized with no complication. Patient underwent ultrasound liver after 24 hours and there was marked

improvement in biliary obstruction. No colour flow was demonstrated within the aneurysm. Patient was discharged after 72 hours in stable condition with instruction to follow with infectious disease.

## 3. DISCUSSION

Mycotic aneurysm is described as an infectious break in the wall of an artery causing formation of a blind, saccular, out pouching, which communicates with the arterial lumen. Aorta is the most common site of involvement followed by peripheral artery, cerebral artery, and visceral arteries [2]. Among the visceral arteries, liver is one of the involved organ [3]. Mycotic hepatic artery aneurysm (HAA) is an uncommon vascular pathology accounting for 0.1% of all arterial aneurysms and 20% of all visceral aneurysms [4].

In 1892, Hale-White was the first to report clinical triad of hepatic artery aneurysm. The triple signs comprised of right upper quadrant pain, gastrointestinal hemorrhage, and jaundice which is still used today as a diagnostic feature of hepatic artery aneurysms [5,6,7]. Similar was the presentation in our patient, which is coined as Quincke's symptoms in the literature and typically occurs in one third of the patients [8,9].

Aneurysm of right hepatic artery (RHA) can erode into the biliary track due to close proximity of this artery with common hepatic duct, this explain the reason of hemobilia, as observed in our patient in whom branch of RHA was involved and eroding into the biliary tree[10,11,12,13]. Hemobilia was undocumented in our patient as no ERCP or stool for occult blood was performed, however significant drop of hemoglobin from baseline 12 mg/dl to 8 mg/dl was highly suggestive of hemobilia.

Hepatic artery aneurysms have the highest rate of rupture (44%) among the splanchnic circulation, though its occurrence is only 20% of the true visceral aneurysms [14].

A study by Shanley et al. [15], mentioned mortality rate of 21 percent after rupture of hepatic artery aneurysm. About 10 per cent of patients suffer from hypovolemic shock from rupture of HAA [16]. Peritoneal hemorrhage is a feature of extrahepatic aneurysm, however intrahepatic aneurysms more frequently rupture into the biliary tree, a factor responsible for

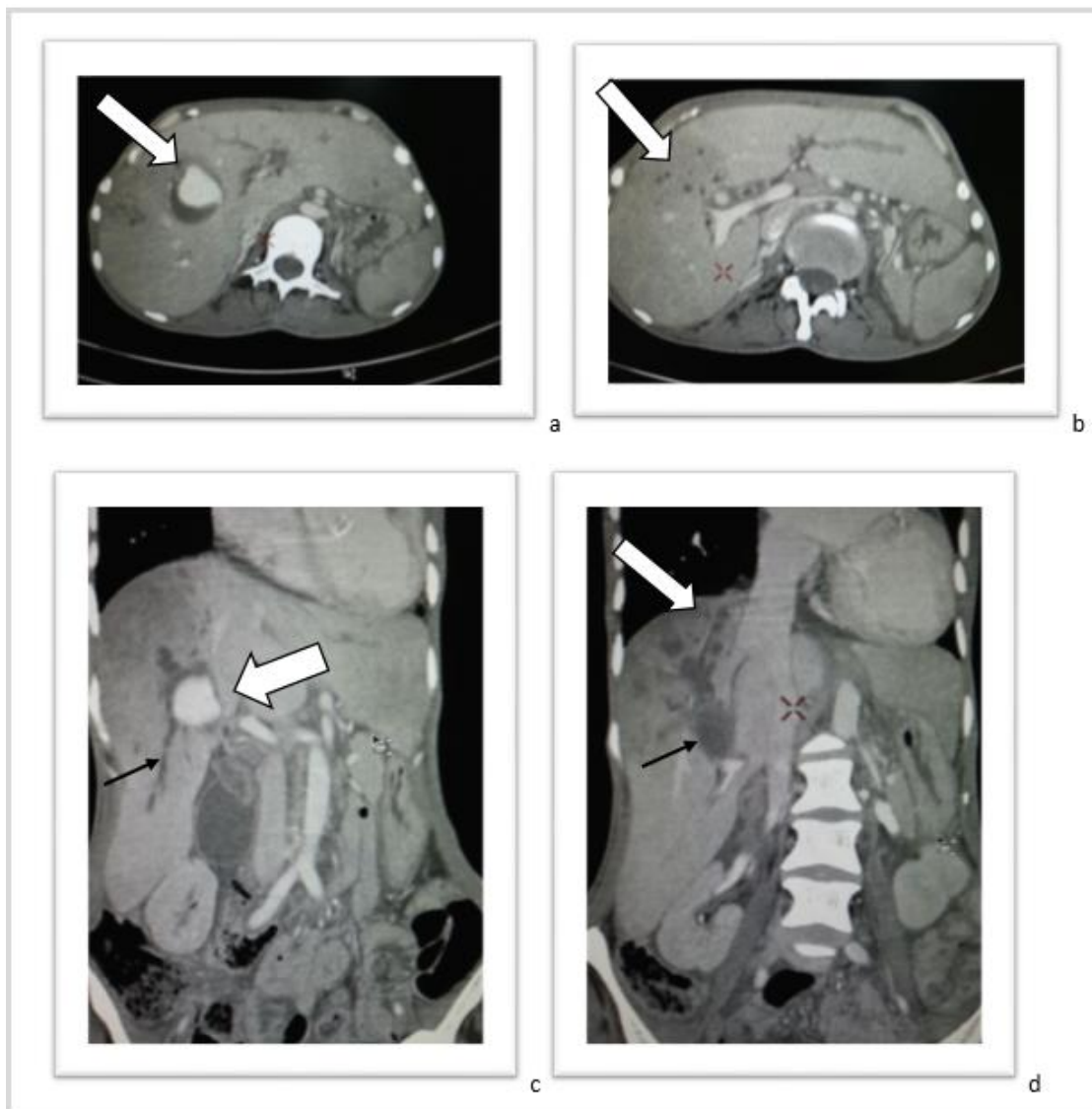
Quinke's triad of pain, jaundice, and hemobilia [16].

Due to recent advances in CT technology, its accuracy in reporting even the smallest of aneurysms has become equivalent to angiography as the method of choice for the diagnosis of visceral aneurysms [17].

Multidetector CT scans with CT angiography is an excellent modality for providing clinicians with

important details regarding anatomical variations, collateral circulation, and the relation between the aneurysm and its adjacent arteries [17].

Hepatic artery aneurysm measuring above 2 cm, generally requires treatment [18]. Percutaneous transcatheter embolization with metallic coils is the treatment of choice, since it is less invasive compared to surgery and is associated with low morbidity, having success rate of 85 percent [18,19].



**Fig. 1. CT scan findings: Axial (a) and coronal (c) images on left, reveal aneurysmal dilatation of hepatic artery compressing the biliary system. (White arrow). Axial (b) and coronal (d) images on right, low attenuation rounded areas in liver represent small abscesses. (White arrow). Coronal (c and d): intrahepatic biliary dilatation (Black arrow)**

#### 4. CONCLUSION

No matter rare, aneurysms of the hepatic artery have been well documented in the literature. Because of the life-threatening nature of this condition, the clinicians must be aware of the symptoms and presentation of hepatic artery aneurysms. Recent advances in CT technology have made diagnosis easier and prompt, leading to early treatment and better prognosis.

#### CONSENT

It is not applicable.

#### ETHICAL APPROVAL

It is not applicable.

#### COMPETING INTERESTS

Authors have declared that no competing interests exist.

#### REFERENCES

1. Bayer AS, Bolger AF, Taubert KA, Wilson W, Steckelberg J, Karchmer AW, et al. Diagnosis and management of infective endocarditis and its complications. *Circulation*. 1998;98:2936-48.
2. Lee WK, Mossop PJ, Little AF, et al. Infected (mycotic) aneurysms: spectrum of imaging appearances and management. *Radiographic*. 2008;28(7):1853-68.
3. Messina LM, Shanley CJ. Visceral artery aneurysms. *Surg Clin North Am*. 1997;77(2):425-42.
4. Kim GA, Lee HC, Jin YJ, et al. A case of ruptured mycotic hepatic artery aneurysm successfully treated using arterial embolization. *Yeungnam University Journal of Medicine*. 2012;29(1):24-27.
5. Oser L, Neusser E, Quincke H, Hoppe-Seyler G. *Diseases of the Liver and the Pancreas and Suprarenal Capsules*. 1903;896.
6. Ariyan S, Cahow CE, Greene FL, Stansel HC. Successful treatment of hepatic artery aneurysm with erosion into the common duct. *Ann Surg*. 1975;182:169-72.
7. Bach AG, Abbas J, Schramm D, et al. An unusual cause of jaundice. *Am J Med*. 2012;125(7):e7-8.
8. Harlaftis NN, Akin JT. Hemobilia from ruptured hepatic artery aneurysm: report of a case and review of the literature. *American Journal of Surgery*. 1977;133(2):229-232.
9. Stauffer JT, Weinman MD, Bynum TE. Hemobilia in a patient with multiple hepatic artery aneurysms: a case report and review of the literature. *American Journal of Gastroenterology*. 1989;84(1):59-62.
10. Pasha SF, Gloviczki P, Stanson AW, Kamath PS. Splanchnic artery aneurysms. *Mayo Clin Proc*. 2007;82:472-9.
11. Standring S. Section 8: abdomen and pelvis. Liver, Chap 68. In: *Gray's Anatomy*, 40<sup>th</sup> Ed. New York: Elsevier Churchill Livingstone. 2005;1169-70.
12. Stack BH, Rankin JT, Bentley RJ. Hepatic artery aneurysm after staphylococcal endocarditis. *BMJ*. 1968;3:659-60.
13. Wagner WH, Allins AD, Treiman RL, et al. Ruptured visceral artery aneurysms. *Ann Vasc Surg*. 1997;11:342-7.
14. Arneson MA, Smith RS. Ruptured hepatic artery aneurysm: case report and review of literature. *Ann Vasc Surg*. 2005;19:540-5.
15. Shanley CJ, Shah NL, Messina LM. Common splanchnic artery aneurysms: splenic, hepatic, and celiac. *Ann Vasc Surg*. 1996;10:315-22.
16. O'Driscoll D, Olliff SP, Olliff JF. Hepatic artery aneurysm. *Br J Radiol*. 1999;72:1018-25.
17. Kim JH, Rha SE, Chun HJ, et al. Giant aneurysm of the common hepatic artery: US and CT imaging findings. *Abdom Imaging*. 2010;35:212-4.
18. Pasha SF, Gloviczki P, Stanson AW, Kamath PS. Splanchnic artery aneurysms. *Mayo Clin Proc*. 2007;82:472-9.
19. Leung JL, Kan WK, Cheng SC. Mycotic cystic artery pseudoaneurysm successfully treated with transcatheter arterial embolisation. *Hong Kong Med J*. 2010;16(2):156-7.

© 2015 Haroon et al.; This is an Open Access article distributed under the terms of the Creative Commons Attribution License (<http://creativecommons.org/licenses/by/4.0>), which permits unrestricted use, distribution, and reproduction in any medium, provided the original work is properly cited.

Peer-review history:

The peer review history for this paper can be accessed here:

<http://www.sciencedomain.org/review-history.php?iid=886&id=38&aid=8442>