



Esthetic Rehabilitation with Zirconia Based Crowns

Nissaf Daouahi^{1*}, Dalenda Hadyaoui¹, Jilani Saafi¹ and Mounir cherif¹

¹Department of Prosthetic Dentistry, Monastir University, Tunisia.

Authors' contributions

This work was carried out in collaboration between all authors. Authors ND and DH contributed equally to writing, correcting the manuscript, managed literature searches and provided the case. Authors JS and MC supervised the draft and provided the necessary material. All authors read and approved the final manuscript.

Article Information

DOI: 10.9734/IJMPCR/2015/16225

Editor(s):

(1) Rakesh Kumar Tiwari, Chapman University School of Pharmacy, Chapman University, Harry and Diane Rinker Health Sciences Campus, Irvine, CA, USA.

Reviewers:

(1) Daniela Martins de Souza, School of Dentistry, Pindamonhangaba College (FAP), Christian Life University Foundation (FUNVIC), Pindamonhangaba, SP, Brazil.

(2) Anonymous, Palestinian.

(3) S. Rajendran, Corrosion Research Centre, Department of Chemistry, RVS School of Engg and Technology, Dindigul-624005, India.

Complete Peer review History: <http://www.sciencedomain.org/review-history.php?id=886&id=38&aid=8393>

Case Report

Received 16th January 2015
Accepted 16th February 2015
Published 11th March 2015

ABSTRACT

This article describes a case of discolored central incisors treated by using Zirconia based crowns. A 25 year old female patient presented to the department of Fixed Prosthodontics. She requested the improvement of her impaired esthetic smile caused by affected teeth. Her dental history revealed an orthodontic treatment of 7 years back conducting to the necrosis of the central incisors. The treatment plan included an endodontic treatment followed by prosthetic therapy consisting of a Zirconia based crown restoring the endodontically treated incisors. Internal bleaching technique was rejected because it is time consuming.

Keywords: Aesthetics; central incisors; all ceramic systems; zirconia based crowns; devitalized teeth.

1. INTRODUCTION

All clinicians are in general agreement that an aesthetically pleasing restoration should mimic

the natural tooth in terms of shape, dimensions and texture besides the translucency and shade in order to get a similar light behavior [1]. As

*Corresponding author: E-mail: nissafdaouahi@gmail.com, dalendaresearch@gmail.com;

tooth color has a particular esthetic value, discoloration poses a serious problem. In addition, It remains a challenge confronted by clinicians especially when central incisors are concerned because they are considered as the most difficult tooth for the laboratory technician to match [2]. As the maxillary incisors have the same shade whereas the canine appear darker, the harmony of the whole becomes difficult to achieve without an artificial appearance. However, Tooth staining can be improved by a number of approaches including bleaching procedures and full coverage restorations. A correct diagnosis seems to be a key of success and a careful assessment is essential for better prediction of the degree to which bleaching will improve tooth color [3,4]. Based on localization and etiology, discoloration can be defined as being extrinsic or intrinsic [5]. The latter may be caused by loss of pulp vitality which can be described as a consequence of not only traumatic injuries of the tooth such as fracture and avulsion but also as an effect of routine orthodontic treatment. This arises from studies which are based on radio respirometric techniques confirming that orthodontic movement can cause a depression of oxygen utilization system within the pulp cells and as a consequence pulp necrosis [6].

When discoloration comes from necrotic pulp tissue it is associated with the alteration of light scattering and absorption properties of enamel and dentin [7]. This problem can be solved by internal bleaching procedures which can achieve a satisfactory aesthetic improvement [8]. In fact, it is a relatively simple procedure which preserves hard tissues [9]. However, because of the long treatment period, patients prefer esthetic improvement through prosthetic treatment rather than bleaching techniques. Moreover, depending on the degree of discoloration, when the underlying tooth color has a dark shade (between A5 and C10) full coverage restorations can, also, be considered as an attractive treatment approach and the core of the material chosen should be opacous [2].

When it comes to prosthetic approach and as opaque metal substructure causes undesirable light reflection, ceramics are considered the best in mimicking the natural tooth appearance. This material provides a deep translucency similar to natural teeth allowing more light to enter and scatter. Optical behavior of ceramics is largely depending on crystalline content of ceramic and differs from system to system. The dilemma that

clinicians are facing is so; which system to use? [2] The selection of the ceramic material depends on factors unique to each patient for that there is no a single ideal material for every case. This choice requires basic knowledge regarding material properties and case selection [10]. The translucency of the ceramic system was described as an important factor that plays a great role in light behavior and in aesthetics [11] It is largely depending on light scattering color of tooth abutment. When it is higher it will let more light to enter into the restoration and more life-like appearance can often be achieved by using a clear cement which means that the underlying tooth has a significant influence over the resultant color [1,11,12].

Nevertheless, discolored teeth require a ceramic material that can mask the underlying abutment tooth color this means that high translucency is not always desirable and there are instances where ceramic materials with lower translucency are beneficial to enhance an aesthetic outcome [1]. This arises from the fact that, when a translucent ceramic restoration is placed on a dark underlying tooth structure, such as an endodontically treated tooth the color beneath the crown might result in discoloration and shadowing of the restoration particularly the cervical areas [12]. In such cases, the use of Silica glass based all ceramic crowns is not recommended because they are translucent. Studies confirmed that changing the underlying color abutment tooth from lighter to darker color resulted in significantly change in aesthetic results when using glass ceramic lithium disilicate reinforced crown and a minimum of 2mm of ceramic thickness was recommended to block out dark underlying color which requires excessive dental tissue removal to provide sufficient bulk for ceramic material [13,14].

Recently, among the all ceramic systems, Zirconia based ceramics have become topic of a great interest in the field of prosthodontics for both its mechanical properties which are very similar to those of metal and its color which is similar to tooth color [15,16]. For these reasons, Zirconia gains attention and became highly attractive for clinicians looking for aesthetic improvement especially with dark abutment teeth in the aesthetic zone because of its high refractive index [17,18]. It is, then, the most suitable material to be used when covering devitalized teeth as it is white in color and more opaque than other dental ceramics. This arises from the fact that with an equal thickness, the

most translucent Zirconia is only 73% translucent as conventional lithium disilicate [1]. It has then to be a foundation of optimal aesthetics in combination with perfectly matching overlay porcelain [17]. Zirconia core is aesthetically better accepted than metallic cores but it remains clinically too white. To improve the overall matching color, the introduction of shaded zirconia is an exciting strategy which gives the opportunity to control the shade of the core allowing highly aesthetic results and as a consequence a thinner veneer should be required to mask the underlying core [11,17,19,20]. However, A successful aesthetic outcome is, also, related to a correct shade match should be well reproduced by the laboratory technician. Therefore, the shade guide should have basic requirements in color matching [21].

2. CLINICAL REPORT

A-25-year old female patient presented to the Department of Fixed Prosthodontics. She had a hidden smile and was complaining about her poor aesthetics due to discoloration of her central incisors [Fig. 1, Fig. 2]. She expressed her dissatisfaction with the impaired aesthetic appearance caused by affected teeth and she was asking for an aesthetic solution. She noticed that the change in color was increased gradually. Her dental history revealed that the central incisors were necrotic as a complication of orthodontic treatment performed 7 years back.

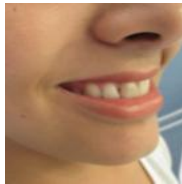


Fig. 1. Extra oral view: Patient smile

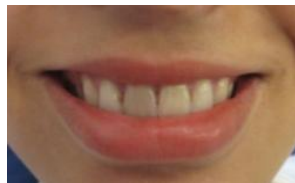

Fig. 2. Extra oral view showing the impaired aesthetic aspect

When they were exposed to vitality testing, central incisors did not show any signs of

sensitivity. Radiological evaluation confirmed that they were non vital. As the teeth were free from fillings and caries and as trauma was not reported, the necrosis could only be a complication of the orthodontic treatment. Soft tissues were evaluated as healthy and oral hygiene as well. Aesthetic assessment showed that the tooth axis, the shape, the size and the gingival Zenith were evaluated as normal. Diagnostic impression using irreversible hydrocolloid impression material (Alginmajr, Major Prodotti Sp A made in Italy) was made and the occlusion was analyzed preoperatively.

The specific challenge facing the treatment team was the wish to have the aesthetic appearance restored and at the same time to reconstruct the biomechanical properties of the devitalized affected teeth. To meet aesthetic goals and considering the patient's request for short time of treatment, the treatment plan included endodontic treatment followed by Zirconia based crowns restoring the aesthetics of central incisors and improving its altered mechanical properties. Internal bleaching technique was rejected because of time consuming procedure.

3. CLINICAL PROCEDURE

An endodontic treatment was performed using the lateral condensation technique [Fig. 3]. The teeth were prepared for all ceramic crowns with internal rounded shoulder at a sub gingival level conducting to sufficient facial tooth reduction in order to secure the thickness of the restoration for discolored teeth masking. This allows a thickness of 1.2 mm of porcelain and 1.5 to 2 mm incisally [Fig. 4]. Tooth preparation edges should be rounded with no sharp angles not to create internal stress in the crown. Then provisional restorations were fabricated using auto-polymerized resin TEXTON (S .S White made in England by Prima Dental Group; Ce 0473), putty index made from the wax up and cemented with temporary cement (Temp Bond Type I Class 1Ce OO86. Kerr made in Italy). The full arch impression was made with a combination of heavy and light silicon (HydroC, Detax made in Germany). The shade was determined with a shade guide (Vitapan 3D Master). About a week after this procedure; the cores were fabricated with Zirconia via CEREC IN LAB, including scanning design and milling procedure, and tried in [Fig. 5]. Afterward, the cores were veneered with a compatible porcelain system with a thickness between 1 mm to 2 mm. An aesthetic try in of the crown was made before final staining

and glazing .This allows verification of the crown morphology and color. So, both of them can be modified in this stage. Aspects such as contact points and occlusion were, also, assessed and adjusted. After the removal of temporary restoration, the abutment teeth were cleaned with chlorhexidine and the final restorations were cemented using Zinc phosphate cement. The tooth shade was in harmony with the surrounding dentition. The patient was fully satisfied with the aesthetically pleasing outcome [Fig. 6, Fig. 7 and Fig.8]

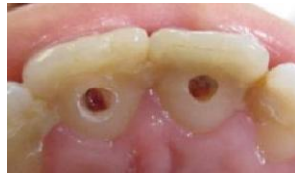

Fig. 3. Intra oral view showing access cavities

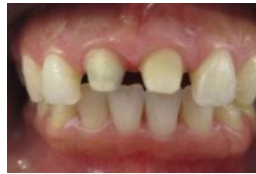

Fig. 4. Tooth preparation: Dark abutment teeth

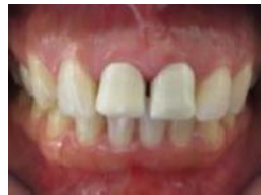

Fig. 5. Zirconia cores

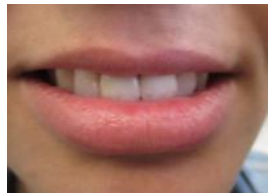

Fig. 6. The tooth shade is in harmony with the surrounding dentition

4. DISCUSSION

Local intrinsic discoloration may result from pulp necrosis conducting to optical and biomechanical alterations related to vitality pulp loss [22-26] .In

fact devitalized teeth have smaller resistance and high fracture risk [25]. Reeh et al. [22,38] demonstrated, also, that cavity preparation and endodontic treatment are associated with a loss of structure and accordingly a loss of strength. This fact was, also, confirmed by other studies which proved that endodontic procedures were responsible for 38% of reduction of flexural strength of the crown [22].

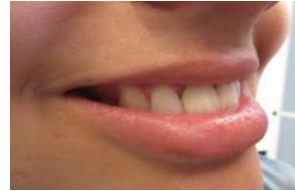

Fig. 7. Final result showing an improvement of the smile

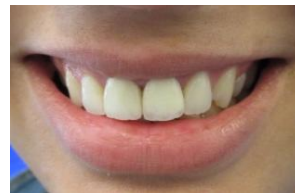

Fig. 8. Front view of final restoration

Many authors describe teeth devitalization as a consequence of a routine orthodontic treatment. In fact and according to studies pulp necrosis can occur in 5% in patients having the history of orthodontic treatment during adolescence [6].

In such cases, the clinician is faced with difficult treatment decision which doesn't only aim for the imitation of natural teeth in terms of shade and translucency but also the improvement of its altered mechanical properties. Intra coronal bleaching can be considered as the most conservative approach. However, it was not the suitable one in this situation because of the time consuming procedure. In Fact, it was demonstrated that the most of bleaching agents causes changes in the level of calcium, sulfur and potassium altering in that order the inorganic component of hydroxyd apatite which is the result of calcium and phosphorus ratio changes. In addition, Australian studies using 30% hydrogen peroxide found that 2% of teeth exhibited cervical resorption exposing the teeth to trauma and the loss. Moreover, tooth fracture has been also observed after intra-coronal bleaching which is probably due to extensive removal of the intra coronal dentin [9].

In the same context, several studies showed that adequate coronal coverage following endodontic treatment resulted in a decrease of tooth loss [27]. Besides, ceramics, which are categorized into translucent and opaque material, offer excellent results in terms of aesthetic, biocompatibility and long term stability of the restoration [28,10]. Furthermore, with the advent of CAD/CAM systems and the improvement in strength and in aesthetic, ceramics based on partially stabilized Zr O₂ have been used in particular [28]. In fact, Zirconia single restoration showed a success rate of 93%. This rate was proved by two studies where the first study focused on a limited sample size of 15 Cercon crown during 2 years of observation meanwhile the second investigation was performed on 204 Procera Zirconia crowns during 3 years of observation [29]. Other studies showed only 2% of porcelain chipping [30,31] which was mainly caused by poor connection between porcelain and zirconia [32]. It can, also, be related to framework architecture and an incorrect shaping of the core [29]. Moreover, as accuracy at the crown margin of 50 µ -100 µ is considered to be ideal, milled dense Zirconia cores showed, also, high accuracy of fit, ranging between 0 and 74 µ [17,29].

According to Kelly et al. [33,39] core translucency is considered as the primary factor in controlling aesthetics and a critical in the selection of the material. The low translucency of Zirconia core, which can be considered by such researchers as a disadvantage, is highly recommended in discolored teeth. This fact makes Zirconia seem to be the suitable material with dark underlying tooth structure and altered mechanical properties in endodontically treated central incisors. It does not allow light transmission through the abutment tooth and it masks its intrinsic coloration similarly to metal frameworks [34].

Currently, To avoid Milky white color there are two methods. The first is to hide the color of zirconia by applying a layer of stain or liner and the second consists on shading the zirconia by immersion or painting with coloring solution in the pre-sintered state. These methods require both an extra step of painting before sintering. The use of porous Zirconia blocks that are pre shaded to the desired coloration seems to be a good alternative. These blocks need to be only fired after machining. In addition, the color of the sintered core is uniform which is an advantage making the coloring solutions unsuitable [11,35].

Authors found, also, that 0.5 mm are necessary for incisors to be opaque in most clinical situations. CEREC system, similarly to LAVA system, allows a thinner core to be fabricated for incisors with a thickness down to 0.3 mm. Due to the improved mechanical properties of the material; it was allowed to thin the cores to 0.2 mm on the facial aspect permitting more space for porcelain veneering and then a maximum translucency which is necessary for central incisors [19,36,37].

5. CONCLUSION

Restoring discolored endodontically treated central incisors remains an aesthetic challenge in fixed restorations. Shade selection, ceramic system choice and appropriate communication with laboratory technician are combined factors for success. Zirconia is considered as an alternative solution because of its enhanced aesthetics and mechanical properties.

CONSENT

All authors declare that written informed consent was obtained from the patient for publication of this case report and accompanying images.

ETHICAL APPROVAL

It is not applicable.

ACKNOWLEDGEMENTS

The authors would like to thank colleagues from the department of prosthodontics for their support. We would also like to thank Mr Fethi Troudi for his valuable efforts.

COMPETING INTERESTS

Authors have declared that no competing interests exist.

REFERENCES

1. Editorial. Prescribing a dental ceramics material: Zirconia vs lithium –disilicate. The Saudi Dental Journal. 2011;23:165-166.
2. Luke S. Kahng. Material Selection and shade Matching for a single Central incisor. The Journal of Cosmetic Dentistry. 2006;22(1):80-86.

3. Anandkumar G, Vinaykumar Hiremath. Bleaching of a non vital anterior tooth to remove the intrinsic discoloration. *Journal of Natural Science, Biology and Medicine*. 2014;5(2):476-479.
4. Mohamed Al Kahtani. Tooth bleaching procedures and their controversial effects: a literature review. *The Saudi Dental Journal*. 2014;26:33-46.
5. Chetana S. Murthy, Sudhanva ME, Raghavendra Rao, Vishwas BV. Combined approach for tooth whitening: A case report. *Int Journal of Clinical Dental Science*. 2011;2(4):69-71.
6. Thomas W. Popp, Jon Artun, Leif Linge. Pulpal response to orthodontic tooth movement in adolescents: A radiographic study. *Am J Orthod Dentofac Orthop*. 1992;101:228-233.
7. Andrew Joiner. The bleaching of teeth: A review of the literature. *Journal of Dentistry*. 2006;34:412-419.
8. Daniel Edelhoff, Olivier Brix. Restoring several discoloured anterior teeth using minimally invasive procedures. *International Dentistry, African Edition*. 2011;1(3).
9. Harshitha C. Effects of tooth Whitening Agents in non Vital Teeth. *Journal of pharmaceutical Sciences and Research*. 2014;6(3):124-126.
10. Chaimongkon Peampring, Sasiwimol Sanohkan. All ceramic systems in Esthetic Dentistry: A review. *Mahiol Dental Journal* 2014;34(1).
11. Sevcan Kurtulmus-Yilmaz, Mutahhar Ulusoy. Comparison of the translucency of shaded Zirconia all ceramic systems. *J Adv Prosthodont*. 2014;6:415-422.
12. Yada Chaiyaburr, John C Kois, Dene Lebeau, Gary Nunokawa. *JPD*. 2011;105:83-90.
13. Mizrahi B. The anterior all ceramic crown: A rationale for the choice of ceramic and cement. *British Dental Journal*. 2008;205:251-255.
14. Fernando Zarone, Simona Russo, Roberto Sorrentino. From porcelain fused –to-metal to Zirconia: Clinical and experimental considerations. *Dental Materials*. 2011;27:83-96.
15. Nelson RF, Silva A, Irena Sailer, Yu Zhang, Paulo G. Coelho, Petra C. Guess, Anja Zembic, Ralf J. Kohal. Performance of Zirconia for dental healthcare. *Materials*. 2010;3:863-896.
16. Paolo Francesco Manicone, Pierfrancesco Rossi Iommetti, Luca Raffaelli. An overview of zirconia ceramics: Basic properties and clinical applications. *Journal of Dentistry*. 2007;35:819-826.
17. Elie Daou, Maha Al Gotmeh. Zirconia Ceramics: A versatile restorative material. *Dentistry*. 2014;4:4.
18. Yeon-Wha Baek, Young-Jun Lim. Restoration of rotated and discolored maxillary incisors with a Zirconia all ceramic system: A case report. *Journal of Dental Rehabilitation and Applied Science*. 2013;29(1):95-101.
19. Edward A, Mc Laren, Russel. Zirconia based ceramics: Material properties, esthetics, and layering techniques of a new veneering porcelain, VM9.QDT; 2005.
20. Andres Ortop, Maria Lind, Gunnar E. Carlsson. A 3-year retrospective and clinical follow-up study of zirconia single crowns performed in a private practice. *Journal of Dentistry*. 2009;37:731-736.
21. Jarad FD, Moss BW, Youngson CC, Russell MD. The effect thickness on color and the ability of a shade guide to prescribe chroma. *Dental Materials*; 2006.
22. Guido Heydecke, Frank Butz, Jorg R. Strub. Fracture strength and survival rate of endodontically treated maxillary incisors with approximal cavities after restoration with different post and core systems: An in-vitro study. *Journal of Dentistry*. 2001;29:427-433.
23. Ibrahim Umar, Hakan Kamalak. Bleaching Discolored Devitalized Teeth with using of new agents. *IOSR Journal of Dental and Medical Sciences*. 2014;13(3):79-82.
24. Didier Dietdchi, Olivier Duc, Ivo Krejci, Avishai. Biomechanical considerations for the restoration of endodontically treated teeth: A systematic review of the literature-Part 1. Composition and micro-and macrostructure alterations. *Quintessence International*. 2007;38(9):733-743.
25. Carla Castiglia Gonzago, Edson Alves de Campos, Flares Baratto-Filho. Restoration of endodontically treated teeth. *RSBO*; 2011.
26. Jan Hajto, Stephan Frei. All ceramic crowns on endodontically treated central incisors. *International Dentistry-African Edition*. 2012;2(4).
27. Philip LB. Tan, Steven A. Aquilino, David G. Gratton, Clark M. Stanford, Swee Chian Tan, William T. Johnson, Deborah Dawson. In vitro fracture resistance of

- endodontically treated central incisors with varying ferrule heights and configurations. JPD. 2005;93:4.
28. Dr Amit agrawal, Dr Akanksha Garg, Dr Syed W. Hashmi, Dr Ankita Piplani Dua. Rehabilitation of anterior esthetics with porcelain fused to Zirconia restoration. IJRID. 2014;4(3):158-163.
29. Fernando Zarone. From porcelain fused to metal to zirconia: Clinical and experimental considerations. Dental Materials. 2011;27:83-96.
30. Bu-kyung Choi, Jung-Suk Han. Shear bond strength of veneering porcelain to zirconia and metal cores. J Adv Prosthodont. 2009;1:129-35.
31. Elie E. Daou. The zirconia Ceramics: Strength and Weaknesses. Dentistry Journal. 2014;8:33-42.
32. Jing Zhao, Zhijian Shen, Wenjie Si, Xinzhi Wang. Bi-colored Zirconia as dental restoration ceramics. Ceramics International. 2013;39:9277-9283.
33. Min -chieh, Steven A. Aquilino, David G Gratton, Keng Liang Ou, Chia-cheng Lin. Relative translucency and surface Roughness of four Yttrium-stabilized Tetragonal Zirconia Polycrystalline based dental restorations. Journal of Experimental and Clinical Medicine 2013;1:22-24.
34. Dalenda Hadyaoui, Nissaf Daouahi, Zohra Noura, Mounir Cherif. Gingival Harmony in Anterior Aesthetic Restorations. Dentistry Journal. 2014;2;155-162.
35. Marzeieh Alikhasi, Yazdan Sabet, Abas Monzavi, Maryam Mohajerfar. Effect of shading on flexural strength of Cercon zirconia-based ceramics. Isfahan Dental School Journal. 2012;8(1):27-33.
36. Futoshi Komine, Markus B. Blatz, Hideo Matsumura. Current status of zirconia based restorations. Journal of Oral Science. 2010;52(4):531-539.
37. Heather J. Conrad, Wook-Jin Seong, Igor. J. Pesun. Current ceramic materials and systems with clinical recommandations: A systematic review. JPD. 2007;98:389-404.
38. Reeh Es, Messer HH, Douglas WH. Reduction in tooth stiffness as a result of endodontic and restorative procedures. Journal of Endodontics 1989;15:512-6.
39. Kelly JR, Nishimura I, Campbell SD. Ceramics in dentistry: Historical roots and current perspectives. J Prosthet Dent. 1996;75:18e32.

© 2015 Daouahi et al.; This is an Open Access article distributed under the terms of the Creative Commons Attribution License (<http://creativecommons.org/licenses/by/4.0>), which permits unrestricted use, distribution, and reproduction in any medium, provided the original work is properly cited.

Peer-review history:

The peer review history for this paper can be accessed here:
<http://www.sciencedomain.org/review-history.php?iid=886&id=38&aid=8393>