



# Critical Evaluation of the Role of Lycopene on Reproduction of Male Wistar Rats Exposed to Dimethoate

Mary Odeh <sup>a</sup>, Alice Amachree <sup>a</sup>, Adetutu Olubunmi Obulor <sup>a\*</sup>  
and Eme Efioanwan Orlu <sup>a</sup>

<sup>a</sup> Department of Animal and Environmental Biology, Rivers State University, P.M.B 5080, Nkpolu-Oroworukwo, Rivers State, Port Harcourt, Nigeria.

## Authors' contributions

This work was carried out in collaboration among all authors. Authors EEO and AOO designed the study. Authors MO, AA and AOO carried out the experiment while author EEO supervised the experiment. Author AOO wrote the first draft of the manuscript. All authors read and approved the final manuscript.

## Article Information

DOI: 10.9734/AJOB/2023/v18i2337

## Open Peer Review History:

This journal follows the Advanced Open Peer Review policy. Identity of the Reviewers, Editor(s) and additional Reviewers, peer review comments, different versions of the manuscript, comments of the editors, etc are available here: <https://www.sdiarticle5.com/review-history/97979>

Original Research Article

Received: 15/02/2023  
Accepted: 17/04/2023  
Published: 04/05/2023

## ABSTRACT

**Aim:** This study was aimed at evaluating the role of Lycopene on reproduction of male Wistar rats exposed to Dimethoate.

**Experimental Design:** A completely randomized experimental design using standard methods for analysis.

**Location and Duration of Study:** This study was carried out in the Animal house, Department of Animal and Environmental Biology of Rivers State University, Nkpolu-Oroworukwo Port Harcourt, Nigeria. GPS 4°47'50"N 6°58'49"E. This study lasted for 21 days.

**Methodology:** Thirty male rats were randomly selected into five (5) groups A-E (6 animals per group). Groups B, C and D were gavaged 10, 20, 30 mg/kg/bw/day of dimethoate respectively, and co-administered Lycopene at 10mg/animal daily. Group E were administered 30mg/kg/bw/day of

\*Corresponding author: E-mail: godwin.obulor1@ust.edu.ng;

dimethoate without Lycopene. All animals were allowed access to cool clean water and standard rat pellet ad libitum. Twenty-four hours to the termination of the experiment, feed was withdrawn from the animals. Blood samples were collected by ocular puncture into heparinized tubes for hormonal analysis. Hormones such as Testosterone, Progesterone, estradiol, Follicle Stimulating Hormone (FSH) and luteinizing hormone (LH) were analysed based on the manufacturer's instruction using Randox Monza assay kit. For Histopathological analysis of the testis, 0.5g of the testis was fixed in 10% formalin and sectioned with a digital Microtome (AO spencer No. 820) at 5µm thick. Histological sections were mounted on clean glass slides and stained with Hematoxylin and Eosin (H&E). The slides were viewed at X400 magnification (modified Orlu, 2014). Statistical analysis was carried out using one-way Analysis of Variance (ANOVA) and expressed as their respective units. Where significant differences were found, Pair-wise comparisons conducted with Tukey test using SPSS 22 software.

**Results:** It was observed that the level of all hormone considered decreased significantly with an increase in Dimethoate exposure despite the administration of lycopene. However, administration of dimethoate only resulted in a significant ( $p < 0.05$ ) reduction in the concentration of all hormones compared with groups given lycopene. The massive cellular degeneration observed in the seminiferous epithelium of experimental animals exposed to higher concentrations (20 and 30mg/kg/bw/day) of Dimethoate is indicative of a targeted action of the pesticide on male reproductive organ. The antioxidant property of Lycopene is clearly visible in testicular cross section of animals in groups given lycopene as gradual regeneration of both mitotic and meiotic spermatogenic elements were evidence.

*Keywords: antioxidant; dimethoate; hormones; leydig; lycopene.*

## 1. INTRODUCTION

"With the world's population growth, it has become necessary to increase the production of food. This was partly achieved through the use of various pesticides on a large scale, initially without global guidelines or restrictions. Despite the benefits, these chemicals have polluted almost every part of our ecosystem (i.e., soil, air, and water) and they have permeated the trophic chains, reaching top predators. Therefore, the assessment of their environmental persistence and their toxicity for animals as well as humans has become a crucial factor and could be important also for the development of a global pesticide legislation that will protect both humans and the environment. Infertility is defined as failure to obtain a clinical pregnancy after 12 months of regular, unprotected sexual intercourse. On the average, it affects 8–12% of couples of child-bearing age" [1]. "A decline in human fertility has prompted an increasing proportion of couples to enrol in in vitro fertilization (IVF) programmes. Over the last 50 years, the sperm count has fallen by 32–50% in Europe and United States; this decline is too rapid to be attributed to a genetic factor, hence, might be related to one or more environmental factors, such as exposure to pesticides" [2,3].

"Pesticides are common in the human environment because of its consistent use as herbicides and insecticides in Agriculture, fields

and residential areas. The negative impact of pesticides has been investigated in experimental animals all over the world. Among the different biological effects that can be induced by pesticides, a great deal of attention has been paid to the ability of pesticides to alter the function of the endocrine system" [4,5]. "Dimethoate is a white solid insecticide with a very strong odour. It was first made to control insects in the environment but it's been used in many countries for agricultural purposes on fruits, vegetables, cotton, tobacco, ornamentals, olives etc consumed by Man. Organophosphate insecticides such as dimethoate are known to cause inhibition of acetylcholinesterase in tissues, impair fertility, testicular degeneration, decrease testicular weight and testosterone levels in rats and mice" [6,7].

"Hormones are secreted into the blood and act on target tissues throughout the body at extremely low concentrations. Endocrine Disruptors interfere with hormone synthesis and distribution or transport, others with hormone-receptor interactions. The overall result can be the adverse effects on the growth, development, brain function, behaviour, metabolism and energy balance of organisms. Interference with the reproductive system can alter timing of puberty and increase the risk of some cancers (e.g. breast, prostate and testicular cancers). The main endocrine axes are the hypothalamic/pituitary/gonad axis controlling

reproduction and puberty” [8,9]. According to [10] “reproduction is controlled by the hormones functional in the hypothalamic-pituitary-gonadal (HPG) axis. In males they concern the maintenance of testicular testosterone (T) production and spermatogenesis by the two pituitary gonadotrophins, luteinizing hormone (LH) and follicle stimulating hormone (FSH)”. “The testicular target cells of LH are the Leydig cells present in the interstitial space and those of FSH are the Sertoli cells present in the seminiferous tubules. LH stimulate Leydig cell T production, and FSH stimulate in Sertoli cells, in synergy with T, the production of regulatory molecules and nutrients needed for the maintenance of spermatogenesis. Hence, both T and FSH regulate spermatogenesis indirectly through Sertoli cell” [8,9]. Experimental data indicate that FSH is beneficial in the early stages of spermatogenesis until round spermatids, while the effect of T becomes enhanced thereafter [11,12,13]. “The germ cell to Sertoli cell ratio also decreases in the absence of FSH. Therefore, the reduction in the number of germ cells is not solely due to the decreased amount of the supporting Sertoli cells, but also because of their decreased ability to nurture germ cells” [11,14]. “The use of plants and plant parts for the treatment of ailments and diseases is increasing due to the presence of antioxidant properties in plants. Medical management including the administration of antioxidants can be a potential low-risk solution to reduce reproductive problems. One of the most powerful antioxidant is lycopene. it has been shown that lycopene is twice as effective as carotene and ten times as effective as  $\alpha$ -tocopherol” [15]. The concentration of lycopene in the testes is ten times higher than in other tissues [16]. The uneven distribution of lycopene indicates its biological role in the testes. Therefore, this study was carried out to validate the role of lycopene on reproduction of male rats exposed to Dimethoate.

## 2. MATERIALS AND METHODS

### 2.1 Experimental Location

This study was carried out in animal house of the Department of Animal and Environmental Biology, Rivers State University, Nkpolu Oroworukwo Port Harcourt.

### 2.2 Experimental Animal Care and Management

Twenty-five male Wistar rats (mean weight  $180.23 \pm 2.6g$ ) were purchased from the

Department of Animal and Environmental Biology, Rivers State University. The rats were housed in five metal cages under standard conditions (12hL: 12hD) and allowed to acclimatize for two weeks prior to the commencement of the experiment. The cages and drinkers were thoroughly washed and sun dried before the commencement of the experiment. Animals were fed with standard rodent pellet and clean water *ad libitum*. All experiments were conducted according to the institutional animal care protocols at the Rivers State University, Nigeria and followed approved guidelines for the ethical treatment of experimental animals.

### 2.3 Experimental Design

The Twenty-five experimental rats were randomly selected into cages with 5 rats per cage and grouped A to E. Group A served as the control group, not given dimethoate or lycopene. Group B were gavaged 10mg/kg /bw/day of dimethoate and 10mg of lycopene. Group C were administered 20mg/kg/bw/day of Dimethoate and 10mg of lycopene. Group D were administered 30mg/kg/bw/day of dimethoate and 10mg of lycopene. Group E were administered 30mg/kg/bw/day of dimethoate only, without lycopene.

### 2.4 Blood Collection

At the end of exposure period, feed was withdrawn from the experimental animals twenty-four (24) hours before euthanization with chloroform, the blood samples were collected into heparinized tubes for hormonal analysis. Hormones such as Testosterone, Progesterone, estradiol, Follicle Stimulating Hormone (FSH) and luteinizing hormone (LH) were analysed based on the manufacturer’s instruction using Randox Monza assay kit purchased from Co-atrium laboratories United Kingdom and read in a spectrophotometer.

### 2.5 Histopathological Analysis of the Testis

Known weight of the testis (0.5g) was fixed in 10% formalin and sectioned with a digital Microtome (AO spencer No. 820) at  $5\mu m$  thick. Histological sections were mounted on clean glass slides and stained with Hematoxylin and Eosin (H&E). The slides were viewed with a digital Microscope Biosphere Miller B with an image processor DN2-Microscopy Image Processing Software at X400 magnification [17].

## 2.6 Data Analysis

Data obtained from the hormonal analysis were subjected to one-way ANOVA, where significant differences were found, pair-wise comparisons were conducted with Tukey test using SPSS 22 software.

## 3. RESULTS

### 3.1 Visual Observation

The experimental animals showed no observable changes in their morphology during the experimental period. Although the animals showed signs of restlessness, gasping for air, itching of paws immediately Dimethoate was administered. All the animals had increased feeding pattern, leading to the increased body weight observed in this study.

### 3.2 Effect of Dimethoate and Lycopene on Mean Body Weight of Male Wistar Rats

The effect of administration of varying concentrations of dimethoate and a single dose of lycopene on the mean body weight of Wistar rats for 21 days is presented in Fig. 1a-e.

Group A is the control group with a linear increase in mean body weight (Fig. 1a). The initial mean body weight was  $179.04 \pm 3.65$ g. It increased to  $183.05 \pm 6.39$ g in week 1,  $186.44 \pm 5.77$ g in week 2 and  $189.90 \pm 6.23$ g in week 3. Fig. 1b is the graph showing the increase in mean weight of animals in group B. The weight increased initially from  $184.34 \pm 7.85$ g to  $185.18 \pm 7.43$ g in week 1,  $188.30 \pm 7.78$ g in week 2 and  $189.96 \pm 8.18$ g in week 3.

In Fig. 1c, there was also an increase in body weight of animals in group C. The weight increased initially from  $180.34 \pm 7.34$ g to  $183.2 \pm 10.2$ g in week 1,  $184.76 \pm 6.41$ g in week 2 and  $189.35 \pm 5.21$ g in week 3. An almost linear graph was presented in group D (Fig. 1d) which was similar to the control animals with values ranging from  $187.26 \pm 4.30$ g to  $189.4 \pm 4.16$ g in week 1,  $191.61 \pm 3.70$ g in week 2 and  $194.51 \pm 4.26$ g in week 3. Fig. 1e shows the mean weight of animals in group E. The mean weight increased from  $180.84 \pm 9.31$ g in week 1 to  $189.64 \pm 6.69$ g in week 3.

However, there was no significant increase in body weight of animals in groups B, C, D and E compared to group A.

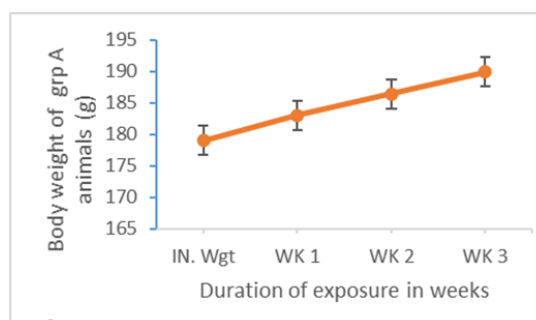


Fig. 1a. Body weight variation of wistar rats in group A (control)

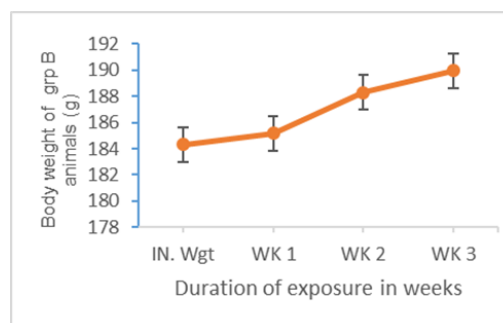


Fig. 1b. Body weight variation of wistar rats administered 10mg/kg bw/day of dimethoate and 10mg of lycopene

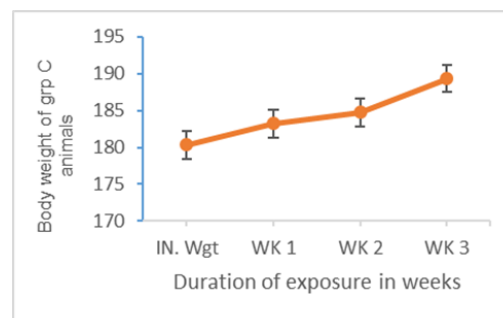


Fig. 1c. Body weight variation of wistar rats administered 20mg/kg bw/day of dimethoate and 10mg of lycopene

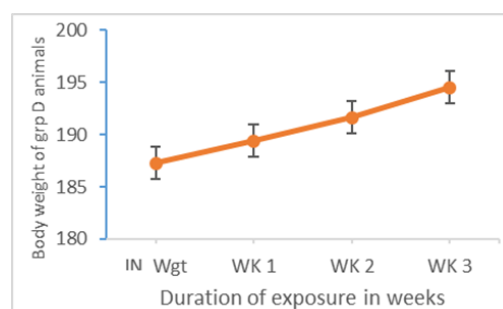
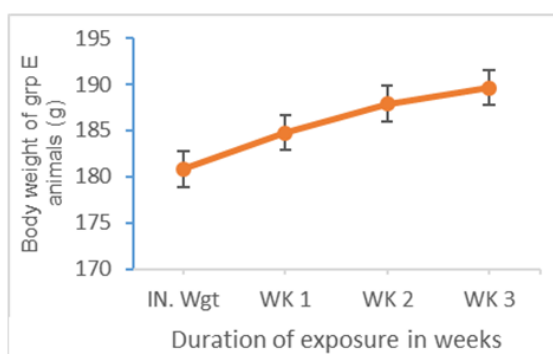


Fig. 1d. Body weight variation of wistar rats administered 30mg/kg bw/day of dimethoate and 10mg of lycopene



**Fig. 1e. Body weight variation of wistar rats administered 30mg/kg bw/day of dimethoate only without lycopene**

### 3.3 Anti-Androgenic Activity of Dimethoate by Analysing Hormonal Activity

The effect of oral administration of dimethoate and lycopene on the follicle stimulating hormone (FSH) production in male Wistar rats is shown in Fig. 2a. The concentration of FSH decreased non-significantly ( $P>0.05$ ) from  $0.574\pm0.04$  m/u/ml in the control group to  $0.494\pm0.02$  m/u/ml with the administration of 10mg of dimethoate and 10mg of Lycopene in group B. A significant ( $P<0.05$ ) decrease in value to  $0.283\pm0.03$  m/u/ml was recorded in group C administered 20mg of dimethoate and 10mg of lycopene.

However, with the administration of 30mg of dimethoate with and without lycopene in group D and E respectively, the concentration of FSH decreased to  $0.19\pm0.02$  m/u/ml and  $0.13\pm0.03$  m/u/ml which is 33.1% and 22.6% below the control level.

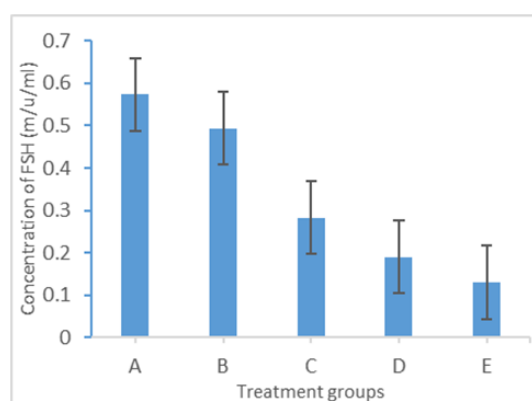
The effect of oral administration of dimethoate and lycopene on Testosterone production in male Wistar rats is shown in Fig. 2b. The concentration of testosterone was  $1.89\pm0.04$  ng/ml at the control level. This value increased significantly to  $2.58\pm0.06$  ng/ml in group B administered 10mg of dimethoate and 10mg of lycopene. A significant decrease in value to  $1.63\pm0.03$  ng/ml was recorded in group C administered 20mg of dimethoate and 10mg of lycopene. This also significantly decreased to  $0.806\pm0.18$  ng/ml in group D and  $0.79\pm0.03$  ng/ml in group E.

The effect of oral administration of dimethoate and lycopene on Progesterone production in male Sprague-Dawley rats is shown in Fig. 2c. The level of progesterone decreased from

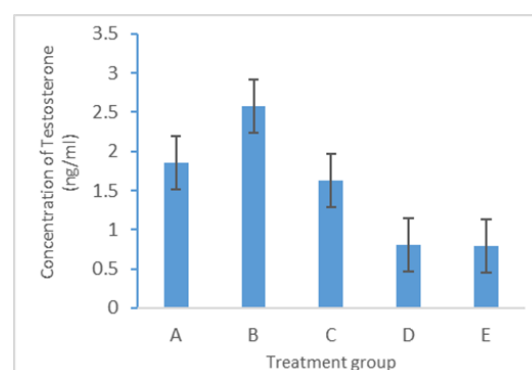
$9.92\pm0.22$  ng/ml in the control to  $6.9\pm0.2$  ng/ml in group B. It further decreased significantly to  $3.75\pm1.04$  ng/ml with the administration of 20mg of dimethoate and 10mg of lycopene. Upon the administration of 30mg of dimethoate with and without 10mg of lycopene, a significant decrease to  $2.82\pm0.49$  ng/ml and  $2.62\pm0.52$  ng/ml were recorded in group D and E respectively.

Fig. 2d shows the concentration of estradiol in Wistar rats exposed to dimethoate and lycopene. The concentration increased non-significantly from  $50.4\pm2.70$  pg/ml in group A to  $51.5\pm2.09$  pg/ml in group B and later decreased non-significantly to  $50.1\pm2.24$  pg/ml in group C,  $48.8\pm2.24$  pg/ml in group D and  $45.2\pm2.38$  pg/ml in group E.

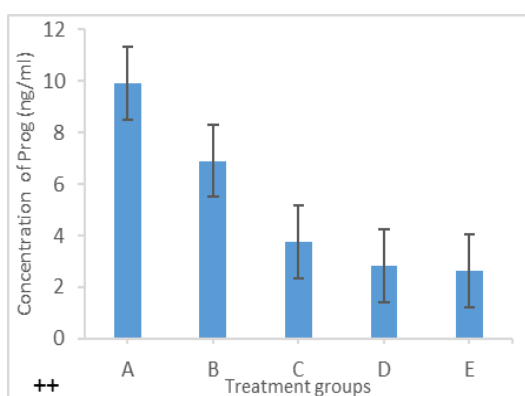
Fig. 2e shows the concentration of luteinizing hormone in Wistar rats administered dimethoate and lycopene. The values of luteinizing hormone decreased with increase in the concentration of dimethoate.



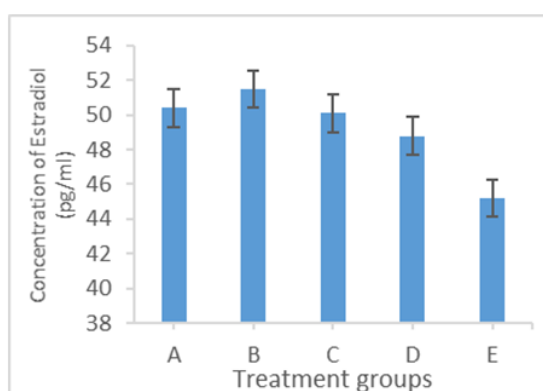
**Fig. 2a. Effect of administration of dimethoate and lycopene on levels of follicle stimulating hormone in male wistar rats**



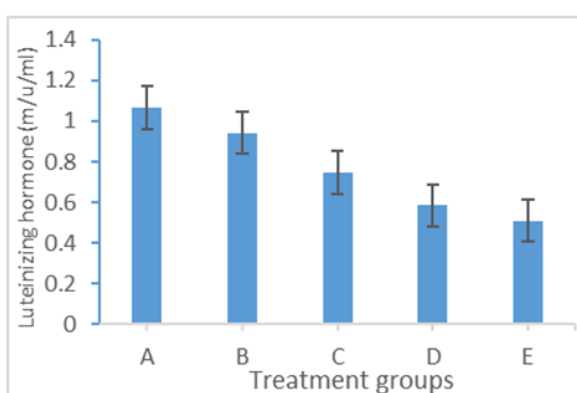
**Fig. 2b. Effect of administration of dimethoate and lycopene on levels of testosterone in male wistar rats**



**Fig. 2c.** Effect of administration of dimethoate and lycopene on levels of progesterone in male wistar rats



**Fig. 2d.** Effect of administration of dimethoate and lycopene on levels of estradiol in male wistar rats



**Fig. 2e.** Effect of administration of dimethoate and lycopene on levels of luteinizing hormone in male wistar rats

### 3.4 Histopathological Analysis of the Testis

Fig. 3a shows a cross section of the testis of Wistar rat having the normal architecture of seminiferous epithelium with mitotic cells (spermatogonia) lining the basement membrane. The epithelium shows complete complement of meiotic primary spermatocytes, Spermatids and maturing spermatogenic spermatozoa.

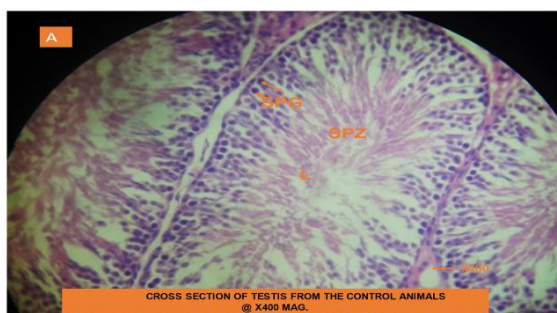
The cross-section in Fig. 3b shows the epithelium of group B experimental animals exposed to Dimethoate at the dosage of 10mg/kg/bw/day and coadministered 10mg of Lycopene. There is some negligible cellular degeneration of mitotic and meiotic spermatogenic elements as well as detachment of basement membrane.

Fig. 3c is the cross section of the seminiferous tubule of Wistar rats exposed to daily dosage of Dimethoate at 20mg/kg/bw/day and coadministered 10mg of Lycopene daily. There is a detachment of the seminiferous epithelium from the basement membrane following some degeneration of spermatogenic elements, empty lumen (EL) devoid of maturing spermatozoa.

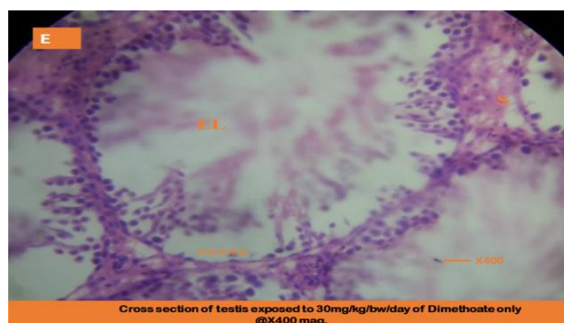
Fig. 3d is the seminiferous epithelium of Wistar rats exposed to Dimethoate at 30mg/kg/bw/day and Coadministered 10mg of Lycopene. There was massive cellular degeneration. Mostly affected are the mitotic spermatogonia showing empty spaces in the epithelium (+). Also seen was Empty lumen (EL) devoid of spermatids and maturing Spermatozoa. Loss of interstitial cell of Leydig cell(S) was observed.

Fig 3e shows complete empty lumen (EL) of Wistar rat exposed to maximum tolerable dose of 30mg/kg bw/day of dimethoate alone. The seminiferous epithelium is totally devoid of meiotic and meiotic spermatogenic elements, spermatids elongating spermatids as well as maturing spermatozoa. We can note a massive degeneration of mitotic spermatogonia (\*\*\*\*) and primary spermatocytes. Degeneration of interstitial cell of Leydig (S) was seen.

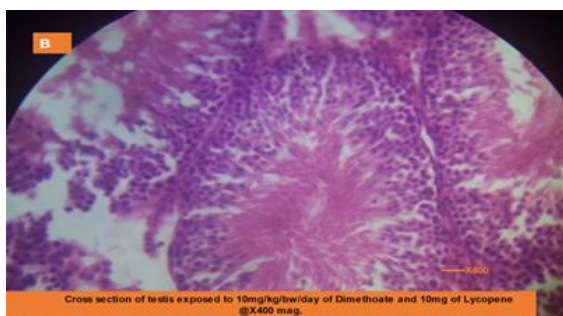




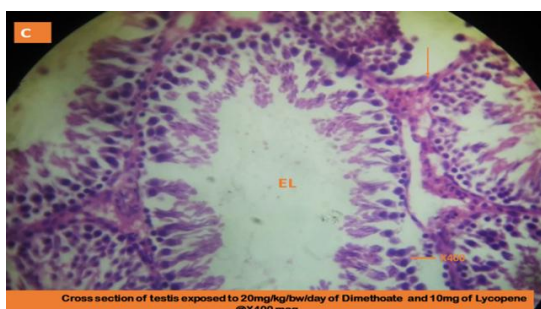
**Fig. 3a. Cross section of testis from the control animal**



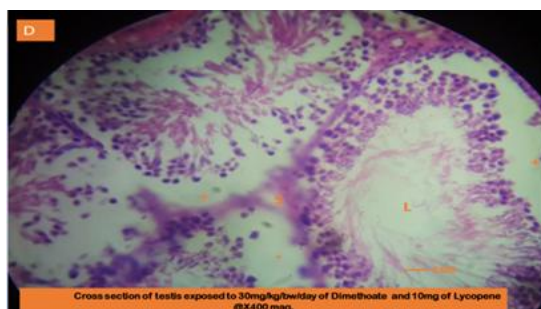
**Fig. 3e. Cross section of testis exposed to 30mg/kg bw/day of dimethoate only**



**Fig. 3b. Cross section of testis exposed to 10mg/kg bw/day of dimethoate and 10mg of lycopene @x400**



**Fig. 3c. Cross section of testis exposed to 20mg/kg bw/day of dimethoate and 10mg of lycopene @x400**



**Fig. 3d. Cross section of testis exposed to 30mg/kg bw/day of dimethoate and 10mg of lycopene @x400**

#### 4. DISCUSSION

Pesticides have been used in agriculture to enhance food production by eradicating unwanted insects and controlling disease vectors. Among them, organophosphorus (OPs) compounds are widely used in agriculture, medicine, and industry [18,19]. Systems that could be affected by OPs are brain, kidney, liver and the reproductive system. Pesticide, can impair fertility, deteriorate semen quality, cause testicular degeneration, male reproductive failure in mice following repeated exposure [20,21].

Analysis of body weight is a criterion for the evaluation of systemic toxicity providing an endpoint for the identification of potentially harmful effects of chemicals. In this study, there was no significant changes in the body weight of all experimental animals in the groups compared with the control ( $p > 0.05$ ). This might indicate that, perhaps, dimethoate is not a systemic toxin.

Concise effort has been channeled toward the study of the adverse effect of Endocrine disrupting chemicals with anti-androgenic activity [21-24]. Pesticides as well as environmental pollutants that exhibit anti-androgenic activity may be responsible for the increased incidence of male and female infertility resulting from hormonal imbalance. Many of the chemicals in the environment are endocrine disruptors and act in antagonism binding to the androgen receptors and mimic vital hormones thereby preventing the transcription of androgen-dependent genes. In this study, it was observed that the level of all hormone considered decreased significantly with an increase in dimethoate exposure despite the administration of lycopene. Moreover, administration of dimethoate only resulted in a significant ( $p < 0.05$ ) reduction in the

concentration of Testosterone, Progesterone, Follicle Stimulating and Luteinizing hormone compared with group given lycopene. The mechanism of action is by blocking acetyl cholinesterase of which are anti-androgenic and the disruption of the transcription of androgen-dependent genes reflected in the reduction of the production of testosterone. Result of studies have reported a competitive interaction of organophosphate pesticides with human androgen receptors thereby drastically reducing testosterone levels in the exposed individuals, decrease in testicular mass and peripheral organs, increased serum LH and FSH and testosterone concentration due to sub lethal administration of 50mg/day of rats to quinalphos [18,19]. Also, [25,26] reported significant increase in serum levels of luteinizing hormone and Follicle stimulating hormone whereas testosterone levels decreased hormone in a dose-dependent manner in rats exposed to Phosalone.

Worthy of note, however, was the observation that the concentration of all other androgens including Testosterone, FSH, LH and Progesterone were significantly ( $p < 0.05$ ) elevated in group B administered 10mg/kg bw/day of Dimethoate and 10mg of lycopene but decreased in other groups despite the addition of lycopene. The elevation in concentration indicates the possible role of Lycopene as an antioxidant in ameliorating hormonal imbalance initiated by Dimethoate exposure.

The massive cellular degeneration observed in the seminiferous epithelium of experimental animals exposed to higher concentrations (20 and 30mg/kg bw/day) is indicative of a targeted action of the pesticide on male reproductive organ. Most affected were the mitotic spermatogonia showing empty spaces in the epithelium (+) resulting in the decline of spermatozoa as the testicular lumen was observed to be empty and devoid of spermatids and maturing Spermatozoa. The loss of interstitial cell of Leydig cell (S) provides a mechanism of action of this pesticide as inhibition of Testosterone production based on the decline of the Leydig cells. The antioxidant property of Lycopene is clearly visible in testicular cross section of animals in group D as regeneration of both mitotic and meiotic spermatogenic element. Group E animals gavaged with the maximum tolerable dose of Dimethoate (30mg/kg/bw/day) without co-

administration of Lycopene also exhibited maximum damage of the Seminiferous epithelium. The seminiferous epithelium was totally devoid of meiotic and meiotic spermatogenic elements, elongating spermatids as well as maturing spermatozoa. There was massive degeneration of mitotic spermatogonia (\*\*\*\*), primary spermatocytes and degeneration of interstitial cell of Leydig (S). Reduction in hormones especially; androgens including testosterone inhibit sexual development and maturation as well as, impair optimal reproductive organ functions during spermatogenesis as reported in this study.

“Hormones play a vital role in the maintenance of reproductive functions. Testosterone (TET), which is the main androgen, is responsible for the initiation and maintenance of spermatogenesis in mammals while the Luteinizing Hormone (LH) stimulates the release of testosterone from the Leydig cells. The Follicle Stimulating Hormone (FSH) regulates the production of spermatozoa in Sertoli cells. Pesticides and other endocrine disrupting chemicals disrupt the normal functions of the Hypothalamic-Pituitary- gonadal axis leading to reduction in androgens and increase in Estrogens with the net effect of feminization of males and causing infertility in both males and female mammals” [13,24,25,26].

## 5. CONCLUSION

Results from this study suggests that Dimethoate, an organophosphate pesticide could act as an endocrine disruptor due the significant decrease in hormonal values reported in group E animals which received Dimethoate only when compared to other groups administered lycopene. Dimethoate also targets the reproductive and germ cells as observed in the histological micrograph of male experimental animals. However, Lycopene has the property of ameliorating effect on reproductive system and spermatogenic element.

Further studies should be done to elucidate the biological and clinical relevance of the fluctuations in hormonal level of both males and females exposed to pesticides.

## COMPETING INTERESTS

Authors have declared that no competing interests exist.



## REFERENCES

- Vander BM, Wyns C. Average of couples affected by infertility. Fertility and infertility. Definition and Epidemiology, Clinical Biochemistry. 2018;62:2-10.
- Levine H, Jorgensen N, Martino-Andrade M, Menduiola J, Wekster-Derri D, Mindlis I, Pinotti R, Swan SH. Temporal trends in sperm count: a systematic review and meta-regression analysis. Human Reproduction Update. 2017;23(6):646-659.
- Sengupta P, Borgs E Jr, Dutta S, Krajawska-Kulak E. Decline in sperm count in European men during the past 50yrs. Human Exp. Toxicology. 2018;37(3): 247-255.
- Stoker TE, Kavlock RJ. Pesticides an endocrine disrupting chemicals. 3<sup>rd</sup> chapter 18, Robert Krieger (ed), Hayes Handbook of pesticide Toxicology (New Edition) Academic Press incorporated, Orlando FL. 2010;1:551-569.
- Gea M, Zhang C, Tota R, Gelardi G, Di Nardo G, Schiliro T. Assessment of five pesticides as endocrine-disrupting chemicals: Effects on estrogen receptors and aromatase. Int. J. Environ. Res. Public Health. 2022;4(19):1959.
- Sayim F. Histopathologic effects of dimethoate on testis in rats. Bull Environ. Contam. Toxicol. 2007;78:479-482.
- Jallouli M, El-bini ID, Dhouib H, Gharbi N, El Fazaq S. Regulatory toxicology and pharmacology. 2015;73(3):853-858.
- Kohrle J. Environment & endocrinology; the case of thyroidology. Ann Endocrinology. 2008;69(2):116-22.
- Oduwole OO, Pettoketo H, Huntanieme IT. Role of follicle stimulating hormone in spermatogenesis. Frontiers of Endocrinology. 2018;9:763.
- Mc Lachlan RI, Wreford NG, Meachem SJ, De Kretser DM, Robertson DM. effects of testosterone on spermatogenic cell populations in the adult rat. Biol. Reproduction. 1994;51:945-55.
- Mc Lachlan RI, Wreford NG, Tsonis C, De Kretser DM, Robertson DM. Testosterone effect on spermatogenesis in the gonadotrophin-releasing hormone immunized rat. Biol. Reproduction. 1994; 50:271-80.
- Wreford NG, Rajendra KT, Matzuk MM, De Kretser DM. Analysis of the testicular phenotype of the follicle stimulating hormone beta-subunit knockout and the activating type II receptor knock out mice by stereological analysis. Endocrinology. 2001;142:2916-20.
- Orlu EE. Deltamethrin-induced alterations in sperm morphology and spermatogenesis impairment in adult. sprague-dawley rats. Research Journal of Applied Sciences, Engineering and Technology. 2014;7(11):2324-2331.
- Iboroma M, Orlu EE, Ebere N, Obulor AO. Androgenic and antioxidant activity of stelleria media on rat following subchronic exposure to dichlorvos. Journal of Pharmacy and Biological Sciences. 2018; 13:38-46.
- Erdman JW Jr. How do nutritional and hormonal status modify the bioavailability, uptake and distribution of different isomers of lycopene? Journal of Nutrition. 2005; 135(8):2046S-2047S.
- Durairayanyargam D, Agarwak A, Ong C, Prashast P. Lycopene and male infertility. Asian Journal of Andrology. 2014; 16(3):420.
- Obulor AO, Orlu EE. Protective role of lycopene on hormonal profile and post testicular functions of male rat exposed to sublethal doses of cypermethrin. Asian Journal of Biology. 2019;21(4):1-9.
- Sun H, Xu LC, Chen JF, Song L, Wang XR. Effect of bisphenol A, tetrachlorobisphenol A and pentachlorophenol on the transcriptional activities of androgen receptor-mediated reporter gene. Food Chemistry and Toxicology. 2006;44:1916–1921.
- Xu LC, Liu L, Ren XM. Evaluation of androgen receptor transcriptional activities of some pesticides *in vitro*. Toxicology. 2008;14(1-2):59-65.
- Obulor AO, Orlu EE. Evaluation of the therapeutic effect of lycopene on cypermethrin induced reproductive toxicity in rats. Journal of Environmental Science, Toxicology and Food Technology. 2018b; 12(3):10-16.
- Orlu EE, Obulor AO. Impact of coenzyme Q10 on hormonal profile in male sprague-dawley rat exposed to sub-chronic concentrations of cypermethrin. Asian Journal of Biology. 2021;12(3):1-9.
- Sakar R, Mohanakumar JP, Chowdhury M. Effect of n organophosphate pesticide, quinalphos on the hypothalamus-pituitary-gonadal axis in adult male rats. Journal of Reprodu Fertility. 2000;118 (1):29-38.

22. Mazaheri F, Aliabad KK, Kalantar SM, Ziya N, Khoradmehr A, Anvari M. Effect of phosalone plant pesticide on sperm parameters and sexual hormone level in wistar rats; An experimental study. International J of Reproductive Biomedicine. 2020;10(9):785-794.
23. Hess RA. Estrogen in the adult male reproductive tract: A review. Reproductive Biology and Endocrinology. 2003;1:52.
24. Sharpe RM. Pathways of endocrine disruption during male sexual differentiation and Masculinization. Best practice and Research, Clinical Endocrinology and Metabolism. 2006;20: 91-110.
25. Durairajanayagam D, Agarwal A, Ong C, Prashast P. Lycopene and male infertility. Asian J Androl. 2014;16(3):420-5.
26. Zhang L, Dong L, Ding S, Qiao P, Wang C, Zhang M. Effects of n-butylparaben on steroidogenesis and spermatogenesis through changed E2 levels in male rat offspring. Environmental Toxicology and Pharmacology. 2014;37: 705–717.

© 2023 Odeh et al.; This is an Open Access article distributed under the terms of the Creative Commons Attribution License (<http://creativecommons.org/licenses/by/4.0>), which permits unrestricted use, distribution, and reproduction in any medium, provided the original work is properly cited.

*Peer-review history:*

*The peer review history for this paper can be accessed here:*  
<https://www.sdiarticle5.com/review-history/97979>