



## **Evaluation of Nephroprotective Activity of *Laportea interrupta* Leaf Extract in Experimental Animals**

**Puneeth Kumar Shetty<sup>a</sup> and Prasanna Shama Khandige<sup>a\*</sup>**

<sup>a</sup> Department of Pharmacology, NGSMS Institute of Pharmaceutical Sciences, NITTE Deemed to be University, Paneer, Deralakatte, Mangalore, 575018, Karnataka, India.

### **Authors' contributions**

*This work was carried out in collaboration between both authors. Both authors read and approved the final manuscript.*

### **Article Information**

DOI: 10.9734/JPRI/2021/v33i59A34283

### **Open Peer Review History:**

This journal follows the Advanced Open Peer Review policy. Identity of the Reviewers, Editor(s) and additional Reviewers, peer review comments, different versions of the manuscript, comments of the editors, etc are available here: <https://www.sdiarticle5.com/review-history/79722>

**Original Research Article**

**Received 07 October 2021**

**Accepted 14 December 2021**

**Published 16 December 2021**

### **ABSTRACT**

*Laportea interrupta* also called as Hen's Nettle is a primitive plant that is known for its property of causing itch after its touch. This plant has been found useful in treating pre maternal health, anti-pyretic and anti-inflammatory action. Previously conducted scientific studies revealed that it is having potential of anti- microbial activity. It has also been proved to have anti-oxidant property as it contains flavonoid contents especially rutin and gallic acid. Extraction of the plant phyto constituent was by maceration process. Healthy Albino rats of wistar strain of 150 to 250 gm were used as experimental animal. Gentamicin induced renal injury and Paracetamol induced nephrotoxicity are the two methodologies followed in this experiment to induce toxicity in rats and then it is followed by ethanolic extract of the plant of low, mid and high dose. Biochemical analysis, Histopathological studies and statistical studies are also performed. There was significant decrease in the gentamicin-induced nephrotoxicity. Observation of change in body weight serum creatinine, serum albumin and serum protein were assessed for kidney function test. Histological and pathological study of kidney tissue was observed to identify the changes in the degree of cellular damage and healing effects in this research work.

**Keywords:** *Laportea interrupta*; anti-oxidant; rutin and gallic acid.

## 1. INTRODUCTION

The present experimental work was conducted to determine the nephroprotective activity from the leaves of Hen's Nettle (*Laportea interrupta*) [1]. The plant *Laportea interrupta* (*L.interrupta*) is known to cause itching effect on touching it. So a plant that commonly causes irritation, allergic reaction and sometimes even toxic are incapacitated from research work to identify its possible beneficial effects from it. These types of plants can be evaluated for medicinal property or other uses and can be studied. The medicinal effect of any drug is mainly based on the dose of that substance. A medicine will become toxic if it is taken at high dose, thus a toxic substance can act as medicine if its dose and other adjuvant is determined. *L.interrupta* is known to have phytoconstituent flavonoids that act as antioxidants. Flavonoids are the powerful antioxidant [2] agent that neutralizes the reactive oxygen species and thus can prevent cell damage

The word 'nephro' comes from the Greek language nephros, which means kidney. Nephron is the structural and functional unit of kidney. In a normal human body, the process of excretion takes place in kidney, lungs and skin but kidney does the major part of it. Blood circulates to all parts of the body and does the role of transporting essential nutrients and other materials to it; in return it will collect all the waste materials from it which will then be filtered in the kidney. Nephroprotective [3] is the protection of kidney from harm. The harm can be due to glomerulonephritis, kidney infection etc. Since excretion is a continuous process, accumulation of waste and toxic material takes place over time. In these days, the lifestyle of human beings has changed dramatically towards more unhealthy condition and habits. Due to this, man's health is also worsening in a gradual manner.

The proverb "Cleanliness is next to Godliness" in short it means, The God is present next to cleanliness. To lead a happy life, cleanliness should be followed in every aspect of our lives. In our body, the process of cleaning is done by excretory system. Excretion is the process of removal of toxic (bad) waste from the body of an organism.

Like all other organs in our body, kidney plays an important role in overall healthy function of the body. Kidney damage if an untreated lead to kidney failure and it is of two types. Acute kidney

failure happens when one or both kidneys suddenly become unable to remove the waste products from the blood. Chronic kidney failure is the second type; it refers to a long-term, gradual loss of kidney function that happens over time. Up to 3 in 10 adults worldwide have chronic kidney disease, which is invariably irreversible and mostly progressive. The present study of the nephroprotective effect was carried out based on the phytochemical screening of the leaves of the plant material *Laportea interrupta* (L.) Chew.

The plant belonging to the family Urticaceae is found in the Asian tropical region and grows mainly during the rainy season. The traditional use of this plant differs from place to place. Some of its commonly known uses are as an aid in pregnancy [4,5] to relive from whooping cough as expectorant [6] to treat spasm of the muscle [7] anthelmintic [8] headache, stomach ache [9] etc.

## 2. MATERIALS AND METHODS

### 2.1 Plant Materials

The leaves of *L. interrupta* were collected from in and around the areas of Mangalore and Kasaragod. The leaf of the plant was authenticated as *L. interrupta* by Krishnakumar G, Professor, Department of Applied Botany, Mangalore University, Mangalgangothri – 574199. The collected leaves were then shade dried for about 30 days

### 2.2 Drugs

Injection of Paracetamol of 150mg/ml and Gentamicin of 10mg/ml were used as the inducer of nephrotoxicity in rats.

### 2.3 Preparation of Plant Extract

The dried leaves were powdered using an electric mixer grinder. This powdered leaves were then subjected to ethanolic extraction by a process called maceration [10]. The powdered leaves materials were immersed in ethanol of 50% v/v concentration in a glass vessel. It was then allowed to macerate for a period of 7 days with occasional stirring. This helps the solvent to penetrate cells of solute, dissolve the soluble constituents and extract out. After the 7th day the extracts are collected, filtered and then evaporated using Laboratory water bath. The final dried, semi-solid product will then be used

for further studies. It is stored in desiccator. It is an air tight container. Its bottom is filled with calcium chloride, silica gel to absorb excess moisture and humidity content during storage of hygroscopic products.

## 2.4 Phytochemical Analysis

The preliminary qualitative analysis revealed that *L.interrupta* is having Alkaloids, Tannins, Steroids, Glycosides, Flavonoids and reducing sugar. The ethanolic extract of this plant had high total phenolic (46.35 mg of gallic acid/ g of extract) and flavonoids (80.27 mg of rutin/g of extract) [11].

## 2.5 Animals

The Albino rats of Wistar strain were inbred and obtained from NUCARE (Nitte Centre for Animal Research & Experimentation) part of the Nitte University Established under NGSM Institute of Pharmaceutical Sciences. The obtained animals were acclimatised in polypropylene cages. Throughout the study animals were give humane care, proper food, water and sanitization was also followed.

## 2.6 Acute Oral Toxicity Studies

Acute toxicity Studies was originally used to measure the potency of a drug substance. All chemicals have the potential to cause toxicity at sufficiently high doses. Its main purpose is to determine the therapeutic index, to describe the adverse effect of a substance that result either from a single or from multiple exposure in rodent and one non rodent species, within 24 hours or less than that.

A simple method for measuring acute toxicity is the up and down method which is given in OECD guidelines for testing of chemicals [12].

Test drug was given by oral route using oral gavage needle. Animals were treated with a particular dose of the test drug and observed for a period of 24 hours for any mortality. The subsequent doses were increased if the dose was tolerated, or decreased if it was lethal. Four additional animals are dosed after passing the first trail testing with individual animal. The starting dose of the test substance will be 500 mg/kg body weight and the maximum dose should not be more than 2000 mg/ kg. If the first animal is dosed with upper limit dose and survives then the second animal will receive the

same dose. After testing with the three animals and no deaths have occurred then further three more animals are used. If there is again no sign of lethality then the test can be terminated.

The animals were kept for fasting overnight before extract treatment (water was provided but not food) and body weight of these rats were taken to determine the dose of the test drug sample. The suspension of the extract having the concentration of 180mg/ml was dissolved in sodium carboxy methyl solution (0.6 % W/V) and administered at the dose of 2000 mg/kg body weight of the treatment. After treatment, the animal will be observed individually with constant attention for 1 hour and once in every 30 minutes for next 4 hours, then after 24 hour and daily thereafter for 14 days.

## 2.7 Nephroprotective Activity

The preliminary qualitative test of *L.interrupta* showed the presence of Alkaloids, Tannins, Steroids, Glycosides, Flavonoids and reducing sugar. This is proved by the previously conducted research work on evaluation of phytoconstituents and its antioxidant property by Krishna CS *et al.* Ethanol extracts of flowers and roots revealed high total phenolic (46.35 mg gallic acid equivalents/g of extract) and flavonoid contents (96.67 mg rutin equivalents/g of extract) respectively. Antioxidant assays showed that ethanol root extract possessed a strong 2,2-diphenyl-1-picrylhydrazyl radical scavenging capacity.

Two animal models were used for the pharmacological effects of *L. interrupta* against Gentamicin induced nephrotoxicity and paracetamol induced nephrotoxicity

In Gentamicin induced renal injury 5 groups (n= 5) rats were taken for study. This study was carried out for a period of 14 days.

Group I served as control and will receive filter water through oral route.

Group II was treated with gentamycin by i.p route with '40 mg/kg' dose of gentamicin.

Group III, IV and V received low dose (100mg/kg), medium dose (200mg/kg), and high dose (400mg/kg), of the ethanolic extract of *L.interrupta* followed by Gentamicin 40 mg/kg respectively.

Paracetamol induced nephrotoxicity was performed for a period of 14 days having 5 groups with 5 rats in each.

Group I was served with normal drinking water.

Group II served as paracetamol drug treated group (200mg/kg) by i.p route

Group III, IV and V were given oral administration as low dose (100mg/kg), medium dose (200mg/kg), and high dose (400mg/kg), of the ethanolic extract of *L.interrupta* followed by intraperitoneal injection of paracetamol (200mg/kg) respectively.

## 2.8 Blood and Kidney Collections

Blood sample collection by retro orbital plexus and kidney tissue dissection after the completion of 14 days course of above experimental procedure are done to check the activity of ethanolic extract of plant against drug induced nephrotoxicity. Blood samples are subjected to Biochemical analysis and kidney tissues are observed under the microscope.

**Determination of biochemical parameters:** On the last day of the experiment, blood sample obtained by retro orbital puncture method are collected in micro centrifuge tube. The obtained blood will be allowed to clot for 30 minutes and after centrifugation, serum from the blood sample is used for biochemical analysis of serum albumin, serum creatinine and total protein using commercially available kits.

**Histopathology of rat kidney:** After the completion of the assessment of blood biochemical parameters rat were be sacrificed. Before sacrificing the rats it were anesthetized using formalin as inhalation anesthetics. The obtained kidney organs of sacrificed rats were stored in 10% formalin solution and then it was dissected to form thin kidney tissue slices. Slices of kidney tissue were fixed on glass slides with the help of paraffin wax and was stained using hematoxylin and eosin. This was then used for microscopic observation to identify the histopathological changes

## 2.9 Statistical Analysis

All the values are expressed as the mean  $\pm$ SD for five rats in each group. Differences between groups were performed by one way analysis of variance (ANOVA) using Statistical Package for Social Sciences (SPSS – Version 16.0). Values correspond to  $p < 0.05$  levels have been denoted

by distinct symbols in the table. Treatment groups is compared with normal group.)

## 2.10 Parameters Used for Nephroprotective Function

a) Percentage change in body weight - The initial and final body weights of every animal of all groups were taken and percentage change in body weight was calculated. Decrease in the body weight was the indicative of illness and also the sign of pathological effects of nephrotoxicity in this experiment.

b) Serum Creatinine: This is one among the common biomarker test for kidney function assessment. As the level of Serum increases from the normal range it is considered as nephrotoxic and may result in further kidney failure

c) Serum total protein: this test gives the measure of total albumin and globulin in the body which together makes up the total protein. This is generated from the liver. This test can help to diagnose kidney disease, liver disease and malnutrition. If total protein level is low it indicates the possibility of having kidney or liver disease.

d) Serum Albumin: A healthy kidney does not allow albumin to pass from the blood to urine into the kidney and damaged kidney lets some albumin to pass into urine. If the albumin level is more than the normal in the blood as well as urine it indicates failure in the normal function of liver as well as kidney like proteinuria, renal function and glomerular lesion.

## 3. RESULTS AND DISCUSSION

From the acute oral toxicity studies the animal was found to be safe and healthy even after administering the maximum dose of 2000mg/kg. Based on the acute oral toxicity study 1/10<sup>th</sup> of the dose 2000mg/kg as medium dose (X), 50 % of the X as the minimum dose and 2 times of X as maximum dose was selected for the test extract.

Present study shows that Gentamicin and Paracetamol has caused renal failure significantly characterized by decrease in body weight, increase in kidney weight, elevated levels of serum albumin [13] serum creatinine [14] and serum total protein [15] when compared to that of

normal animal group. These variations in biochemical parameter of renal function are well supported by histopathological parameters. Evidences suggest that high dose or long course treatment of Gentamicin induces nephrotoxicity via oxidative stress [16]. Enhancement of oxidative stress is due to excessive production of oxygen free radical generation. Gentamicin binds with 16rRNA at the 30s ribosomal subunit disturbing the translation of mRNA leading to the accumulation of reactive oxygen species, as a result depletion of protein are involved in

oxidation reduction that may lead to bacterial death on the other hand the generation of reactive oxygen species leads to cellular damage of various organs of the body. Paracetamol also induces acute or chronic renal damage [17] but the mechanism behind this is not clearly well established. The pathophysiology behind nephrotoxicity due to paracetamol is attributed to isoenzyme mixed function oxidase present in the kidney; other reasons can also be due to prostaglandin sythetase and N – deacetylase enzymes

**Table 1. Various Parameters used for the assessment of Nephroprotective effect of *Laportea interrupta* against Gentamicin induced nephrotoxicity**

	Percentage change in the body weight	Serum Albumin in g/dl	Serum Total Protein in g/dl	Serum creatinine in mg/dl
Group 1	5.036 ± 2.835	3.970 ± 0.79	6.400 ± 0.600	0.526 ± 0.16 <sup>a</sup>
Group 2	-3.498 ± 0.576 <sup>a</sup>	1.900 ± 0.349 <sup>a</sup>	4.112 ± 0.597 <sup>a</sup>	2.550 ± 0.422 <sup>a</sup>
Group 3	-1.133 ± 0.404 <sup>a</sup>	2.460 ± 0.853 <sup>a</sup>	3.614 ± 0.818 <sup>a</sup>	2.206 ± 0.324 <sup>a</sup>
Group 4	3.364 ± 2.191 <sup>a</sup>	3.260 ± 0.610 <sup>a</sup>	6.149 ± 0.597 <sup>a</sup>	1.450 ± 0.306 <sup>a</sup>
Group 5	5.226 ± 3.240 <sup>a</sup>	3.690 ± 0.741 <sup>a</sup>	7.247 ± 1.207 <sup>a</sup>	1.030 ± 0.578 <sup>a</sup>

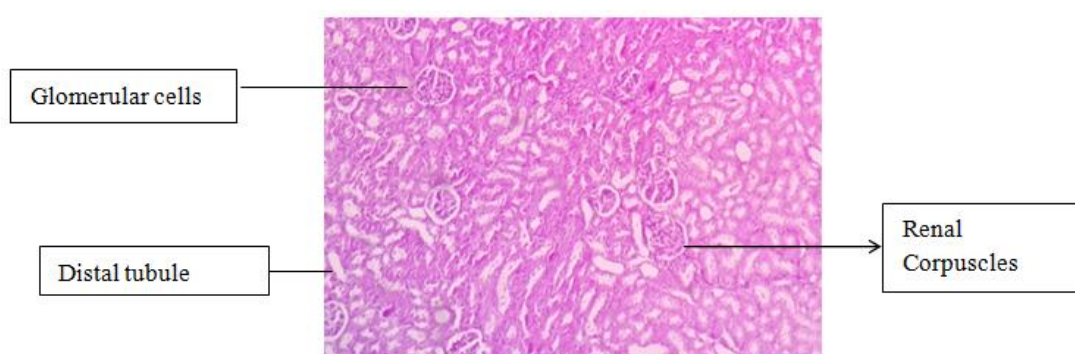
All the values are expressed as Mean ± Standard Deviation (n = 5)  
 a. P < 0.05 when compared with group 1 (Normal)

**Table 2. Various Parameters used for the assessment of Nephroprotective effect of *Laportea interrupta* against Paracetamol induced nephrotoxicity**

	Percentage change in the body weight	Serum Albumin in g/dl	Serum Total Protein in g/dl	Serum creatinine in mg/dl
Group 1	5.19 ± 1.835	3.172 ± 0.444	0.640 ± 0.599	0526 ± 1.63
Group 2	0.697 ± 0.576 <sup>a</sup>	1.414± 0.325 <sup>a</sup>	5.661 ± 0.293 <sup>a</sup>	1.474 ± 0.213 <sup>a</sup>
Group 3	-0.742 ± 0.404 <sup>a</sup>	1.753 ± 0.646 <sup>a</sup>	6.258 ± 0.637 <sup>a</sup>	1.399 ± 0.206 <sup>a</sup>
Group 4	5.28 ± 2.191 <sup>a</sup>	2.881 ± 0.458 <sup>a</sup>	7.220 ± 0.737 <sup>a</sup>	1.184 ± 0.294 <sup>a</sup>
Group 5	5.97 ± 1.624 <sup>a</sup>	3.307 ± 0.258 <sup>a</sup>	8.226 ± 0.544 <sup>a</sup>	0.860 ± 0.264 <sup>a</sup>

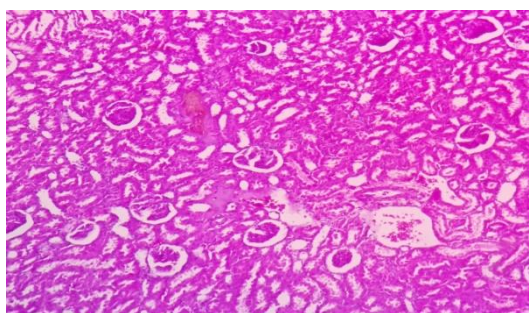
All the values are expressed as Mean ± Standard Deviation (n = 5)  
 a. P < 0.05 when compared with group 1 (Normal)

Histopathological observation of Rat kidney tissue of Gentamicin induced nephrotoxicity experiment model.

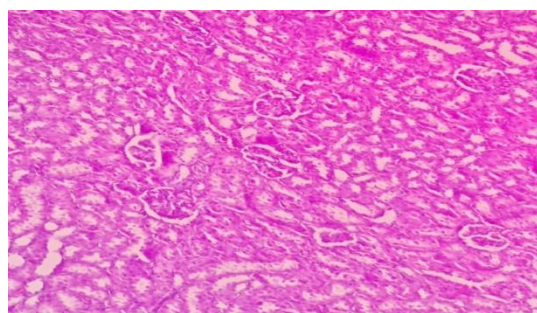


**Fig. 1.1. Rat kidney dissection of group 1**

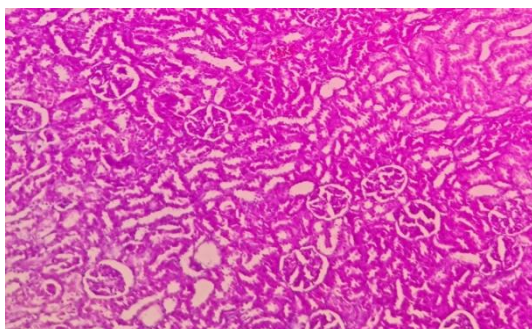




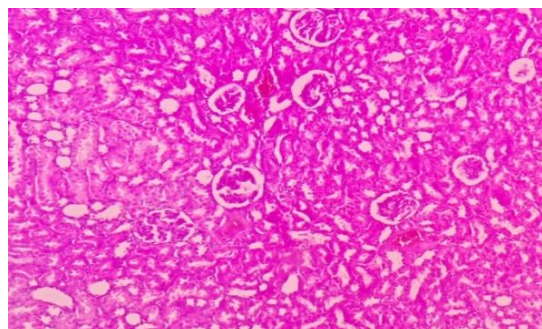
**Fig. 1.2. Group 2**



**Fig. 1.3. Group 3**



**Fig. 1.4. Group 4**



**Fig. 1.5. Group 5**

**Chart 1. Drug administration**

SI No.	Animal Group	Drug Administration
1	Group 1	Normal drinking water
2	Group 2	Gentamicin 40mg/kg (i.p)
3	Group 3 (low dose)	Gentamicin 40mg/kg (i.p) + Plant extract 100mg/kg (oral)
4	Group 4 (mid dose)	Gentamicin 40mg/kg (i.p) + Plant extract 200mg/kg (oral)
5	Group 5 (high dose)	Gentamicin 40mg/kg (i.p) + Plant extract 400mg/kg (oral)

Fig. 1.1 represents the normal kidney tissue. Here we can see the tubular region that are in the shape of clear white space tubules that are large in numbers and the renal corpuscles in semicircular form that are spread across the renal cortex region. Inside the renal corpuscles there is glomerular structure.

Fig. 1.2 shows the distortion of renal corpuscles and glomerular structure. The distal and proximal tubules had loss of cellular boundary. The epithelial cells of tubular structure were desquamated

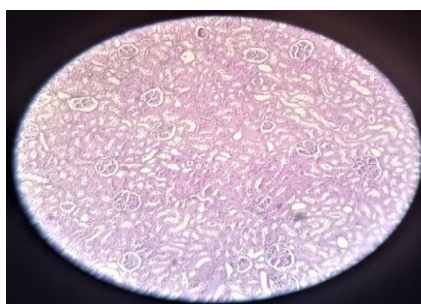
In Fig. 1.3 there is slight recovery of renal corpuscles against gentamicin induced nephrotoxicity. The renal tubular structures are moderately gaining to its normality but most of them are still have necrotic epithelial cells,

widening of bowman's space and thickening of glomerular cells

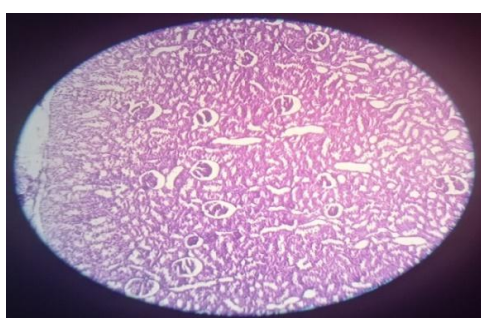
Fig. 1.4 represents the improvement in condition of rat kidney tissue with graded increase in the dose of plant extract against gentamicin induced renal damage when compared with Group II of the experimental group.

Fig. 1.5 shows attenuation from adverse effects of gentamicin induced nephrotoxicity. There is recovery in the structure of renal corpuscles especially the bowman capsule and also regaining of renal tubular cells to normal form. Signs of amelioration of renal tubules and glomeruli are seen however mild desquamation and roughness in the brush border of the tubular cell are observed in some parts of kidney tissue microscopic images.

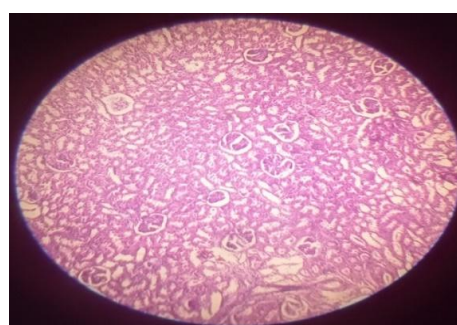
*Histopathological observation of Rat kidney tissue of Paracetamol induced nephrotoxicity methodology experiment*



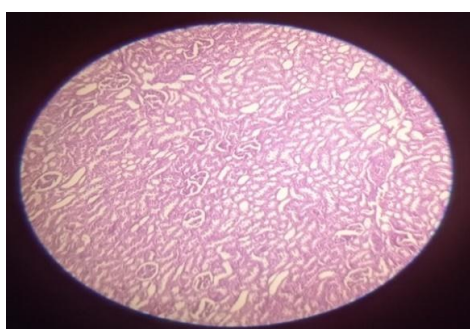
**Fig. 2.1. Group 1**



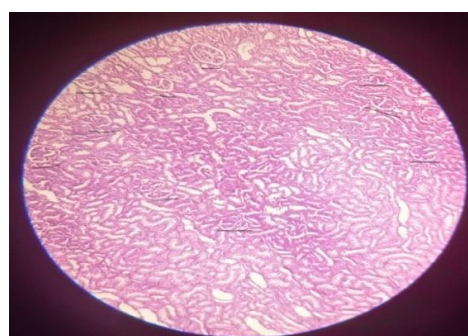
**Fig. 2.2. Group 2**



**Fig. 2.3. Group 3**



**Fig. 2.4. Group 4**



**Fig. 2.5. Group 5**

**Chart 2. Drug administration**

SI No.	Animal Group	Drug Administration
1	Group 1	Filter water
2	Group 2	Paracetamol 200 mg/kg (i.p)
3	Group 3 (low dose)	Paracetamol 200 mg/kg (i.p) + Plant extract 100mg/kg (oral)
4	Group 4 (mid dose)	Paracetamol 200 mg/kg (i.p) + Plant extract 200mg/kg (oral)
5	Group 5 (high dose)	Paracetamol 200 mg/kg (i.p) + Plant extract 400mg/kg (oral)

In Fig. 2.1 tissue sample of the kidney depicts the presence of renal corpuscle, distal as well as proximal renal tubules. Its epithelial cells as well as connective tissues at the base line tissue material are observed.

In Fig.2.2: The histopathological change of rat kidney tissue of group 2 reveals the disorientation of renal corpuscles structure, widening of Bowman's capsule space with glomerular incassate and renal tubular damage.

The brush borders of tubular cells had interstitial edema and degeneration of epithelial cells.

In Fig. 2.3: The microscopic image of rats' kidney tissue of Group III represents gradual recovery against paracetamol induced nephrotoxicity. The renal tubular cells returning to its typical form are seen. The damages of renal corpuscles are still present.

In Fig.e 2.4: The kidney tissue section of Group IV shows progress in healing effects by decreasing the lesions along the tubular lines and vacuolation of epithelial cells. The glomerular were not affected but shrinkage in the size of renal corpuscles was still seen.

Fig. 2.5 represents the region that is more towards the renal medullary region, as a result more amount of renal tubular cells are seen with few numbers of renal corpuscles denoted by black lines. Normalization of kidney tissue section with occasional degenerative cells. Mild glomerular, peritubular congestion and inflammatory cells are observed.

From the histopathological observation [18] of the above two methodology it can be inferred that groups that was treated with toxic effect (Gentamicin 20mg/kg and paracetamol 200mg/kg) showed disorientation of renal corpuscles structure, widening of Bowman's capsule space with glomerular incassate and renal tubular damage. The brush borders of tubular cells had interstitial edema and degeneration of epithelial cells. The epithelial cells of tubular structure were desquamated. With increase in the dose of the plant extract there was gradual healing effect or the protective effect from the plant extract. There was normalization of kidney tissue section with occasional degenerative cells. mild glomerular, peritubular congestion and inflammatory cells were observed.

### 3.1 Discussion

In general nephrotoxicity occurs is mainly due to the side effect of chemotherapy. The reactive oxygen metabolites, accumulation of drug metabolites, kinetics of drug trapping process etc. are some of the factors that induce renal damage. Drug associated nephrotoxicity accounts for 18 to 27 % of all acute kidney injury cases. In the present study Gentamicin and paracetamol were used to induce nephrotoxicity to evaluate the ameliorative potential of ethanolic extract of *L.interrupta* leaf.

Present study shows that Gentamicin and Paracetamol has caused renal failure significantly characterized by decrease in body weight, increase in kidney weight, elevated levels of serum albumin, serum creatinine and serum total protein when compared to that of normal animals. These variations in biochemical parameter of renal function are well supported by histopathological parameters. Evidences suggest that high dose or long course treatment of Gentamicin induces nephrotoxicity via oxidative stress. Enhancement of oxidative stress is due to excessive production of oxygen free radical generation. Gentamicin binds with 16rRNA at the 30s ribosomal subunit disturbing the translation of mRNA leading to the accumulation of reactive oxygen species, as a result depletion of protein are involved in oxidation reduction that may lead to bacterial death on the other hand the generation of reactive oxygen species leads to cellular damage of various organs of the body. Paracetamol also induces acute or chronic renal damage but the mechanism behind this is not clearly well established. The pathophysiology behind nephrotoxicity due to paracetamol is attributed to isoenzyme mixed function oxidase present in the kidney; other reasons can also be due to prostaglandin sythetase and N – deacetylase enzymes. The ethanolic extract of leaves of *L.interrupta* and its preliminary phytochemical screening indicated the presence of alkaloids, carbohydrates, proteins and essential amino acids. The antioxidant property of this plant due to the phytoconstituent flavonoid especially rutin. Hence the probable mechanism of nephroprotection by this plant could be due to its anti- oxidant property and free radical scavenging property.

Thus this plant could be taken up for advanced research work to understand interaction of plant phytoconstituents with biological cell in establishing its potential to act as nephroprotective.

### 4. CONCLUSION

There are certain plants which act as irritant or as causative agent of allergic reaction and sometimes even toxic for the other living animals. This kind of nature of plant is actually its self-defense or to protect itself from the outside predators. These types of plant can be used as herbal remedy to treat different ailments and this is mainly based on the quantity of intake of it or otherwise called as dose of the drug. Hence the



plant *L.interrupta* is one such plant that causes itch on touch of it.

Extracts was orally administered to experimental animals in three different doses as low dose, mid dose and high dose. The effect of plant extract was assessed in terms of serum albumin, serum total protein, serum creatinine, percentage change in body weight. Histopathological studies were also done to support the results. Extracts treated groups of animals showed significant improvement in serum biomarkers and also the healing effects observed from histological study of the rat kidney.

The present study showed that the nephroprotective effect of *L.interrupta* is partially seen against the adverse effects induced by the gentamicin and paracetamol. However the total pharmacological interaction of plant extract and the biological are still not clear. The overall findings of this experiment through histopathological study and serum biochemical of certain parameters were supportive towards the healing effect from the causes of nephrotoxic problems. Further investigation of this plant can be done for research work to investigate the nephroprotective activity.

## CONSENT

It is not applicable.

## ETHICAL APPROVAL

The experimental protocols were approved by the Institutional Animal Ethical Committee (IAEC) and were performed according the ethical guidelines laid down by the Committee for the purpose control and supervision of experimental animals. (CPCSEA)

## ACKNOWLEDGMENTS

The authors would like to thank Nandikur Labs, Mangaluru for their kind support during histopathological and all other lab studies.

## COMPETING INTERESTS

Authors have declared that no competing interests exist.

## REFERENCES

1. Thamizh Selvam N, Surabhi KR, Vasantha Kumar KG, Deep VC, Acharya MV. Physico-chemical, Phytochemical and

Spectroscopic Characteristics of Aqueous and Methanolic Extracts of *Laportea interrupta* L. Chew Leaf. *Phytochemical Analysis*. 2016;9:13.

2. Tiwari SC, Husain NI. Biological activities and role of flavonoids in human health–A. *Indian J Sci Res*. 2017;12(2):193-6.
3. Al-Snafi AE, Talab TA. A review of medicinal plants with nephroprotective effects. *GSC Biological and Pharmaceutical Sciences*. 2019;8(1):114-22.
4. Lopez-Giacoman S, Madero M. Biomarkers in chronic kidney disease, from kidney function to kidney damage. *World journal of nephrology*. 2015;4(1):57.
5. Guzman JAS, Beltran RJL, Rubio R, Ramos GB. Potential of pre-gestational intake of *Laportea interrupta* L. (Stinging nettle) leaf decoction as an aid for foetal – maternal health. *Asian Pacific Journal of Reproduction*. 2015;4(2): 85-90.
6. Nitin M, Ifthekar SQ, Mumtaz M. Evaluation of hepatoprotective and nephroprotective activity of aqueous extract of *Vigna mungo* (Linn.) Hepper on rifampicin-induced toxicity in albino rats. *International Journal of Health & Allied Sciences*. 2012;1(2):85-87.
7. Majumdar K, Datta BK. Practice pattern of Traditional Pharmaceutical Formulations by the Tribes of Tripura, Northeast India. *Global Journal of Pharmacology*. 2013; 7(4):422-447.
8. Kalpana B, Devilal R, Goud MS, Shekar BC, Sadasivaiah B, Rao NB. *Laportea interrupta* (L.) Chew (Urticaceae)—A new distributional record from Central Eastern Ghats, India. *Journal of Biological Records*. 2016;9(16): 81-5.
9. Gaikwad K, et al. A review on some nephroprotective medicinal plants. *International Journal of Pharmaceutical Sciences and Research*. 2012;3(8): 2451
10. Hiscox JD, Israelstam GF. A method for the extraction of chlorophyll from leaf tissue without maceration. *Canadian journal of botany*. 1979;57(12):1332-4.
11. Krishna CS, Sajeesh T, Parimelazhagan T. Evaluation of nutraceutical properties of *Laportea interrupta* (L.) Chew. *Food Science and Biotechnology*. 2014;1 (2):577-585.
12. Erhirhie EO, Ihekwereme CP, Ilodigwe EE. Advances in acute toxicity testing: strengths, weaknesses and regulatory

- acceptance. *Interdisciplinary toxicology*. 2018;11(1):5.
13. Steinman TI. Serum albumin: its significance in patients with ESRD. In *Seminars in dialysis*. Boston, MA, USA: Blackwell Science Inc. 2000;13(6):404-408.
  14. Wilmer MJ, Ng CP, Lanz HL, Vulto P, Suter-Dick L, Masereeuw R. Kidney-on-a-chip technology for drug-induced nephrotoxicity screening. *Trends in biotechnology*. 2016;34(2):156-70.
  15. Amin KA, Hameid II HA, Abd Elsttar AH. Effect of food azo dyes tartrazine and carmoisine on biochemical parameters related to renal, hepatic function and oxidative stress biomarkers in young male rats. *Food and Chemical Toxicology*. 2010; 48(10):2994-9.
  16. Vysakh A, Abhilash S, Kuriakose J, Midhun SJ, Jyothis M, Latha MS. Protective effect of *Rotula aquatica* Lour against gentamicin induced oxidative stress and nephrotoxicity in Wistar rats. *Biomedicine & Pharmacotherapy*. 2018; 106:1188-94.
  17. Chinnappan SM, George A, Thaggikuppe P, Choudhary Y, Choudhary VK, Ramani Y, Dewangan R. Nephroprotective effect of herbal extract *Eurycoma longifolia* on paracetamol-induced nephrotoxicity in rats. *Evidence-Based Complementary and Alternative Medicine*; 2019.
  18. Brzóška MM, Kamiński M, Supernak-Bobko D, Zwierz K, Moniuszko-Jakoniuk J. Changes in the structure and function of the kidney of rats chronically exposed to cadmium. I. Biochemical and histopathological studies. *Archives of toxicology*. 2003;77(6):344-52.

© 2021 Shetty and Khandige; This is an Open Access article distributed under the terms of the Creative Commons Attribution License (<http://creativecommons.org/licenses/by/4.0>), which permits unrestricted use, distribution, and reproduction in any medium, provided the original work is properly cited.

*Peer-review history:*

*The peer review history for this paper can be accessed here:*  
<https://www.sdiarticle5.com/review-history/79722>