



Hepatoprotective Effects of Suberoylanilide Hydroxamic Acid (A Histone Deacetylase Inhibitor) in Immunological Liver Injury in Rats

A. Alhaddad^{1*}, H. Abdel Kawy¹, W. Ramadan¹ and A. Abbas¹

¹Department of Pharmacology, School of Medicine, King Abdulaziz University, Saudi Arabia.

Authors' contributions

This work was carried out in collaboration among all authors. Author HAK was the supervisor who designed the study and revised all materials. Author A. Alhaddad wrote the protocol, wrote the manuscript, managed the literature searches, performed the majorities of experiments and performed the statistical analysis. Author WR did the histological studies. Author A. Abbas was handling the animal care. All authors read and approved the final manuscript.

Article Information

DOI: 10.9734/JPRI/2019/v30i330271

Editor(s):

(1) Rafik Karaman, Professor, Department of Bioorganic Chemistry, College of Pharmacy, Al-Quds University, Jerusalem, Palestine.

Reviewers:

(1) Aamir Mushtaq, Pakistan.

(2) Juliano Augusto Brum Scheffer, IBRRA, Brazil.

Complete Peer review History: <https://sdiarticle4.com/review-history/50926>

Original Research Article

Received 05 June 2019
Accepted 17 August 2019
Published 19 October 2019

ABSTRACT

One of the main reasons for the development of chronic liver disease is autoimmune hepatitis (AIH). There is no clear etiological factor for AIH occurrence and no drug has been approved for its treatment. Vorinostat, a Histone deacetylase inhibitor (HDACi) has been shown to reduce inflammation. Our aim was to explore the therapeutic potential of vorinostat in a rat model of AIH induced by Concanavalin A (Con A). The rats were randomly divided into 4 groups; control group, con A (20 mg/kg/iv/wk) group, vorinostat (15 mg/kg/day p.o) group and Con A with vorinostat group. Blood and liver samples were collected at the end of the fourth and eighth weeks for biochemical and histopathological examinations. Results revealed that administration of Con A elevated aspartate aminotransferase (AST) and alanine aminotransferase (ALT) liver enzymes, which were reduced to 52.8% and to 61.8% respectively on simultaneous administration of Vorinostat as compare to Con A group. Furthermore, Vorinostat reduced fibrosis and diminished apoptosis as deduced by the decrease in the hepatic hydroxyproline content of the liver and tumor

*Corresponding author: E-mail: dr-alhaddadaa@hotmail.com;

necrosis factor-alpha levels. Relative gene expression analysis of interleukin 1 β and transforming growth factor beta were significantly decreased in groups treated with vorinostat. Histopathological analysis showed that administration of vorinostat significantly restored the well organized structure of the liver, decreased initial inflammation produced by Con A, reduced liver fibrosis and mitigated hepatic stellate cell's activities. In conclusion, administration of vorinostat in Con A model of autoimmune hepatitis, significantly decreased liver inflammation and fibrosis. So vorinostat might show a novel therapeutic approach for management of autoimmune hepatitis and its obstacles.

Keywords: Vorinostat; Concanavalin A; hepatitis; autoimmune hepatitis; hydroxyproline.

1. INTRODUCTION

Chronic liver disease is a worldwide health issue that affects about 81,000,000 persons annually around the world [1]. Autoimmune hepatitis (AIH) is one of the main reasons for the development of chronic liver disease and if left untreated or improperly managed, might lead to cirrhosis and liver carcinoma [2]. The occurrence of AIH is between 11% and 20% of the global population. AIH is an illness that usually affects females and children, however, it can also affect older individuals and males. Statistical data from Saudi Arabia have shown an onset of the illness at an earlier age in comparison to other Asian countries, Europe and the US [2].

One of the main characteristics of AIH is the loss of immune tolerance to the antigens which are located on hepatocytes and lead to impaired immune regulation. Up till now, no clear and distinguish cause has been recognized for triggering and initiating this liver damage that was caused by the immune system which is observed with AIH. However, there are numerous suggestions on some of the triggering risk factors that might play a role in AIH. Genetic predisposition is also thought to play a major role in the development of AIH [2].

Hepatic stellate cells (HSCs) are activated after continuous liver injury followed by their transformation to myofibroblast-like cells. These transformations conscribes different pro-inflammatory mediators and the accumulation of these mediators interrupts the normal function of the liver, which leads to the formation of fibrotic cells and more deteriorating effects such as hepatic cirrhosis or cancer [3].

Histone deacetylase (HDACs) plays a critical role in inflammation by coordinating the communication of intracellular signaling pathways, chromatin remodeling and transcriptional factors. In experimental animal research, pharmacological modulators of HDACs

have shown a strong anti-inflammatory outcome [4]. Moreover, inhibition of HDACs generally results in apoptosis and impairs growth in certain cancer cell line [5].

Suberoylanilide hydroxamic acid (SAHA), an HDAC inhibitor that has a trade label of vorinostat, was the first HDAC inhibitor approved by the food and drug administration (FDA) to treat certain cutaneous T-cell lymphoma. It has been shown that vorinostat has the ability to enhance liver function and reduce liver fibrosis. However, the mechanism of action behind that is still not clear. The dose of vorinostat used in the treatment of cancer is higher than the dose used in inflammation [6].

The T-cells mitogen concanavalin A (Con A) has been used in inducing immune-mediated liver injury. This plant mitogen has the potential to activate T-cells and their precursors [7]. One of the unique characteristics of Con A model is the pathogenesis similarities to human immune-stimulated hepatitis, such as autoimmune hepatitis, acute viral hepatitis or certain kind of drug toxicity leading to immune activation [8]. Injections of a large amount of Con A might cause acute hepatitis, while repeated small doses of Con A might produce chronic hepatitis [9].

The main goal of this study was to explore the therapeutic potential of administration of vorinostat, in a rat model of AIH induced by Con A. Changes in the liver biochemical and histological markers were measured. An attempt was made to evaluate the underlying molecular mechanisms of vorinostat on HSCs activity and other signaling inflammatory pathways.

2. MATERIALS AND METHODS

2.1 Drugs and Chemicals

Vorinostat was purchased from Advanced Engineering, WI, USA and was dissolved in

Dimethyl sulfoxide (DMSO) [10]. Concanavalin A (Con A) was purchased from Advanced Engineering, WI, USA with a molecular weight of 112 KDa and was supplied in a one-gram bottle in the form of white to off-white powder and was dissolved in saline for intravenous injection [11].

2.2 Experimental Protocol

All animal procedures were approved by the research animal ethics committee at King Abdul-Aziz University, faculty of medicine. The number of registration at National Committee of Bio and Medical ethics is HA-02-J-008. Forty-eight Wistar male rats (weighing 150 to 200 g) were purchased from an animal house in King Fahd Center for Medical Research (KFMRC). The rats were housed in an animal room with temperature (22°C) and lighting (12 h light– dark cycle) for an adaptation period of 1 week and saline as a vehicle of drug administration was allowed before initiation of the experimental protocol.

2.3 Animal Grouping

Rats were randomly divided into 4 groups, 12 rats in each group. Group 1 (control group): Normal control group, rats were given intravenously normal saline in the tail vein once in a week and a daily vehicle (DMSO) via gastric gavage. Group 2 (Con A group): rats received intravenously 20 mg/kg of Con A in the tail vein once a week. Group 3 (Vorinostat group): rats were given daily vorinostat (15 mg/kg) by gastric gavage. Group 4 (Combination of the two studied medication group): rats receive Con A as in group II, alongside were given daily Vorinostat (15 mg/kg) by gastric gavage.

The dose of Concanavalin A for induction of liver damage [8] and the dose of Vorinostat that examines the protective effect of vorinostat in inflammation [12], were chosen from previous studies.

2.4 Induction of Liver Inflammation and Fibrosis by Concanavalin A

A model of autoimmune hepatitis was induced by intravenous injection of Con A in male Wistar rats. To establish chronic hepatitis and liver fibrosis, 20 mg/kg, Con A was intravenously injected into rat's tail veins once a week for 4 and 8 weeks [13].

2.5 Blood and Liver Samples Preparation

Rats were euthanized at the end of the experiment by using deep ether anesthesia. The

effective concentration of ether to produce anesthesia is 1.9%. Blood samples were collected from the tail vein of rats of all groups and livers were collected (6 rats each time) by the end of the fourth and eighth weeks of injections of Con A for biochemical and histopathological analysis. After rats sacrificed, livers were rapidly removed at the end of the 4th and 8th weeks of the experiment. The right lobe of the livers were removed, cut into thin slices and kept in 10% formalin for histological and immunohistochemical examination. The left lobe was frozen (–80°C) for the assessment of hepatic hydroxyproline contents, tumor necrosis factor alpha level and genes expression analysis by real-time PCR for Interleukin 1 β and Transforming growth factor β .

2.6 Biochemical Measurements

2.6.1 Serum Alanine Aminotransferase (ALT) and Aspartate Aminotransferase (AST) levels

Blood was collected from tails and retro-orbitals of all groups and left to clot for 15 minutes at room temperature and then centrifuged at 3500 r.p.m (Rotation per minute) for 15 minutes to separate the serum so as to determine serum AST and ALT level.

2.6.2 Measurement of hepatic hydroxyproline contents

Measuring the level of hydroxyproline is considered a critical step in evaluating fibrosis and an indicator of hepatic stellate cell activity [14]. In this experiment, scarifications of rats have been done twice; at the end of the fourth and eight weeks of treatment. Liver samples were centrifuged for 20 min at 1000 x g. Liver hydroxyproline was measured by a Sandwich of the enzyme-linked immunosorbent assay (ELISA) kit that purchased from lifespan Bio Sciences, Inc. The content of hydroxyproline was measured as $\mu\text{g/ml}$ of the samples.

2.6.3 Determination of hepatic tumor necrosis factor alpha (TNF- α)

This assay utilizes a sandwich kit for the accurate quantitative detection of TNF- α . It is an enzyme-linked immunosorbent assay (ELISA) of Bioassay Technology Laboratory, Shanghai, China. TNF- α present in the sample binds to the antibody coated on the walls. After that, a biotinylated rat TNF- α is added and will also bind

to TNF- α in the sample. And then streptavidin-horseradish peroxidase (HRP) is added and binds to TNF- α antibody. The unbound streptavidin-HRP is washed away. A substrate solution is then added, and color develops in proportion to the amount of TNF- α present in the sample. An acidic stop solution is then added to terminate the reaction. The absorbance is measured at 450 nm.

2.7 Gene Expression Analysis by Real-time PCR for Hepatic Interleukin 1 β (IL-1 β) and Transforming Growth Factor β (TGF- β)

The gene expression for IL-1 β and TGF- β levels were amplified from cDNA using the QuantiTect SYBR Green PCR Kit cat no: 204141 (Qiagen, Germany) and the QuantiTect primer assays cat no: 249900 [(Rn_IL-1 β _1_SG QuantiTect Primer Assay, ID(QT00181657) and (Rn_Tgfb1_1_SG; ID QT00190953)]; respectively. The (Rn_Actb_1_SG; ID QT00193473) Primer sequence was used as a housekeeper gene. All samples were analyzed using the 5 plex Rotor-Gene PCR Analyzer (Qiagen, Germany). The $2^{-\Delta\Delta Ct}$ method was conducted for the analysis of gene expression levels, using ACTB as an endogenous reference control for normalization purposes.

2.8 Histopathological Studies

2.8.1 Histological preparation for routine staining

Samples of the liver kept in 10% neutral phosphate-buffered formalin were processed into paraffin blocks. Five-micrometer-thick sections were stained with Hematoxylin and Eosin (H&E), used for studying general histology. Masson's trichrome staining was used to study the collagen fiber contents [15]. Visualization and photographing of the slides were done using an Olympus light microscope (model: BX51TF-Japan).

2.8.2 Tissue preparation for routine immunostaining

The preparation for the immunostaining procedure was completed according to the process that was described by Yu [16]. The staining for alpha-smooth muscle actin (α SMA) was performed and after blocking, the excess

blocking serum was discarded, followed by incubation of slides with mouse monoclonal antibody SMA-CAT NO-7602601 and P53 CAT NO -6012332 individually. Each slide was diluted individually in TBST for 60 minutes. Following washing, the slides were incubated for 30 minutes in mouse-specific EnVision+System-HRP (Dako UK Ltd, Ely, UK), and envisioned by incubation in (DAB) for 10 minutes. Staining was negatively coordinated by exchanging mouse immunoglobulin (Ig) fraction and diluted to the exact Ig concentration of the primary antibody.

2.9 Statistical Analysis

A statistical study was conducted using graph pad prism version 8 (2019), USA. All data were given as means plus standard error of the mean. For comparison of the different groups, analysis of variance (ANOVA) was calculated with significance set at $< P 0.05$. When an ANOVA test was significant, it is followed by Tukey test for multiple comparisons between groups.

3. RESULTS

The outcome of vorinostat on liver injury stimulated by repetitive administration of Con A:

3.1 Biochemical Markers

3.1.1 The influence of vorinostat on serum AST levels of Con A-treated rats

Fig. 1. shows that administration of Con A at week 4 and week 8 produced a significant ($P<0.05$) increase in the serum AST level compared to the corresponding control normal group. The serum AST level increased from 38.8 ± 6.8 to 123.7 ± 8.3 IU/L in Con A group with a mean percentage value of 218.8% at 4 weeks and from 37.8 ± 7.9 to 141 ± 8.8 IU/L with a mean percentage value of 273% at 8 weeks.

After 4 weeks, there was a significant ($P<0.05$) decrease in serum AST level in rats that received vorinostat in combination with Con A to 74.8 ± 9.9 IU/L, in comparison to Con A control group with a mean percentage value of 39.5%. After 8 weeks, there was a significant ($P<0.05$) decrease in the AST level in rats that received vorinostat in combination with Con A to 66.5 ± 3.1 IU/L, in comparison to Con A control group with a mean percentage value of 52.8%. No significant differences were detected between vorinostat and vehicle control group.

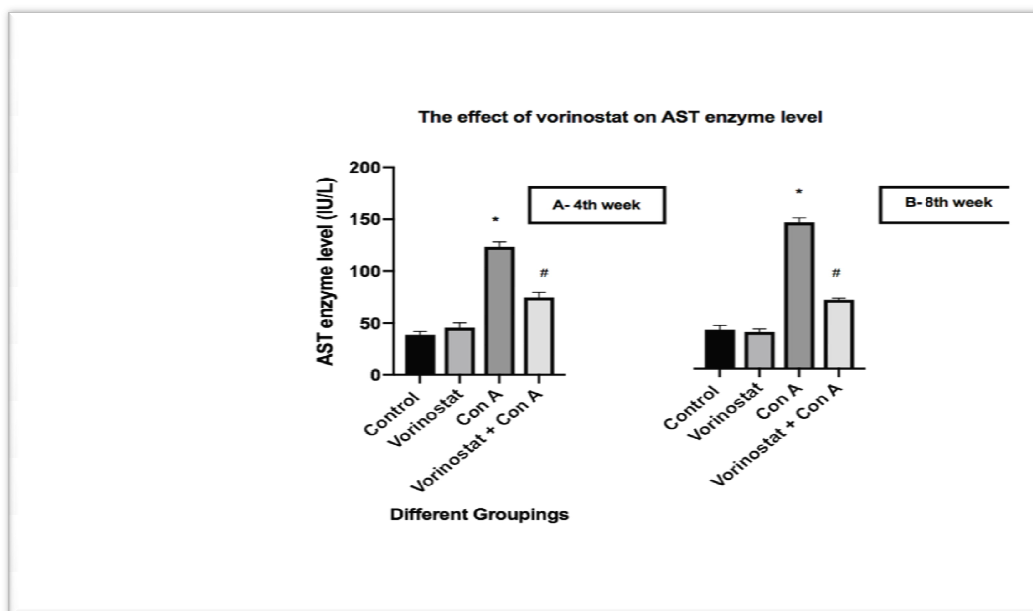


Fig. 1 (A and B). Effects of vorinostat on serum aspartate aminotransferase (AST) levels in control rat treated with a vehicle control group; Vorinostat treated group (15 mg/kg/day, orally), Con A treated rats (20 mg/kg g, i.v. once a week), and combination group of Vorinostat and Con A (20 mg/kg g, i.v. once a week) for 4 weeks (A) and for 8 weeks(B). Bar chart signifies mean \pm S.E.M of 6 rats, *P < 0.05, vs vehicle control group, #P < 0.05 vs Con A, by one-way ANOVA

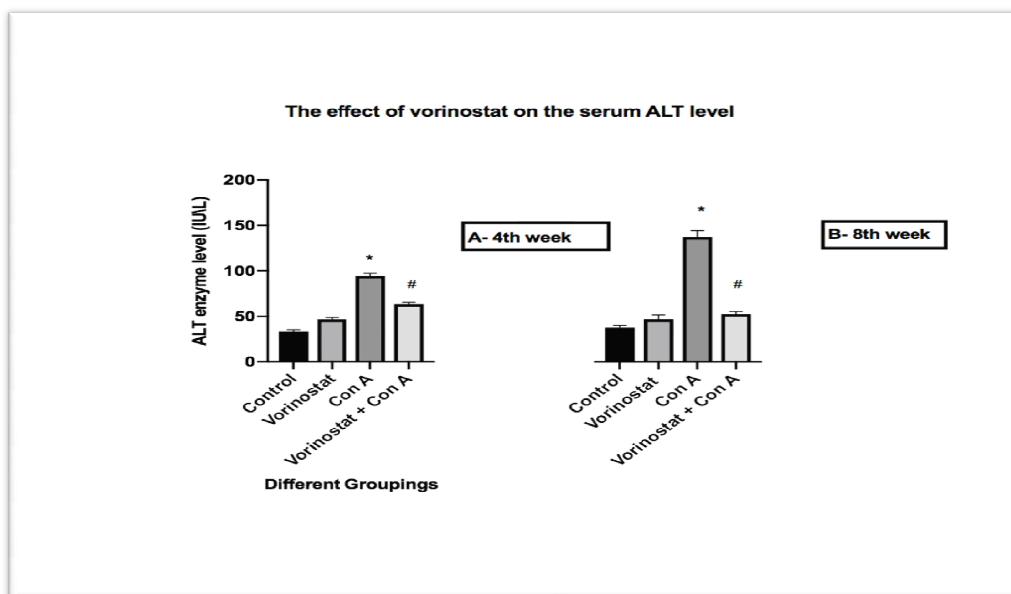


Fig. 2 (A and B). Outcomes of Vorinostat on serum alanine aminotransferase (ALT) levels in control rat treated with vehicle group (saline); Vorinostat treated group (15 mg/kg/day, orally), Con A treated rats (20 mg/kg g, i.v. once a week), and combination group of Vorinostat and Con A (20 mg/kg g, i.v. once a week) for 4 weeks (A) and for 8 weeks (B). Bar chart signifies mean \pm S.E.M of 6 rats, *P < 0.05, vs untreated control group, #P < 0.05 vs Con A, by one-way ANOVA

3.1.2 The influence of vorinostat on serum ALT levels of Con A-treated rats

Fig. 2. shows that administration of Con A for 4 weeks and for 8 weeks produced a significant ($P < 0.05$) increase in the serum ALT level compared to the corresponding normal control group. The serum ALT level was increased with Con A from 33.75 ± 2.9 to 94.7 ± 4.7 IU/L with a mean percentage value of 180.1% after 4 weeks and from 37.5 ± 5.6 to 137.3 ± 14 IU/L with a mean percentage value of 266.1% after 8 weeks compared to the normal control group.

After 4 weeks, there was a significant ($P < 0.05$) decrease in serum ALT levels in rats that received vorinostat in combination with Con A to 63.5 ± 3.4 IU/L, in comparison to Con A control group with a mean percentage value of 32.9%. After 8 weeks, there was a significant ($P < 0.05$) decrease in ALT level in animals that received vorinostat in combination with Con A to 52.5 ± 5.6 IU/L, in comparison to Con A control group with a mean percentage value of 61.8%. No significant differences were detected between vorinostat and vehicle control group.

3.1.3 The effects of oral administration of vorinostat on hepatic hydroxyproline contents in Con A treated rat

Fig. 3. Shows that administration of Con A for 4 weeks and for 8 weeks produced a significant ($P < 0.05$) increase in hepatic Hydroxyproline content compared to the corresponding control normal group. The hepatic Hydroxyproline content was increased with Con A from 17.2 ± 1.7 to 66.5 ± 13.2 (ng/g tissue) with a mean percentage value of 286.6% after 4 weeks and from 13.8 ± 3.4 to 69.4 ± 3.7 (ng/g tissue) with a mean percentage value of 402.9% after 8 weeks.

After 4 weeks, there was a significant ($P < 0.05$) decrease in hepatic Hydroxyproline content in rats that received vorinostat in combination with Con A to 29.5 ± 2.9 (ng/g tissue), in comparison to Con A control group with a mean percentage value of 55.6%. After 8 weeks, there was a significant ($P < 0.05$) decrease in hepatic Hydroxyproline content in rats that received vorinostat in combination with Con A to 31 ± 8.8 (ng/g tissue), in comparison to Con A control group with a mean percentage value of 55.3%. No significant differences were detected between vorinostat and vehicle control group.

3.1.4 Effects of oral administration of vorinostat on hepatic tumor necrosis factor alpha (TNF- α)

In Fig. 4, after eight weeks, the quantities of the hepatic TNF- α were significantly raised by Con A ($P < 0.05$) in comparison with the control group from 119.65 ± 3.5 to 145.55 ± 3.5 and with a mean percentage value of 21.6%. The administration of vorinostat in combination with Con A significantly decreased the levels of TNF- α as compared to the Con A group to 96.78 ± 33.5 with a percentage reduction of 33.5% at 8th weeks ($P < 0.05$). No significant differences were detected between vorinostat and vehicle control group.

3.2 Gene Expression Analysis by Real-time PCR for Interleukin 1 β (IL-1 β) and Transforming Growth Factor β (TGF- β)

Fig. 5. shows that administration of Con A for 4 weeks and for 8 weeks produced a significant ($P < 0.05$) increase in the hepatic TGF- β level and IL-1 β compared to the corresponding normal control group. The hepatic TGF- β level was increased with Con A from 0.98 ± 0.6 to 117.78 ± 6.8 (copies/ul) tissue with mean percentage value of 119.2% after 4 weeks and from 1.03 ± 0.57 to 133.44 ± 5.44 (copies/ul) tissue with mean percentage value of 128.6% after 8 weeks compared to normal control group.

Administration of vorinostat in combination with Con A for 4 weeks and for 8 weeks significantly ($P < 0.05$) reduced the hepatic TGF- β levels to 32.67 ± 6.03 and to 19.3 ± 3.3 (copies/ul) respectively, compared with Con A control group with a mean percentage value of 72.3% and 85.7% respectively. No significant differences were detected between vorinostat and vehicle control group.

Fig. 6. showed that administration of Con A (20 mg/kg, i.v. once a week) produced a significant increase in levels of IL-1 β as compared to the control treated group. While the co-administration of vorinostat in combination with Con A group produced a significant reduction in IL-1 β levels as compared to the Con A group with a percentage reduction of 30.3%, 75% by the end of 4th and 8th weeks respectively ($P < 0.05$). No significant differences were detected between vorinostat and vehicle control group.

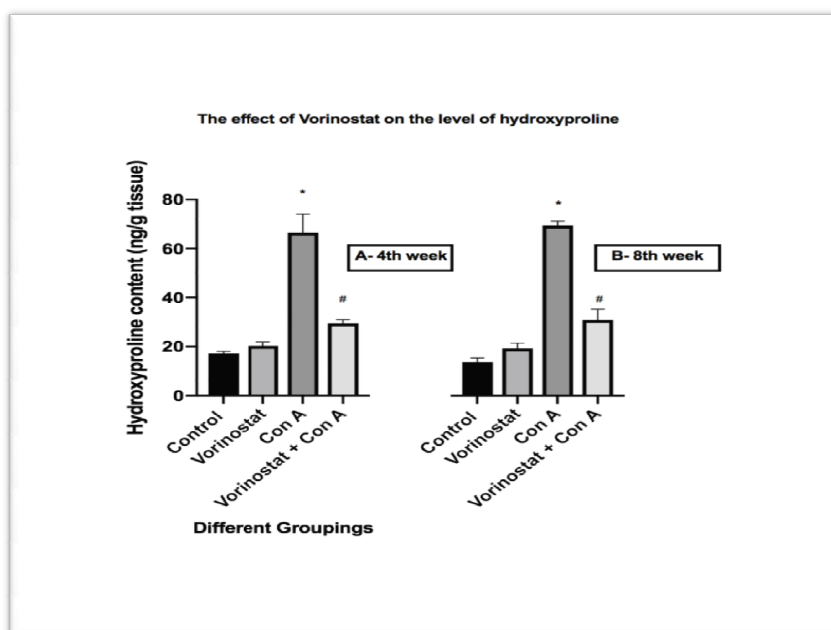


Fig. 3 (A and B). Outcomes of Vorinostat on hepatic hydroxyproline levels in control rat treated with vehicle group (saline); Vorinostat treated group (15 mg/kg/day, orally), Con A treated rat (20 mg/kg g, i.v. once a week), and combination group of Vorinostat and Con A (20 mg/kg g, i.v. once a week) for 4 weeks (A) and for 8 weeks (B). Bar chart signifies mean \pm S.E.M of 6 rats, *P < 0.05, vs untreated control group, #P < 0.05 vs Con A, by one-way ANOVA

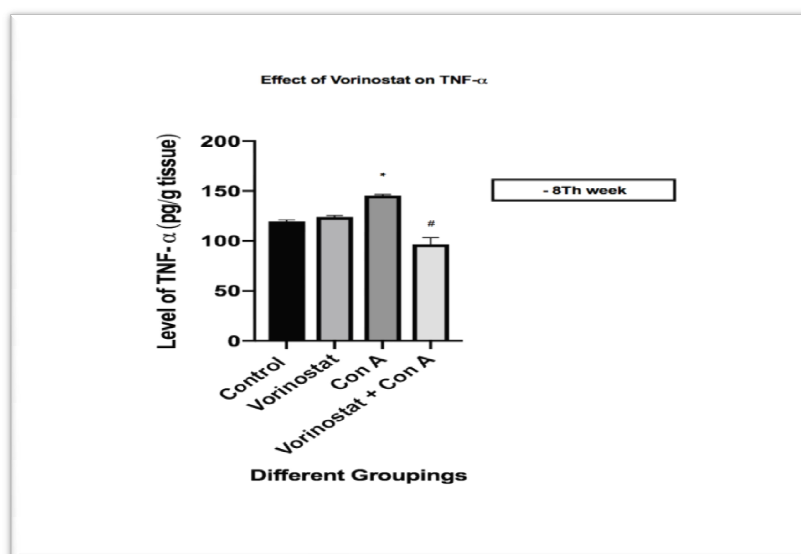


Fig. 4. Outcomes of vorinostat on hepatic tumor necrosis factor alpha (TNF- α) levels in control rat treated with vehicle group (saline); vorinostat treated group (15 mg/kg/day, orally), Con A treated rat (20 mg/kg g, i.v. once a week) and combination group of vorinostat and Con A (20 mg/kg g, i.v. once a week) for 8 weeks (B). Bar chart signifies mean \pm S.E.M of 6 rats, *P < 0.05, vs untreated control group, #P < 0.05 vs Con A, by one-way ANOVA

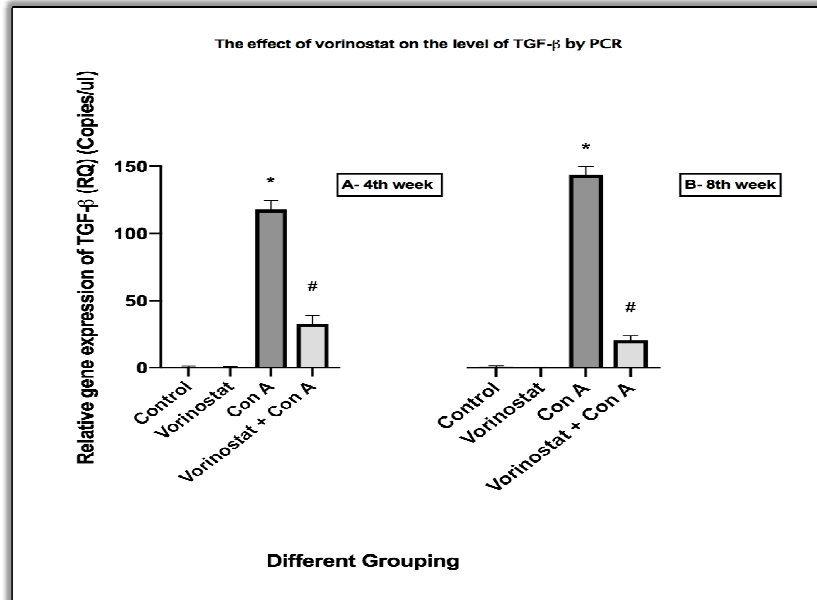


Fig. 5. Outcomes of vorinostat on TGF-β levels in control rat treated with vehicle group (saline); vorinostat treated group (15 mg/kg/day, orally), Con A treated rats (20 mg/kg g, i.v. once a week), and combination group of vorinostat and Con A (20 mg/kg g, i.v. once a week) for 4 weeks (A) and for 8 weeks (B). Bar chart signifies mean ± S.E.M of 6 rats, * P < 0.05, vs untreated control group, #P < 0.05 vs Con A, by one-way ANOVA

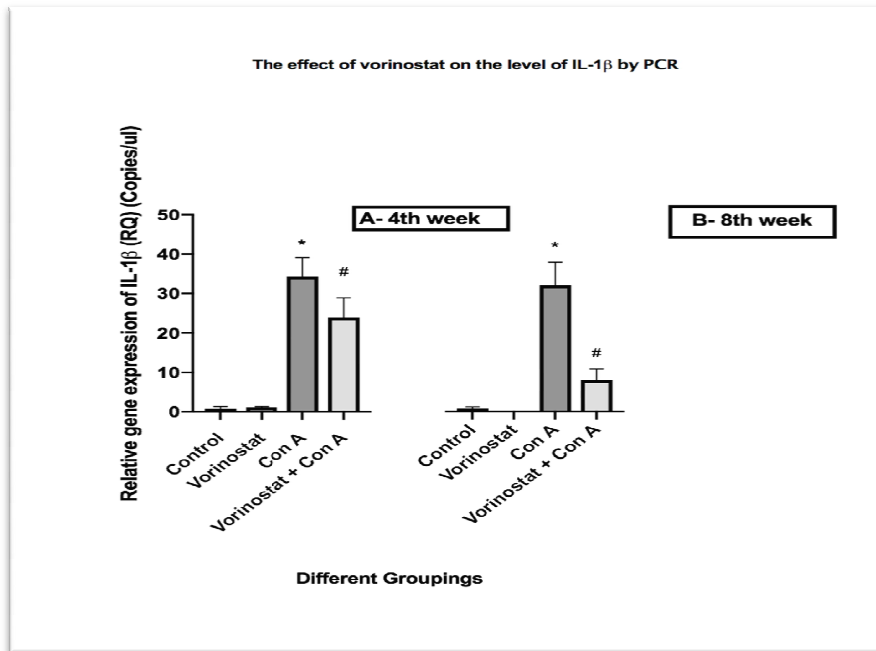


Fig. 6. Outcomes of vorinostat on Interleukin 1β (IL-1β) levels in control rat treated with vehicle group (saline); Vorinostat treated group (15 mg/kg/day, orally), Con A treated rats (20 mg/kg g, i.v. once a week) and combination group of vorinostat and Con A (20 mg/kg g, i.v. once a week) for 4 weeks (A) and for 8 weeks (B). Bar chart signifies mean ± S.E.M of 6 rats, * P < 0.05, vs untreated control group, #P < 0.05 vs Con A, by one-way ANOVA

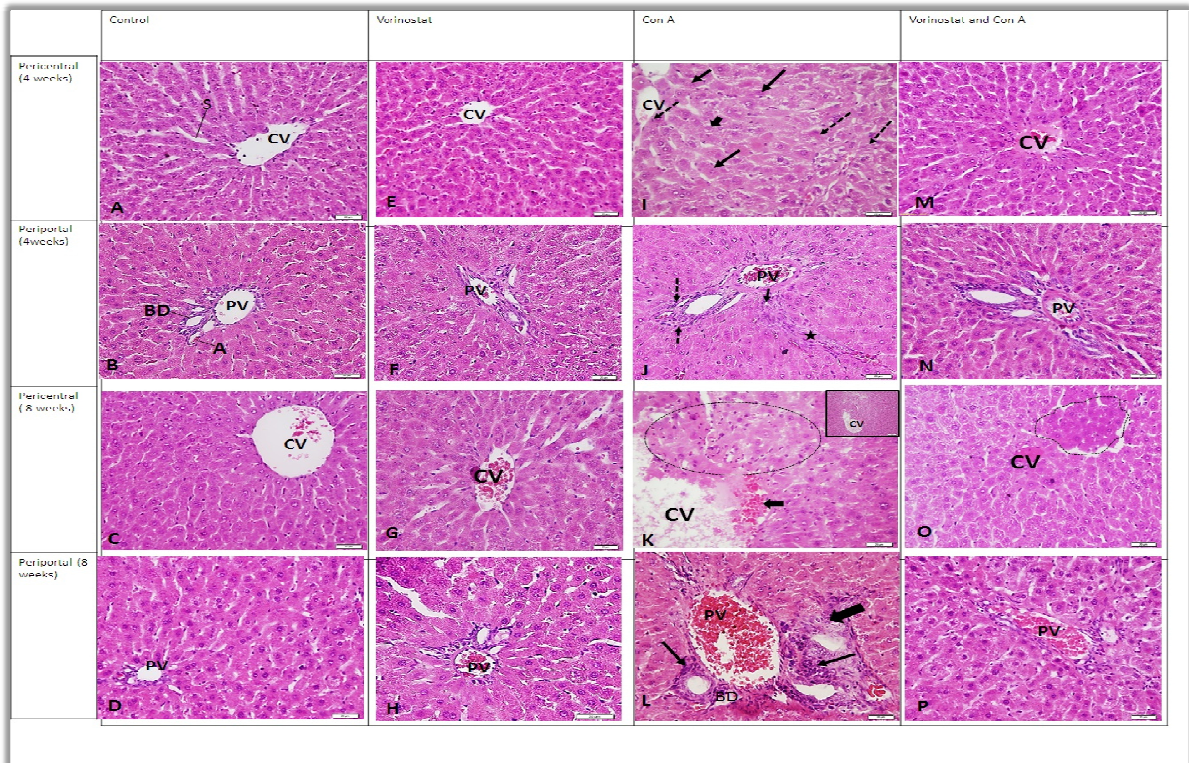


Fig. 7. Photomicrographs of liver sections of the control group shows normal structure in the pericentral and periportal zones (A-D). Groups administered VOR for 4 weeks and 8 weeks revealed no structural alteration of the liver (E-H). Groups administered CON A for 4 weeks show multiple hepatocytes with an apoptotic feature in the pericentral area (thin arrows), fragmented nuclei (dashed arrows) or vacuolated cytoplasm (thick arrow). In the periportal zone, polymorphonuclear cell infiltration (dashed arrows) and spindle-shaped nuclei of CT cells, disrupting the architecture of the liver (star) are noted (I-J). Sections of livers administered Con A for 8 weeks show a ruptured wall of (CV) with localized areas of hemorrhage (arrow), and disturbed architecture (dotted circle). Note an inset showing lower magnifications of congested dilated PV, polymorphonuclear cell infiltration (arrows), proliferated dilated (BD) and fragmented hepatocytes with no cell boundaries (thick arrow) (K-L). Treatment with VOR markedly revealed the altered histopathological picture after 4 and 8 weeks (M-P). Also indicated are CV: central vein, PV: portal vein, CT: connective tissue, BD: Bile ducts (H&E x400)

3.3 Histopathological Modifications in the Concanavalin A Induced Chronic Liver Injury

In the present study sections of the liver from rats in the control group stained with Hematoxylin and eosin stain (H&E) revealed cords of normal polygonal hepatocytes with central vesicular nuclei radiating from the central vein (CV) and separated by a sinusoid. In the periportal area (PT), portal vein (PV), hepatic artery (A) and bile duct (BD) are noted (A-D). This structure was similar to those administered in VOR (E-H).

Group administered Con A for 4 weeks reveals numerous hepatocytes in the vicinity of the central vein with deep eosinophilic cytoplasm and hypercatic condensed pyknotic nuclei, fragmented nuclei and vacuolated cytoplasm. Polymorphonuclear cell infiltration in the periportal area was noted and spindle-shaped nuclei of CT cells, disrupting the architecture of the liver (I-J).

Group administered Con A for 8 weeks revealed a ruptured wall of a central vein with localized areas of hemorrhage, disorganized pattern of hepatocytes and disturbed normal architecture

where hepatocytes are shrunk with deeply acidophilic cytoplasm and pyknotic nuclei. The periportal zone exhibited congested dilated portal vein (PV), apparent increase in the polymorphonuclear cell infiltration and proliferated dilated bile ducts (BD). Deep acidophilic hepatocytes in the vicinity of the portal tract appear homogenous with no cell boundaries (K-L).

Treatment with vorinostat markedly ameliorated the pathological effect of Con A on the structure of the liver and regained most of the normal structural features. Only localized areas of apoptotic cells are noted in the field (M-P) (Fig. 7) (H&E x 400).

Sections stained with Masson's trichrome revealed normal distribution and deposition of the

blue colored collagen fibers in the control group around CV and PT zones (A-D) and those administered VOR (E-H). Groups administered Con A for 4 weeks revealed an apparent increase of collagen deposition around the CV and PT which is further enhanced after 8 weeks (E-H). Simultaneous administration of VOR ameliorated collagen deposition after 4 and 8 weeks (I-L) (Fig. 8).

Groups administered Con A for 4 weeks revealed an apparent increase of collagen around the CV and PT which is further enhanced after 8 weeks (E-H). Simultaneous administration of VOR ameliorated collagen deposition after 4 and 8 weeks (I-L). CV: central vein, PT: portal tract, PV: portal vein (Masson trichrome' x 200).

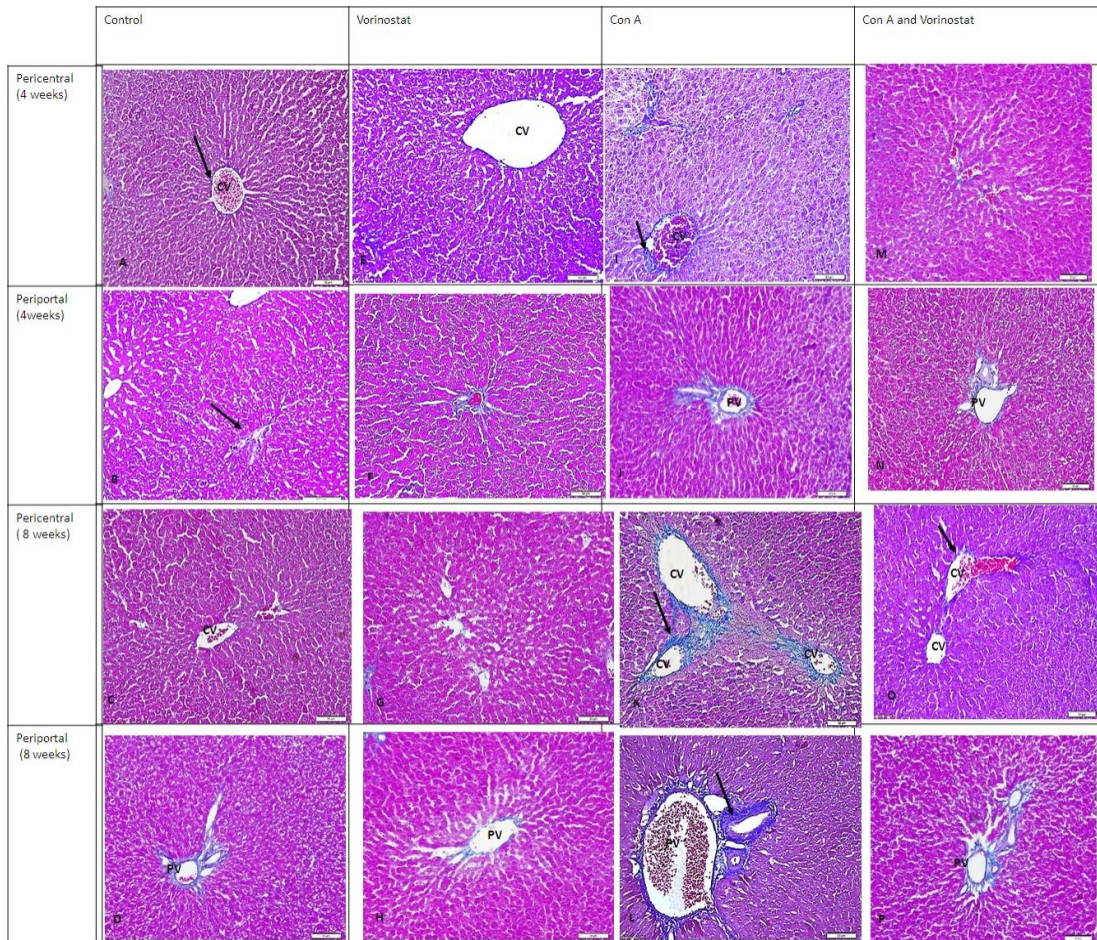


Fig. 8. Photomicrographs of liver sections showing normal distribution of blue colored collagen fibers in the control group around CV and PT zones (A-D) and those administered VOR (E-H)

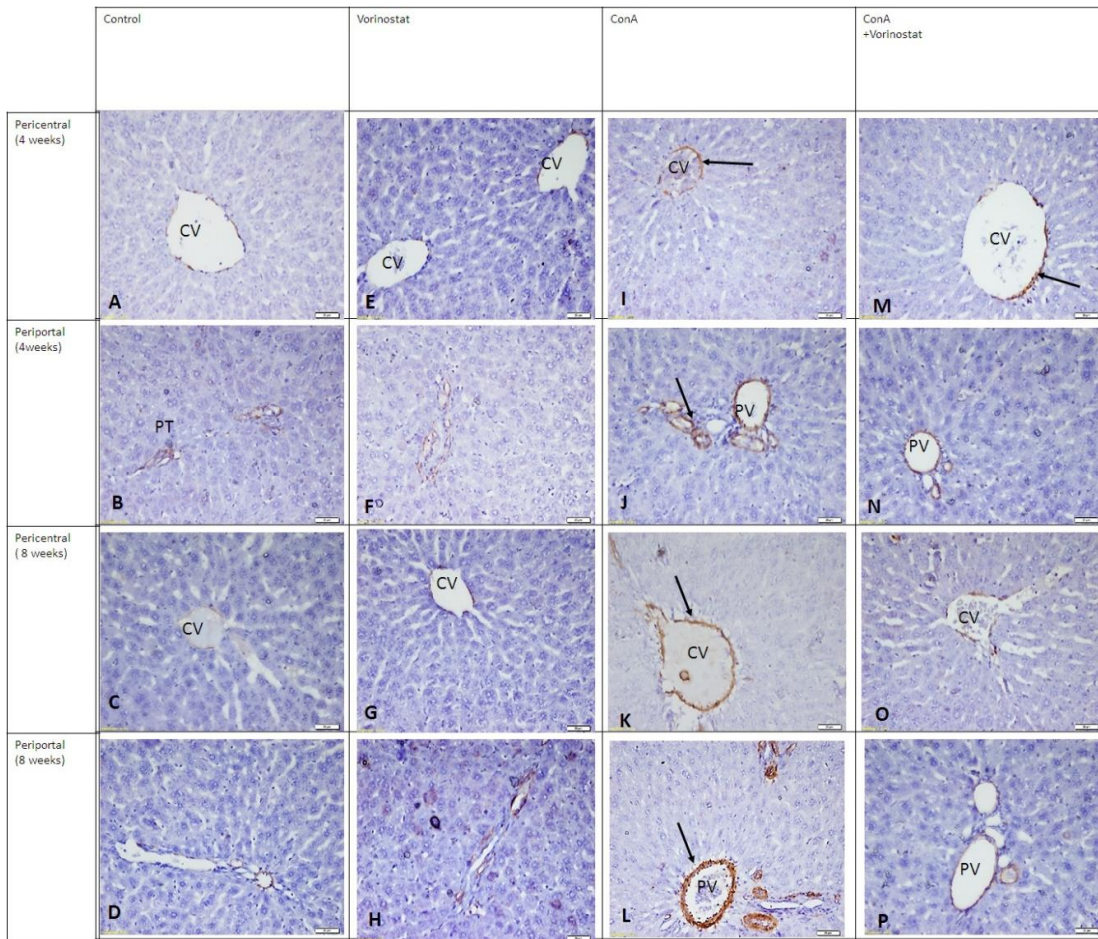


Fig. 9. Photomicrographs of immunostained liver sections showing normal expression of brown colored alpha-SMA in control group in the pericentral and periportal zones (A-D). Similar results appear in section administered VOR (E-H). Groups administered Con A for 4 weeks reveal apparent up-regulated expression of alpha-SMA around the CV and PT and is more intensified after 8 weeks (I-L). Treatment with VOR down-regulated the alpha-SMA reaction (M-P). (alpha-SMA x 200)

In the present study, immunostained liver sections exhibited normal expression of brown colored alpha-SMA in control group in the pericentral and periportal zones (A-D) and in those administered VOR (E-H). Groups administered CON A for 4 weeks revealed an apparent up-regulated expression of alpha-SMA around the CV and PT, which was more intensified after 8 weeks (I-L). Treatment with VOR down-regulated the alpha – SMA reaction induced by Con A (M-P). (alpha –SMA x 200).

According to the cell components measurements in Table 1, data showed statistical increase in the cytoplasmic area of the Con A treated group and minimum change in the nucleus area compared

to the control group. This increase in the cytoplasmic area and shrinkage of nucleus supported the characteristic morphology of apoptosis. In the combination group, the area of cytoplasm reduced compared to the area of Con A group and that might support the role of vorinostat in preventing or inhibiting the apoptosis process that is produced by Con A. No significant differences were detected between vorinostat and vehicle control group. Also in the table, statistical increase in the level of collagen fiber as seen in the stained area in Con A group, especially at the end of 8th week and reduction in that collagen fiber content in the combination group as compared to Con A group. No significant differences were detected between

Table 1. Morphometric measurement by quantitative parameters of the cytoplasmic area, nuclear area of hepatocytes, area percentage of collagen fibers stained by Masson trichrome in sections of liver and area percentage of Alpha-smooth muscle actin (α -SMA) immune stained cells in all different groups. Data are expressed as mean \pm SD and the unit of measurement is μm and p -value < 0.05 by one-way ANOVA. * $P < 0.05$, vs untreated control group, # $P < 0.05$ vs Con A, by one-way ANOVA

Rats groups (n=6)	Control	Vorinostat	Con A	Vorinostat + Con A
Morphometric measurement by quantitative parameters of the cytoplasmic area				
4 th week	70.7 \pm 9.2	65.6 \pm 6.7	134.1 \pm 23.3*	40.4 \pm 12.1 #
8 th week	76.4 \pm 6.6	72.7 \pm 9.3	90.2 \pm 12.2 *	67.7 \pm 7.8 #
Morphometric measurement by quantitative parameters of the nuclear area of hepatocytes				
4 th week	14.1 \pm 1.8	16.4 \pm 4.9	20.9 \pm 5.3	18.8 \pm 5.7
8 th week	13.9 \pm 3.6	13.5 \pm 4.1	9.1 \pm 2.7	16.1 \pm 3.4
Area percentage of collagen fibers				
4 th week	2.33 \pm 0.74	3.03 \pm 0.96	7.6 \pm 2.4*	4.6 \pm 1.4#
8 th week	2.27 \pm 0.72	3.07 \pm 0.97	18.6 \pm 5.9*	8.1 \pm 2.7#
Area percentage of α-SMA immune stained cells				
4 th week	3.7 \pm 1.3	4.9 \pm 1.5	24.3 \pm 2.1*	11.3 \pm 3.4#
8 th week	3.9 \pm 1.2	5.8 \pm 1.8	47.9 \pm 6.8*	31.4 \pm 4.6#

vorinostat and vehicle control group. Moreover, the area percentage of α -SMA immune stained cells were quantified and it revealed statistical elevation of the area stained for α -SMA in the Con A group, and reduction of the stained area in the combination group as compared to Con A. No significant differences were detected between vorinostat and vehicle control group.

4. DISCUSSION

The relationship between HDACs, cancer origination and development has been well studied in the past years. In addition to the role of HDAC inhibitors in the management of several types of cancer. Current findings suggested that the activity of HDAC is additionally connected to the initiation and progression of certain chronic disorders characterized by fibrosis, such as chronic kidney disease, cardiac hypertrophy and idiopathic pulmonary fibrosis [17].

In the current study, we used Con A stimulated chronic hepatitis model which closely mimics what occurs in autoimmune hepatitis disorder to offer a precise understating of the potential role of vorinostat in AIH pathophysiology and management. Induction of liver fibrosis by Con A has been broadly used to give more illustrations of the immune system mediated liver injury [18]. Following an intravenous injection of the lectin component in Con A in rats, stimulating the activated CD4⁺ T cells, natural killer T (NKT) cells and Kupffer cells have produced a huge quantity of the hepatotoxic cytokines like TNF- α

and interferon- γ (IFN- γ) [19]. Additionally, Reactive oxygen species have a critical function in immune-mediated Con A-stimulated hepatitis, possibly as a result of the immune-mediated liver damage [20]. A single bolus dose of Con A stimulated acute hepatitis, whereas repetitive doses stimulated chronic hepatitis. To induce hepatic fibrosis, continuous doses of Con-A are required to form chronic inflammation that leads to stimulation of continuous processes of tissue damage repairing [8].

Sensitive indicators of potential liver damage that are widely used are serum ALT and AST [8]. In the present findings, a significant elevation in serum level of transaminases enzymes at the fourth week of injection of Con A in rats was observed, but not in Vorinostat treated group. The results of these findings possibly suggest that Con A produce liver injury is consistent with the study of Mohamed, et al. (2013) and Lv, et al. (2012) who reported that Con A induces hepatitis and leads to elevation in ALT levels [21,22].

Another critical indicator of inflammation is the elevation of the hepatic content of hydroxyproline. This study also revealed that, Con A has the ability to induce inflammation by stimulating the massive production of hepatic hydroxyproline which is not the case in the vorinostat group. A similar finding was previously reported [23]. Vorinostat in this study has shown protective effects from liver injury in combination groups by significantly reducing the elevated levels of transaminase enzymes and also

reducing the hydroxyproline content in the combination groups which indicate the anti-inflammatory effects of vorinostat.

Fibrosis is characterized by abnormal growth and stimulation of fibroblasts. The term myofibroblast is described by the presence of activated form fibroblast. The myofibroblast is characterized by the stimulation of the expression of alpha-smooth muscle actin (α -SMA) and increased production of extracellular matrix (ECM) components. Stimulation and production of fibroblasts are activated by many growth factors and cytokines like transforming growth factor and interleukins [17]. Based on our study, Con A was successfully induced and activated fibroblasts by stimulating the tumor necrosis factor alpha (TNF α) which is a cytokine cell signaling protein that is elaborated in the general inflammation process and considered one of the cytokines that form the acute phase reaction of inflammation [24]. Vorinostat on the other hand protected hepatocyte by reducing TNF α in the combination group.

Interleukin-1 β is a part of cytokines family that is released by stimulated macrophages as a pro-protein and it is considered as a critical mediator of the inflammatory process [25]. This study further showed that Con A had the ability to stimulate IL- 1 β , while the combination group showed that vorinostat has anti-inflammatory ability to inhibit IL- 1 β and protect hepatocyte from fibrosis. In addition, transforming growth factor beta (TGF- β) stimulates transcription of diverse target genes that have an important role in differentiation, proliferation, and motivation of several immune cells [26]. Con A also successfully stimulated myofibroblast through stimulation of TGF- β , while vorinostat in the combination group reduced the level of TGF- β . It has been reported in different studies that IV of Con A (15– 20 mg/kg) once weekly for 4 weeks, led to a noticeable rise in serum ALT, AST, IFN- γ and hepatic TGF- β levels [19,21,27,28]. This also conforms with our findings.

Histopathological studies on the groups administered Con A for 4 weeks revealed numerous hepatocytes in the vicinity of the central vein with deep eosinophilic cytoplasm, hyperchromatic condensed pyknotic nuclei, fragmented nuclei and vacuolated cytoplasm. Polymorphonuclear cell infiltration was noticed in the periportal area. After 8 weeks there were ruptured wall of the central vein with localized areas of hemorrhage, disorganized pattern of

hepatocytes and disturbed normal architecture, where hepatocytes are shrunk with deeply acidophilic cytoplasm and pyknotic nuclei. These histological findings were also confirmed by another study done by Mohamed [21]. Treatment with VOR markedly ameliorated the pathological effect of Con A on the structure of the liver and regained most of the normal structural features. Only localized areas of apoptotic cells were noted in the field (M-P) (Fig. 7) (H&E x400).

Current statistics have also revealed that the liver during AIH, selectively recruits and stimulates the apoptosis, which programmed cell death by activation of CD8+ T cells after immune stimuli [29]. Morphometric measurements using quantitative parameters to measure the cytoplasmic and nuclear area of hepatocytes in all different groups have shown that the increase in the mean of the cytoplasm area in Con A sections compared to other groups at 4 weeks, confirmed the vacuolation of the cytoplasm of hepatocytes at early stages of affection. At 8 weeks in Con A group, apoptosis was marked, resulting in a decrease in the area of the nucleus (Pyknotic nucleus) and cytoplasm (shrunk cells). Vorinostat in the combination group reduced the apoptotic stimulation that was produced by Con A. Histopathological studies done by Mohamed D.I. showed the morphological appearance of apoptotic cells following the treatment with Con A [21]. This induction of Con A to apoptosis was similar to the process that happened during AIH [29].

Sections stained with Masson's trichrome showed an apparent increase of collagen deposition around the CV and PT in the groups administered Con A for 4 weeks which is further enhanced after 8 weeks (E-H). Simultaneous administration of vorinostat ameliorated collagen deposition after 4 and 8 weeks (I-L) (Fig. 8). Moreover, the area percentage of collagen fibers stained with Masson trichrome in sections of the liver showed an increase in the percentage area of cells that were stained by Masson's trichrome after treatment with Con A and a reduction of the stained area in the combination group. Histological staining to confirm the deposition of collagen has been done by Hussein RM and it revealed deposition of collagen after administration of Con A which was confirmed by the results of this study [30].

Immunostained liver sections in the group administered with Con A for 4 weeks revealed an apparent up regulated expression of alpha-SMA

around the CV and PT, which was more intensified after 8 weeks. Treatment with VOR down regulated the alpha-SMA reaction induced by Con A. The Area percentage of Alpha-smooth muscle actin (α -SMA) immune stained cells also confirmed the increase in the stained area with α -SMA after treatment with Con A and reduction of that area in combination group. These immunostained and quantification results together confirmed the liver inflammatory effect of Con A by stimulation of α -SMA, which is a marker of myofibroblast formation and also confirmed the liver anti-inflammatory effect of vorinostat by the reduction of α -SMA in combination area. Immunostaining studies done by Mohamed D.I. showed increase in the area stained with Con A treated group which confirmed the results of this study [21]. Reasons why vorinostat has the ability to restore the morphology of liver cells following the treatment with Concanavalin might be as results of reduction of liver enzymes, reducing of the production of collagen in the extracellular matrix, moreover to the inhibiting of the inflammatory mediators IL-1 β , TNF α and inhibiting myofibroblast stimulator TGF- β .

5. CONCLUSION

Con A successfully induced liver fibrosis. While oral administration of vorinostat (15 mg/kg) showed a significant reduction in serum liver enzymes (ALT and AST) at the end of both the 4th and 8th weeks when compared to Con A. Excess production of extracellular matrix (ECM) components, especially collagen is a feature of liver fibrosis and the ability of vorinostat to reduce Hydroxyproline content could suggest that vorinostat efficiently reduces the inflammation of liver tissues and alleviates liver injury.

CONSENT

It is not applicable.

ETHICAL APPROVAL

It is not applicable.

ACKNOWLEDGEMENT

Special thanks to the King Abdulaziz City for Science and Technology (KACST) for funding this research work.

COMPETING INTERESTS

Authors have declared that no competing interests exist.

REFERENCES

1. Bataller R, et al. Liver fibrogenesis: a new role for the renin-angiotensin system. *Antioxid Redox Signal*. 2005;7(9-10):1346-1355.
2. Fallatah HI, et al. Autoimmune hepatitis: Single-center experience of clinical presentation, response to treatment and prognosis in Saudi Arabia. *Saudi J Gastroenterol*. 2010;16(2):95-99.
3. Dooley S, Ten Dijke P. TGF-beta in progression of liver disease. *Cell Tissue Res*. 2012;347(1): 245-256.
4. Grabiec AM, et al. Function of histone deacetylase inhibitors in inflammation. *Crit Rev Immunol*. 2011;31(3):233-263.
5. West AC, Johnstone RW. New and emerging HDAC inhibitors for cancer treatment. *J Clin Invest*. 2014;124(1):30-39.
6. Duvic M, et al. Phase 2 trial of oral vorinostat (suberoylanilide hydroxamic acid, SAHA) for refractory cutaneous T-cell lymphoma (CTCL). *Blood*. 2007;109(1):31-39.
7. Dwyer JM, Johnson C. The use of Concanavalin A to study the immunoregulation of human T cells. *Clin Exp Immunol*. 1981;46(2):237-249.
8. Heymann F, et al. The Concanavalin A model of acute hepatitis in mice. *Lab Anim*. 2015;49(1 Suppl):12-20.
9. Kamiyoshi A, et al. Endogenous alpha-calcitonin gene-related peptide mitigates liver fibrosis in chronic hepatitis induced by repeated administration of Concanavalin A. *Liver Int*. 2009;29(5):642-649.
10. Zhao Y, et al. Protective effect of suberoylanilide hydroxamic acid against lipopolysaccharide-induced liver damage in rodents. *J Surg Res*. 2005;194(2):544-550.
11. Wu J, et al. Laennec protects murine from Concanavalin A-induced liver injury through inhibition of inflammatory reactions and hepatocyte apoptosis. *Biol Pharm Bull*. 2008;31(11):2040-2044.
12. Rao SS, et al. Suberoylanilide hydroxamic acid attenuates paraquat-induced pulmonary fibrosis by preventing Smad7 from deacetylation in rats. *J Thorac Dis*. 2016;8(9):2485-2494.

13. Nakano T, et al. Immunological aspects and therapeutic significance of an autoantibody against histone H1 in a rat model of Concanavalin A-induced hepatitis. *Immunology*. 2010;129(4):547-555.
14. Woessner JF, Jr. The determination of hydroxyproline in tissue and protein samples containing small proportions of this imino acid. *Arch Biochem Biophys*. 1961;93:440-447.
15. Drury RA. Carlton's Histological Techniques. 6th London, Oxford University press London. 1983;139:303.
16. Yu E, et al. Expression of alpha-smooth muscle actin in liver diseases. *J Korean Med Sci*. 1993;5:367-373.
17. Pang M, Zhuang S. Histone deacetylase: A potential therapeutic target for fibrotic disorders. *J Pharmacol Exp Ther*. 2010; 335(2):266-272.
18. Hatano M, et al. Effects of Kupffer cell-depletion on Concanavalin A-induced hepatitis. *Cell Immunol*. 2008;251(1):25-30.
19. Erhardt A, et al. IL-10, regulatory T cells and Kupffer cells mediate tolerance in Concanavalin A-induced liver injury in mice. *Hepatology*. 2007;45(2): 475-485.
20. Shirin H, et al. Inhibition of immune-mediated Concanavalin A-induced liver damage by free-radical scavengers. *Dig Dis Sci*. 2010;55(2):268-275.
21. Mohamed DI, et al. Fenofibrate A peroxisome proliferator activated receptor-alpha agonist treatment ameliorates Concanavalin A-induced hepatitis in rats. *Eur J Pharmacol*. 2013;721 (1-3):35-42.
22. Lv K, et al. Galectin-9 ameliorates Con A-induced hepatitis by inducing CD4(+)CD25(low/int) effector T-Cell apoptosis and increasing regulatory T cell number. *PLoS One*. 2012;7(10): e48379.
23. Xu W, et al. Effects of RNA interference targeting transforming growth factor-beta 1 on immune hepatic fibrosis induced by Concanavalin A in mice. *Hepatobiliary Pancreat Dis Int*. 2009;8(3): 300-308.
24. Locksley RM, et al. The TNF and TNF receptor superfamilies: Integrating mammalian biology. *Cell*. 2001;104(4):487-501.
25. Auron PE, et al. Nucleotide sequence of human monocyte interleukin 1 precursor cDNA. *Proc Natl Acad Sci U S A*. 1984;81(24):7907-7911.
26. Massague J. TGF-beta signaling in context. *Nat Rev Mol Cell Biol*. 2012;13(10):616-630.
27. Tanabe J, et al. Interferon-beta reduces the mouse liver fibrosis induced by repeated administration of Concanavalin A via the direct and indirect effects. *Immunology*. 2007;122(4): 562-570.
28. Chen L, et al. Kupffer cells contribute to Concanavalin A-induced hepatic injury through a Th1 but not Th17 type response-dependent pathway in mice. *Hepatobiliary Pancreat Dis Int*. 2011; 10(2):171-178.
29. Lapierre P, et al. Pathogenesis of autoimmune hepatitis: from the break of tolerance to immune-mediated hepatocyte apoptosis. *Transl Res*. 2007;149(3):107-113.
30. Hussein RM, et al. Theophylline, an old drug with multi-faceted effects: Its potential benefits in immunological liver injury in rats. *Life Sci*. 2015;136:100-107.

© 2019 Alhaddad et al.; This is an Open Access article distributed under the terms of the Creative Commons Attribution License (<http://creativecommons.org/licenses/by/4.0>), which permits unrestricted use, distribution, and reproduction in any medium, provided the original work is properly cited.

Peer-review history:

The peer review history for this paper can be accessed here:
<https://sdiarticle4.com/review-history/50926>