



# A Systematic Review on Management of Condylar Fracture

B. Niranjana <sup>a++\*</sup>, Aishwarya Kumar <sup>a++</sup>, Prarthana Basu <sup>a++</sup>,  
Ashish Sharma <sup>a#</sup>, Himanshu Bhutani <sup>a†</sup>  
and Sugandha Kaushik <sup>a++</sup>

<sup>a</sup> Oral and Maxillofacial Surgery, ITS Dental College, Greater Noida, India.

## **Authors' contributions**

*This work was carried out in collaboration among all authors. All authors read and approved the final manuscript.*

## **Article Information**

### **Open Peer Review History:**

This journal follows the Advanced Open Peer Review policy. Identity of the Reviewers, Editor(s) and additional Reviewers, peer review comments, different versions of the manuscript, comments of the editors, etc are available here: <https://www.sdiarticle5.com/review-history/97219>

**Systematic Review Article**

**Received: 04/01/2023**  
**Accepted: 10/03/2023**  
**Published: 21/03/2023**

## **ABSTRACT**

**Aim:** The mandibular condyle or sub condylar region is one of the most frequent site of mandibular fracture encountered, occurring between 25% and 35% of all mandibular fractures. Condyle fracture accounts for approximately 30% and 37% of fracture in dentulous mandible patients and edentulous mandible patients, respectively. Surgeons often debate on which type of plate has a better potency over the other for the fixation of condylar fracture. We have tried to resolve this by conducting a systematic review by comparing the reduction outcomes of using 2 mini plates and 1 trapezoidal plate for condylar fractures.

**Materials and Methods:** An elaborate data base was done to collect articles pertaining to Fixation of condylar fracture using trapezoidal or mini plate. The study selection was restricted to articles published in English and from the year 1984 to 2021. The review was done in accordance with Preferred Reporting Items for Systematic Reviews and Meta-Analysis (PRISMA) statement guidelines after detailed PICO analysis.

**Results:** The initial search returned 300 studies reported from January 1984 through June 2021. Abstract and full-text reports were acquired for 20 studies. After reviewing the full-text reports on

<sup>++</sup> Post Graduate;

<sup>#</sup> Professor & Head of Department;

<sup>†</sup> Professor;

<sup>\*</sup>Corresponding author: Email: [niranjanaabaskaran2201@gmail.com](mailto:niranjanaabaskaran2201@gmail.com);

the basis of inclusion/ exclusion criteria, Amster 2 scale, Pedro Scale and Robis only 2 studies were deemed eligible for the present review. The total sample size was 70 patients including 56 males and 14 females with mandibular sub condylar fractures and other concomitant fractures. The patients were classified in two groups according to the fixation method. The 2 fixation methods used are mini plates (group A) or a trapezoidal plate (group B).

**Conclusion:** The results of the systematic review concluded that that both the plates perform equally in the grounds of fracture reduction, functionally stable fixation, and postoperative infection and condylar movements. But trapezoidal plates are superior in terms of stability, hardware failure and time taken for fixation.

*Keywords: Condylar fracture; mini plates; trapezoidal plate; comparison.*

## 1. INTRODUCTION

The mandibular condyle or sub condylar region is one of the most frequent site of mandibular fracture encountered, occurring between 25% and 35% of all mandibular fractures. Condyle fracture accounts for approximately 30% and 37% of fracture in dentulous mandible patients and edentulous mandible patients, respectively [1]. There are various treatment options available for fixation of condylar fractures. Open reduction has now become a popular choice as it provides more accurate anatomic reduction, lesser time on inter maxillary fixation which improves patient compliance and therefore more successful outcomes [2-6]. The choice of plate helps in reduction and fixation of the fracture. Various fixation plates are available, the most commonly used plates for fixation of condylar fractures are trapezoidal, delta, strut and mini plate [7-13].

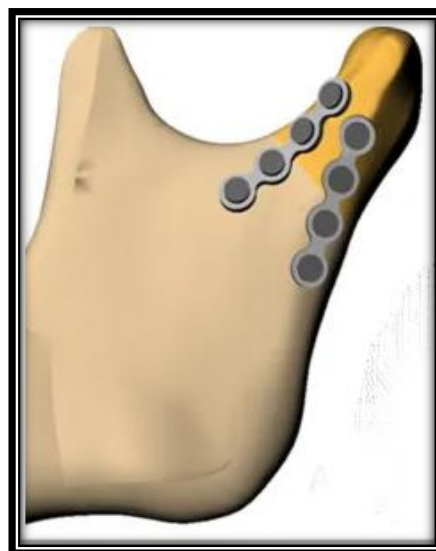

**Picture 1. Trapezoidal plate**

Sub condylar fracture can be reduced by using a single or double mini plate. Double mini plates provide better 3 dimensional stability to the fracture as compared to single mini plate when screwed along the Champy's line of osteosynthesis.

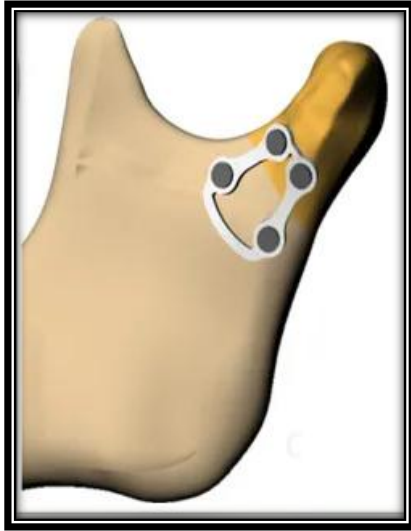

**Picture 2. 2 mini plate**



**Picture 3. 2 non parallel mini plate for Condylar fracture reduction and fixation**

Trapezoidal plate is a 3 – D plate used in the anatomically constricted region of condylar neck. One arm of the plate is placed parallel to condylar axis and to the mandibular notch. Therefore it simulates how two mini plates function in the treatment of condylar fracture [14].



**Picture 4. Trapezoidal plate for condylar fracture reduction and fixation**

Sheng Yao et al in his study quotes that the major components that standardizes healing of condylar fracture are : (1) mouth opening greater than 40 mm, (2) had no pain, (3) mandible had good activity in all directions, (4) patients who had recovered their occlusal relationship before injury, (5) temporomandibular joint stability, and (6) symmetric facial appearance [15]. In this systematic review a comparison between trapezoidal and mini plates is being done to evaluate which plate is better for the treatment of condylar fractures. These two plates were chosen for this study as they are the most commonly used plates for the fixation of mandibular fractures.

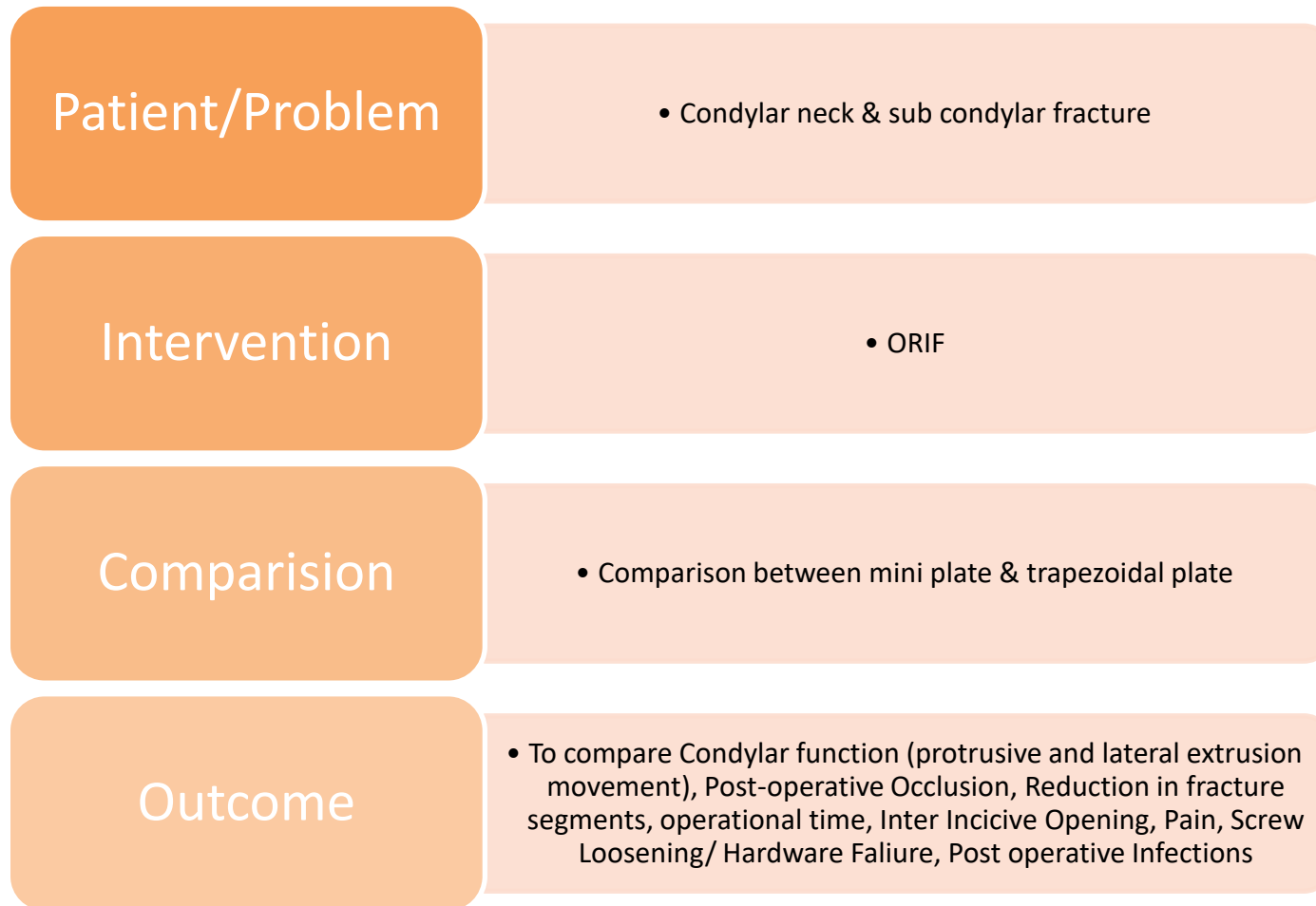
## 2. METHODOLOGY

An elaborate data base search using search engines like google scholar, Pub med, Ebsco Host, Medline, Cochrane library and EMBASE was done to collect articles pertaining to Fixation of condylar fracture using trapezoidal or mini plate. The study selection was restricted to articles published in English and from the year 1984 to 2021. The review was done in accordance with Preferred Reporting Items for Systematic Reviews and Meta-Analysis

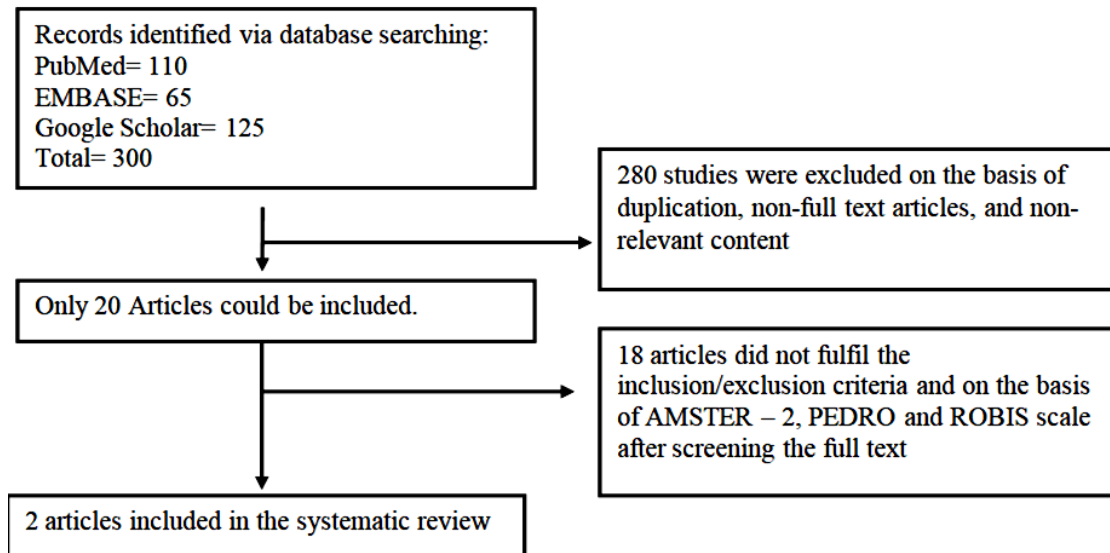
(PRISMA) statement guidelines after detailed PICO analysis. The following were the Pico components.

Boolean terms such as Internal fixation AND 'mandibular condylar fracture; One miniplate compared with two AND mandibular condylar fracture; Single miniplate compared with double miniplate AND mandibular condylar fracture; Mandibular condylar fracture AND Trapezoidal plate; Clinical and radiological outcomes AND mandibular condylar fracture and treatment outcomes AND mandibular condylar fractures; Mini plate AND condylar fracture; Mini plate AND trapezoidal plate AND condylar fracture. Initial article selection as done on the basis of preset inclusions which were Studies of humans. Adult patients with mandibular condylar fracture treated with open reduction and internal fixation. Fixation done using mini plate or trapezoidal plate. And exclusion criteria were set as Literature reviews, brief case reports, abstract-only reports, and reports written in a language other than English, Studies performed using animal mandibles, Lab studies done on polyurethane or other models, Studies that had evaluated degradable fixation systems, Studies that had used no titanium plates and screws, Studies in which fixation of the fracture was completed with wires or screws alone were excluded, Communicated fractures, Patient requiring bone graft, Syndromic patients with condylar fracture, Edentulous patients with condylar fracture [16-23]. After the initial selection, careful reviewing of the full text was done to extract information on the following criteria

1. Condylar function – It was evaluated by the operator by observing protrusive and lateral extrusion movement of the mandible.
2. Post-operative Occlusion - Checked by maximum intercuspation of teeth between both the arches
3. Reduction in fracture segments – Evaluation was done on regular follow ups 1 month postoperatively by radiographs
4. Hardware failure or screw loosening - Was checked on regular follow ups 1 month postoperatively by radiographs
5. Operation time was measured by time taken to reduce and fix fracture with plates.
6. Maximum interincisal opening was measured using a ruler postoperatively.
7. Pain was measured by using a visual analogue scale on a range of 1 – 100.



**Fig. 1. Study protocol**



**Fig. 2. Study principles and database searching**

The quality, strength and risk of bias of various study was evaluated by using AMSTAR – 2, after which data collection was done in tabular form using Microsoft Excel for further interpretation

### 3. RESULTS

The initial search returned 300 studies reported from January 1984 through June 2021. Abstract and full-text reports were acquired for 20 studies. After reviewing the full-text reports on the basis of inclusion/ exclusion criteria, Amster 2 scale, only 2 studies were deemed eligible for the present review. Primary data was extracted from 2 included studies. The total sample size was 70 patients including 56 males and 14 females with mandibular sub condylar fractures and other concomitant fractures. The most prevalent etiology was RTA (70%) followed by fall, assault and sport injury. The patients were classified in two groups according to the fixation method. The 2 fixation methods used are mini plates (group A) or a trapezoidal plate (group B).

#### 1. Operation time

The operational time was significantly shorter for fixation using trapezoidal plate than 2 mini plates. The mean time taken for fracture reduction and fixation for trapezoidal plate was 6 mins (3- 26 mins) whereas for mini plate fixation the time taken was 15 mins (6 – 60 mins) (Graph 1).

#### 2. Reduction in fracture

The anatomic reduction the fracture segments did not yield much difference in both the groups.

This was evaluated by using radiographs by the operator. Both the plates provided adequate reduction for the fracture segments.

#### 3. Occlusion

The occlusion was checked by maximal intercuspation of teeth .In both the groups as reported by the authors no patient reported back with the complaint of occlusal derangement or instability which warranted a second surgery. However mild occlusal disharmonies were managed by grinding.

#### 4. Condylar movements

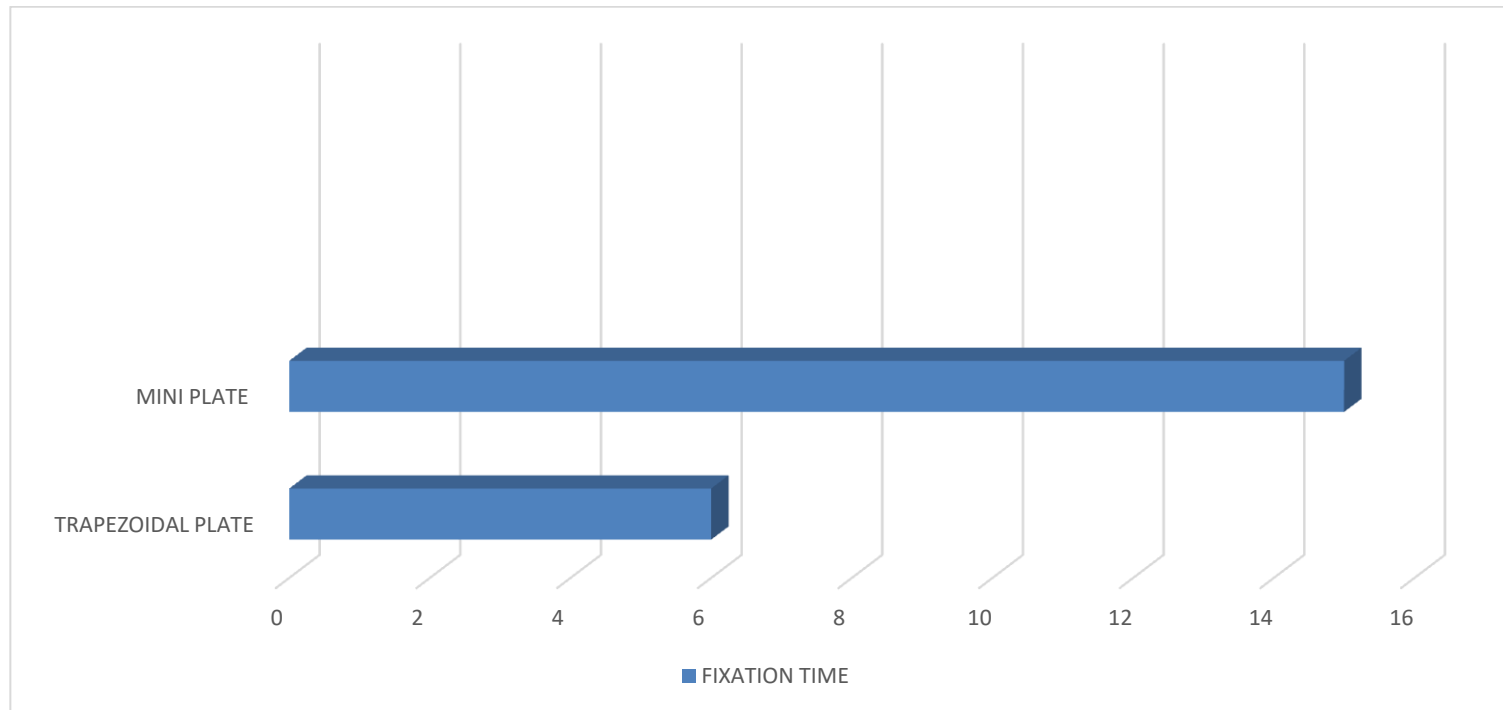
There was decreased immediate postoperative condylar movement mostly protrusive and lateral excursion movements which subsequently improved in the post-operative follow up.

#### 5. Inter incisal opening

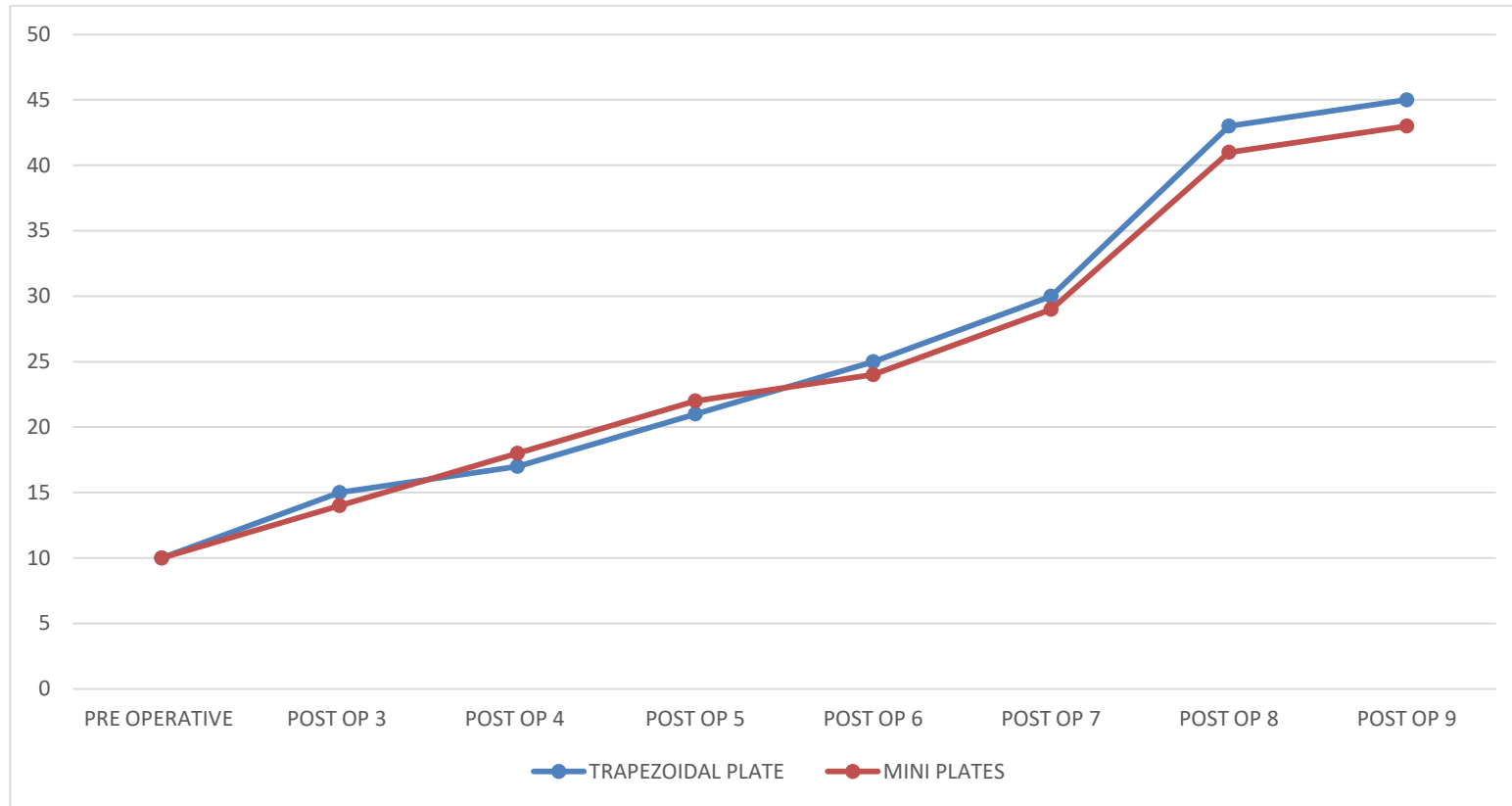
The immediate postoperative mean inter incisal distance was noted to be 15 mm (10 – 20 mm). Interincisal opening was not significantly different in both the groups (Graph 2).

#### 6. Pain

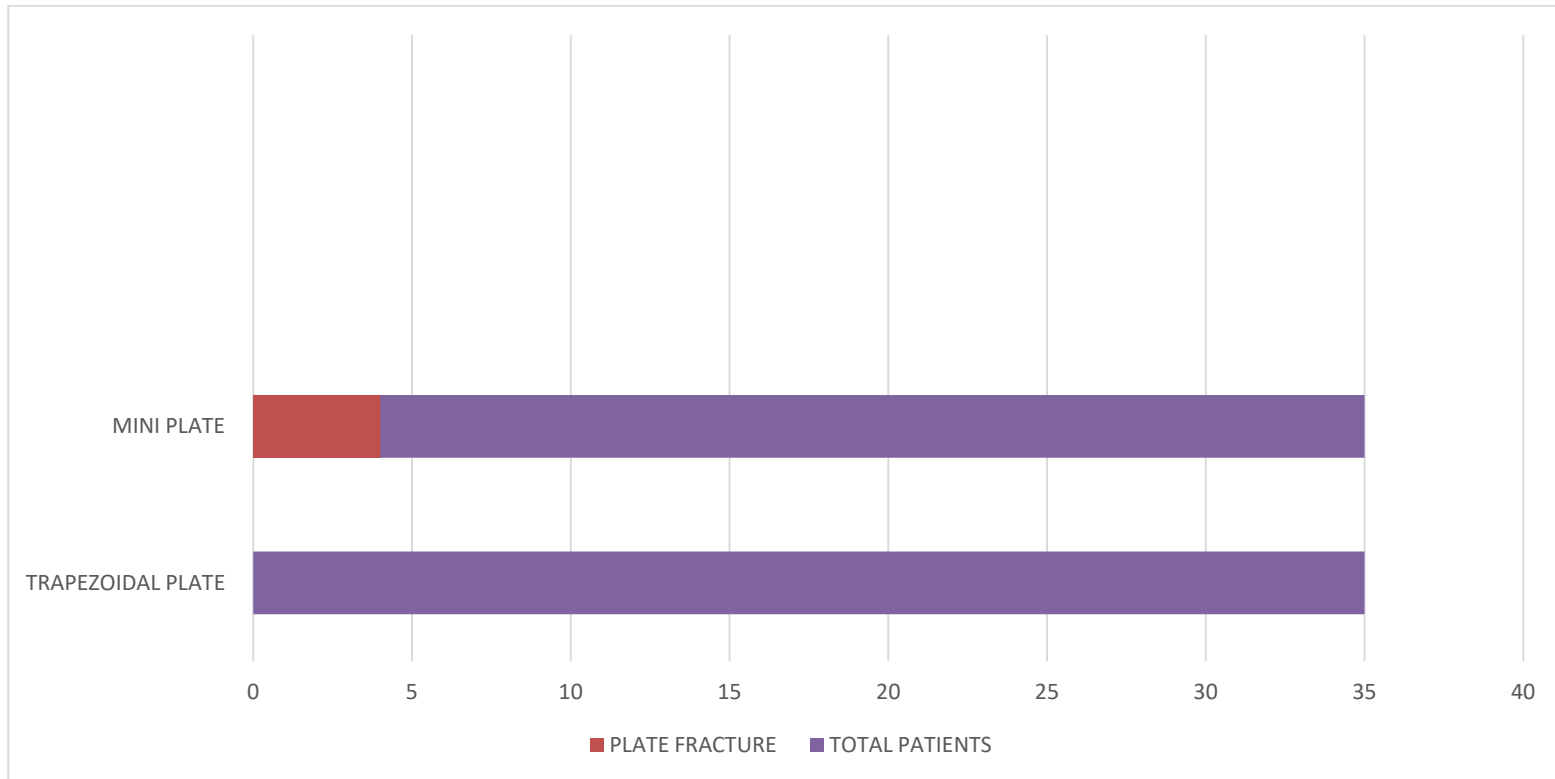
Pain was observed in patients immediately after surgery and also in cases of plate fracture. The pain could also be due to the surgery. A mean value of 33.33 was observed in both the cases which subsided eventually in further recalls.



**Graph 1. Mean fixation time in minutes**



**Graph 2. Maximum mouth opening**



**Graph 3. Hardware failure**



#### 7. Screw loosening / hardware failure

Was not a common observation, however the authors report fracture of plate in Group A more commonly. Only in 4 patients out of 70, mini plate fracture was observed and trapezoidal plates did not show any plate fractures. Post-operative pain and infections were also associated with the patients who had plate fracture (Graph 3).

#### 8. Post-operative infection.

Most patients did not develop post-operative infection but infection due to plate fracture was seen in 1 patient.

In accordance with the above stated results, it is determined that trapezoidal plates provides better stability and has less intra operational time as compared with mini plates. Thus trapezoidal plates are a better choice for condylar fracture fixation.

### 4. DISCUSSION

Even though condylar fractures are the most common type of mandibular fractures, their treatment protocol still remains a controversy. When an informed choice of ORIF has been made according to Zide and Kents absolute and relative indications, the surgeon has a variety of plating options to choose from for his fixation. This systematic review hence chose 2 most commonly used plates i.e trapezoidal plate and mini plate for fixation of condylar fracture and compare which of these yields better outcomes. A null hypothesis was made that there will be no significant difference between performances of the two plates. The aim of this study was to compare the plates on the basis of operational time reduction of fracture segments, condylar movements, pain, screw loosening, and post-operative infection. Our systematic review concluded that trapezoidal plate provides better stability at the fracture site and has significantly less operational time.

For a surgeon, time spent on the treatment of the problem is never an issue so as to give the best treatment to the patient. But anything that reduces time and effort is much desired by anyone. On this aspect the time taken to manipulate and fix trapezoidal plate at the fracture site was significantly more as compared to 2 mini plates. Recently Transmassetric anterior parotid approach has shown to have less facial nerve injuries, fistulas and post-operative

infections. The availability of a clear field is what bring adequate reduction and fixation of the segments but it is difficult to fix mini plate at the proximal segment of condyle [1]. The transmassetric Anterior parotid approach helps in fixing that issue as well. Moreover, more the number of plates and screws, more is the time taken for fixation. Trapezoidal plate gives 3 dimensional stability to the fracture site, it is easy to manipulate and fix. The mean time for fixation for trapezoidal plate was around 6 mins but for 2 mini plates it turned out to be 15 mins. Therefore, trapezoidal plate saves time and soft tissue retraction is for lesser time there by decreasing the chances of post-operative complications such as edema and facial nerve paralysis.

Fracture reduction helps in anatomic as well as functional restoration for the patient. Adequate reduction and fixation is required to bring correct occlusion to the patient. In both the groups there was no significant difference in reduction of fracture which was assessed via radiograph post operatively. Post-operative occlusion is of the most important aspect for management of sub condylar fracture. This was checked by maximum intercuspation on occlusion. Literature suggests that obtaining a satisfactory post-operative occlusion ranges from 72 to 100 percent, and our results were in accordance with them regardless of the type of plate used in fracture reduction.

The range of mandibular movements are determined by bilateral synchronized movements of the condyle. In all the 70 patients who underwent ORIF for treatment of condylar fracture showed adequate lateral excursion, protrusive movement. Irrespective of the plate type a mean value of 15 mm of maximum mouth opening was observed using a ruler post operatively. The mouth opening significantly increased in further follow-ups.

As reported by the authors hardware failure due to plate fracture was seen in 4 cases in group A (5.71%). The tensile strains lines are mainly responsible for the complications concerning plate fracture or screw loosening that lead to the displacement of the reduced condylar fragment with the consequent presence of a gap in the fracture line [24-27]. The first plate, fixed by four screws (two on each side of the fracture), is positioned parallel to the condylar neck axis, respecting the compressive strain lines in this region. This first plate helps to obtain "intermediary stability", so permitting the

restoration of the height of the ramus. But this same plate is not capable of resisting the biomechanical strains that occur in the condylar region during mastication, and more precisely the sagittal tension correlated to the tensile strain lines that lead to the displacement of the condylar fragment with the consequent appearance of the gap [28-31]. Therefore it is necessary to position a second plate in an oblique direction along the tensile strain lines that run below and parallel to the sigmoid notch, in agreement with Champy's concept of stable osteosynthesis functionality. The second plate protects the first plate from damaging mechanical strains that could cause its fracture and a secondary displacement of the mandibular condylar fragment reduced [1]. Meyer's et al. in the year 2006 suggested through his experimental study that 2 non parallel mini plates cannot bare the physiologic strain the sub condylar region leading to hardware failure [32]. Hence, the concept of trapezoidal plate was hatched, due to the shape of the plate which has been made keeping in mind the stress, strain and bone deformation occurring at the condylar region [32] it is easier to manipulate the plate and fix it in the line of osteosynthesis regardless of high or low condylar fracture. Therefore, plate fracture was not reported in group B, emphasizing the superior stability of trapezoidal plate.

Post-operative infections were not a very common finding in any of the cases. However 1 case out of 70 patients showed infection (1.42%) in the surgical site. The infection was treated with incision and drainage. This can be avoided with aseptic environment during surgery and regular change of dressing. This promotes better and faster healing as well. Post-operative pain was usually associated with the surgical site and was maximum during the 1<sup>st</sup> week. The pain subsided eventually during further visits. The stability of the fractured segments is inversely proportional to pain. Though there was no significant difference, but the stability provided by trapezoidal plate is better as compared to a mini plate. Therefore pain is also less in group B.

## 5. CONCLUSION

In conclusion we can suggest that both the plates perform equally in the grounds of fracture reduction, functionally stable fixation, and postoperative infection and condylar movements. But trapezoidal plates are superior in terms of stability, hardware failure and time taken for

fixation. These factors are very important for successful outcome of a fracture reduction. Therefore trapezoidal plate should be preferred over 2 mini plates for the reduction of condylar segments.

## CONSENT

It is not applicable.

## ETHICAL APPROVAL

It is not applicable.

## COMPETING INTERESTS

Authors have declared that no competing interests exist.

## REFERENCES

1. Narayanan V, Ramadorai A, Ravi P, Nirvikalpa N. Transmasseteric anterior parotid approach for condylar fractures: experience of 129 cases. *British Journal of Oral and Maxillofacial Surgery*. 2012;50(5):420-4.
2. Chaudhary M, Pant H, Singh M, Vashistha A, Kaur G. Evaluation of trapezoidal-shaped 3-D plates for internal fixation of mandibular subcondylar fractures in adults. *Journal of Oral Biology and Craniofacial Research*. 2015;5(3):134-9.
3. Choi KY, Yang JD, Chung HY, Cho BC. Current concepts in the mandibular condyle fracture management part II: open reduction versus closed reduction. *Archives of Plastic Surgery*. 2012;39(4):301.
4. Silvennoinen U, Iizuka T, Lindqvist C, Oikarinen K. Different patterns of condylar fractures: an analysis of 382 patients in a 3-year period. *Journal of Oral and Maxillofacial Surgery*. 1992;50(10):1032-7.
5. Gerbino G, Boffano P, Tosco P, Berrone S. Long-term clinical and radiological outcomes for the surgical treatment of mandibular condylar fractures. *Journal of oral and maxillofacial surgery*. 2009;67(5):1009-14.
6. Zhou HH, Liu Q, Cheng G, Li ZB. Aetiology, pattern and treatment of mandibular condylar fractures in 549 patients: A 22-year retrospective study. *Journal of Cranio-Maxillofacial Surgery*. 2013;41(1):34-41.

7. Zachariades N, Mezitis M, Mourouzis C, Papadakis D, Spanou A. Fractures of the mandibular condyle: A review of 466 cases. Literature review, reflections on treatment and proposals. *Journal of Cranio-Maxillofacial Surgery*. 2006;34(7): 421-32.
8. Choi BH, Yi CK, Yoo JH. Clinical evaluation of 3 types of plate osteosynthesis for fixation of condylar neck fractures. *Journal of Oral and Maxillofacial Surgery*. 2001;59(7):734-7.
9. Ellis III E, Throckmorton GS. Treatment of mandibular condylar process fractures: biological considerations. *Journal of Oral and Maxillofacial Surgery*. 2005;63(1): 115-34.
10. Tominaga K, Habu M, Khanal A, Mimori Y, Yoshioka I, Fukuda J. Biomechanical evaluation of different types of rigid internal fixation techniques for subcondylar fractures. *Journal of Oral and Maxillofacial Surgery*. 2006;64(10):1510-6.
11. Goyal M, Marya K, Chawla S, Pandey R. Mandibular osteosynthesis: A comparative evaluation of two different fixation systems using 2.0 mm titanium miniplates & 3-D locking plates. *Journal of Maxillofacial and Oral Surgery*. 2011;10(4):316-20.
12. Parascandolo S, Spinzia A, Parascandolo S, Piombino P, Califano L. Two load sharing plates fixation in mandibular condylar fractures: biomechanical basis. *Journal of Cranio-Maxillofacial Surgery*. 2010;38(5):385-90.
13. Koshy JC, Feldman EM, Chike-Obi CJ, Bullocks JM. Pearls of mandibular trauma management. In *Seminars in Plastic Surgery*. 2010;24(04):357-374. © Thieme Medical Publishers.
14. Valiati R, Ibrahim D, Abreu ME, Heitz C, de Oliveira RB, Pagnoncelli RM, Silva DN. The treatment of condylar fractures: to open or not to open? A critical review of this controversy. *International Journal of Medical Sciences*. 2008;5(6):313.
15. Yao S, Zhou J, Li Z. Contrast analysis of open reduction and internal fixation and non-surgical treatment of condylar fracture: A meta-analysis. *Journal of Craniofacial Surgery*. 2014;25(6):2077-80.
16. Choi KY, Yang JD, Chung HY, Cho BC. Current concepts in the mandibular condyle fracture management part I: Overview of condylar fracture. *Archives of Plastic Surgery*. 2012;39(4):291.
17. Zrounba H, Lutz JC, Zink S, Wilk A. Epidemiology and treatment outcome of surgically treated mandibular condyle fractures. A five years retrospective study. *Journal of Cranio-Maxillofacial Surgery*. 2014;42(6):879-84.
18. Dalla Torre D, Burtscher D, Widmann G, Pichler A, Rasse M, Puelacher W. Surgical treatment of mandibular condyle fractures using the retromandibular anterior transparotid approach and a triangular-positioned double miniplate osteosynthesis technique: A clinical and radiological evaluation of 124 fractures. *Journal of Cranio-maxillofacial Surgery*. 2015;43(6): 944-9.
19. Chaudhary M, Pant H, Singh M, Vashistha A, Kaur G. Evaluation of trapezoidal-shaped 3-D plates for internal fixation of mandibular subcondylar fractures in adults. *Journal of Oral Biology and Craniofacial Research*. 2015;5(3):134-9.
20. Powers DB. Classification of mandibular condylar fractures. *Atlas Oral Maxillofac Surg Clin North Am*. 2017;25(1):1-0.
21. Darwiche MA, Albogha MH, Abdelmajeed A, Darwiche K. Assessment of the biomechanical performance of 5 plating techniques in fixation of mandibular subcondylar fracture using finite element analysis. *Journal of Oral and Maxillofacial Surgery*. 2016;74(4):794-e1.
22. Bischoff EL, Carmichael R, Reddy LV. Plating options for fixation of condylar neck and base fractures. *Atlas Oral Maxillofac Surg Clin North Am*. 2017;25(1):69-73.
23. Ahuja SA, Galinde J, Asnani U, Mistry YA. Comparative evaluation of clinical outcomes using delta plates and conventional miniplates for internal fixation of mandibular condylar fractures in adults. *Journal of Oral and Maxillofacial Surgery*. 2018;76(6):1255-66.
24. Saikia J, Kumar S, Jain H, Gupta A. Biomechanical study of trapezoidal plate, delta plate and miniplate in subcondylar fracture. *Journal of Clinical & Diagnostic Research*. 2018;12(10)
25. Menon S, Kumar V, Archana S, Nath P, Shivakottee S. A retrospective study of condylar fracture management in a Tertiary Care Hospital—A 10-year experience. *Journal of Maxillofacial and Oral Surgery*. 2020;19(3):380-6.
26. Marwan H, Sawatari Y. What is the most stable fixation technique for mandibular condyle fracture?. *Journal of Oral and*

- Maxillofacial Surgery. 2019;77(12):2522-e1.
27. El-Mahdy MA, Ezz MK, Shindy MI. Assessment of subcondylar fracture treated using two four-hole straight miniplates versus The Synthes® Matrixmandible Trapezoidal Plate: Randomized Controlled Trial. *European Journal of Molecular & Clinical Medicine*. 2020;7(9):692-708.
28. Bhowmick RS, Bhowal K, Ghosh S. Plating systems for 3D stability of subcondylar fracture: A research article with review of literature. *International Journal of Orthopaedics*. 2019;5(2):681-3.
29. Lata J, Verma N, Mahajan S. Evaluation of efficacy of 3-dimensional delta versus trapezoidal condylar plates in internal fixation of mandibular subcondylar fractures: A clinical study. *The Traumaxilla*. 2019;1(1):11-21.
30. Adhikari M, Bhatt K, Yadav R, Mandal J, Bhutia O, Roychoudhury A. Fixation of subcondylar fractures of the mandible: A randomized clinical trial comparing one trapezoidal plate with two miniplates. *International Journal of Oral and Maxillofacial Surgery*; 2020.
31. Bonanthaya K, Panneerselvam E, Manuel S, Kumar VV, Rai A, editors. *Oral and maxillofacial surgery for the clinician*. Springer Nature; 2021.
32. Meyer C, Serhir L, Boutemi P. Experimental evaluation of three osteosynthesis devices used for stabilizing condylar fractures of the mandible. *Journal of Cranio-Maxillofacial Surgery*. 2006; 34(3):173-81.

© 2023 Niranjana et al.; This is an Open Access article distributed under the terms of the Creative Commons Attribution License (<http://creativecommons.org/licenses/by/4.0>), which permits unrestricted use, distribution, and reproduction in any medium, provided the original work is properly cited.

*Peer-review history:*  
*The peer review history for this paper can be accessed here:*  
<https://www.sdiarticle5.com/review-history/97219>