



# Recurrent Right Sided Endocarditis and Right Heart Failure in a Child with Ventricular Septal Defect

Uma Devi Karuru <sup>a++\*</sup>, Naveen T <sup>a</sup>, Ashirbad Parhi <sup>a</sup>, Sai Kumar Mysore <sup>a</sup> and Sadanand Reddy Tummala <sup>a</sup>

<sup>a</sup> Department of Cardiology, ESIC Medical College and Super Speciality Hospital, Hyderabad, India.

## **Authors' contributions**

*This work was carried out in collaboration among all authors. All authors read and approved the final manuscript.*

## **Article Information**

DOI: <https://doi.org/10.9734/ajcr/2025/v8i1246>

## **Open Peer Review History:**

This journal follows the Advanced Open Peer Review policy. Identity of the Reviewers, Editor(s) and additional Reviewers, peer review comments, different versions of the manuscript, comments of the editors, etc are available here: <https://www.sdiarticle5.com/review-history/129494>

## **Case Report**

**Received: 11/11/2024**

**Accepted: 14/01/2025**

**Published: 17/01/2025**

## **ABSTRACT**

**Background:** Right-sided infective endocarditis (IE) is a rare but serious complication of congenital heart defects, particularly ventricular septal defects (VSDs). Tricuspid regurgitation (TR) can develop as a secondary consequence of recurrent right-sided IE, leading to significant hemodynamic disturbances. While most cases are managed successfully with antibiotics, a subclinical, massive, and torrential TR resulting in recurrent right heart failure (RHF) remains uncommon, particularly in the paediatric population. This case report aims to highlight the clinical challenges and management strategies in such a scenario.

**Case Presentation:** We present the case of a 10-year-old child with a small, previously unrecognized peri membranous VSD who developed recurrent right-sided IE. Over several months, the patient exhibited signs of right heart failure, including hepatomegaly, edema, and poor weight

<sup>++</sup> Assistant Professor;

\*Corresponding author: Email: [drumadevikaruru@gmail.com](mailto:drumadevikaruru@gmail.com);

gain. Echocardiographic evaluation revealed significant tricuspid regurgitation secondary to extensive damage to the septal tricuspid leaflet secondary to previous vegetations consistent with infective endocarditis. Despite several courses of antibiotics, the patient continued to experience episodes of right heart failure, with progressive worsening of TR and volume overload. Surgical intervention was considered due to the failure of medical management, the persistence of heart failure.

**Conclusions:** This case underscores the rare but serious occurrence of recurrent right heart failure due to torrential TR in a child with a VSD complicated by infective endocarditis. While early antibiotic therapy is essential, surgical intervention may be required in cases of refractory heart failure, significant valve damage, or risk of embolic complications. Tricuspid valve repair requires a thorough approach to debridement and tissue preservation, with a focus on minimizing the use of prosthetic materials. The prognosis remains guarded in such cases, emphasizing the importance of early recognition and timely intervention to prevent further morbidity and mortality.

**Keywords:** *Ventricular septal defect; right heart failure; right sided endocarditis; tricuspid regurgitation; recurrent endocarditis.*

## ABBREVIATIONS

VSD : *Ventricular Septal Defect*  
TR : *Tricuspid Regurgitation*  
IE : *Infective Endocarditis*  
NYHA : *New York Heart association*  
ECG : *Electrocardiography*  
RA : *Right Atrium*  
RV : *Right Ventricle*  
2D ECHO: *2-Dimensional Echocardiography*  
PAH : *Pulmonary Artery Hypertension*  
IVC : *Inferior Vena Cava*

## 1. INTRODUCTION

Ventricular septal defects (VSDs) are among the most common congenital heart defects. While small VSDs are often asymptomatic, larger defects or those associated with other congenital anomalies can predispose patients to a variety of complications, including infective endocarditis (IE). Right-sided IE, although less common than left-sided IE, is a recognized complication in patients with VSDs, particularly in those who have recurrent or chronic infections.

Infective endocarditis in the setting of a VSD may lead to significant valve damage, most commonly involving the tricuspid valve. The right-sided heart involvement occurs due to the high-pressure gradient between the left and right ventricles, which facilitates bacterial colonization of the tricuspid valve, especially in the presence of turbulent flow across the defect. This can result in progressive valve destruction, leading to organic tricuspid regurgitation (TR), which may exacerbate the hemodynamic burden on the right side of the heart. Although most cases of right-sided IE can be managed with antibiotics, the

development of massive, subclinical TR can lead to chronic volume overload and recurrent heart failure, posing significant challenges in paediatric management.

Recurrent IE may cause progressive tricuspid valve damage, resulting in severe, often subclinical TR and recurrent right heart failure. We present a paediatric case of significant TR secondary to recurrent right-sided IE in a child with a small VSD, leading to chronic volume overload and persistent heart failure despite antibiotic therapy. This case highlights the rare occurrence of massive TR due to recurrent right-sided IE in VSD, underscoring the need for early intervention and, in some cases, surgical repair to prevent long-term complications such as irreversible heart failure and valve dysfunction.

## 2. CASE PRESENTATION

A 10-year-old girl presented to our centre with progressively worsening dyspnoea on exertion, worsened from NYHA class II to class IV over a span of two years. Additionally, she exhibited anasarca, initially manifesting in the lower limbs and subsequently spreading throughout her body, alongside symptoms of easy fatigability, respiratory distress, and poor feeding.

### 2.1 Physical Examination

Clinical examination revealed dental caries in multiple tooth, grossly elevated jugular venous pressure with prominent CV waves, anasarca, and hepatomegaly. Auscultation identified soft S1, loud P2, and a pan-systolic murmur graded V/VI in the left parasternal area, accentuated during inspiration without radiation. Bilateral

basal crepitations were noted, in addition to firm hepatomegaly measuring 13 cm in span.

## 2.2 Past History

The patient was diagnosed with a perimembranous VSD at the age of 2 years and was advised regular medical follow-up due to anticipated spontaneous closure. However, at ages 7, 8, and 9 years, she experienced episodes of infective endocarditis with organisms *Staphylococcal aureus*, *Streptococcus sinensis* with resultant right heart failure, necessitating decongestive measures and antibiotic therapy at an outside hospital. Upon presentation to our centre at 9 years of age, she was diagnosed with a restrictive perimembranous VSD accompanied by severe TR. Despite a recommendation for surgical intervention, familial consent was lacking, leading to deferred surgery. Three months later, she presented with acute decompensated right heart failure, necessitating multiple inotropic agents, decongestive measures, and intravenous antibiotics. Subsequent evaluation revealed *Staphylococcal aureus* septicaemia without intracardiac vegetations, prompting treatment as infective endocarditis in the context of recurrent episodes of IE and decompensated heart failure. Dental evaluation revealed minor dental caries which was managed conservatively and was on dental hygiene measures.

## 2.3 Investigations

Laboratory investigations revealed anaemia, neutrophilic leucocytosis, thrombocytosis with positive C- reactive protein (Table 1). Primary and secondary immunodeficiency work-up (Immunoglobulins levels, compliment 3 & 4 levels, Nitro blue tetrazolium test, human immunodeficiency virus antigen), as well as viral markers (Hepatitis B antigen, anti-hepatitis C antibodies) were negative. Radiographic

evaluation via chest X-ray demonstrated cardiomegaly with a cardiothoracic ratio of 0.90 (Fig. 1) and signs of pulmonary venous congestion. Electrocardiography (ECG) revealed sinus rhythm, right atrial (RA), right ventricular (RV) enlargement, and P pulmonale. Two-dimensional echocardiography (2D ECHO) unveiled grossly dilated RA with RA area of 31.6cm<sup>2</sup> and RV, restrictive perimembranous VSD with a size of 4.9mm with left-to-right shunt with a pressure gradient of 77mm Hg (Figs. 2A, 2B, 2D) (Video 1), deformed tricuspid leaflets with thickened tricuspid valve leaflet tips, tricuspid annular diameter of 34mm (Fig. 2C), massive central tricuspid regurgitation (Video 2) with moderate pulmonary artery hypertension (PAH) (Right Ventricular Systolic Pressure= 46mm Hg+ Right Atrial Pressure) (Fig. 2E), moderate pericardial effusion more on the anterior side, and dilated inferior vena cava (IVC). Cardiac computerized tomography revealed similar findings (Fig. 3) with mild pulmonary venous congestion without evidence of tricuspid, pulmonary or branch pulmonary artery vegetations, consolidation or collapse.

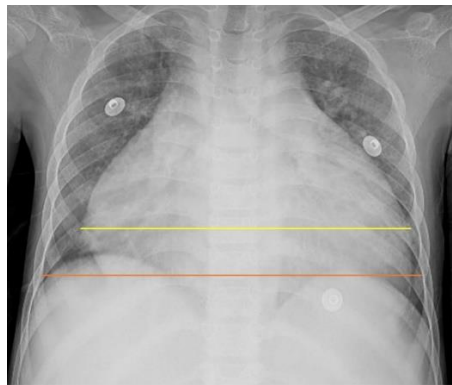## 2.4 Management

Given the high-risk nature of the case, surgical closure of the perimembranous VSD coupled with tricuspid valve repair under cardiopulmonary bypass was deemed appropriate due to marked right heart dilatation and torrential TR. VSD closure was achieved utilizing a pericardial patch secured with pledgeted interrupted sutures, alongside insertion of a 26 mm rigid tricuspid annuloplasty ring, resulting in trivial TR and closure of the VSD. However, the patient experienced complete heart block, low cardiac output syndrome within six hours post-surgery, precipitating severe RV dysfunction leading to anuric renal failure requiring peritoneal dialysis and eventual demise within 24 hours.

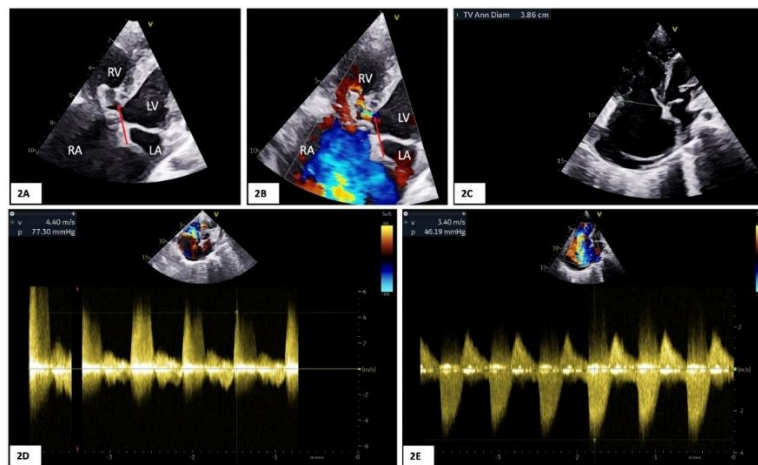
**Table 1. Baseline investigations at the time of admission**

| Investigation                   | Value                             |
|---------------------------------|-----------------------------------|
| Hemoglobin                      | 10.2g/dL                          |
| White blood cell conut          | 18,800/mm <sup>3</sup>            |
| Neutrophil/lymphocyte           | 60%/28%                           |
| Platelets                       | 5.8lakhs/mm <sup>3</sup>          |
| CRP/ESR                         | 14mg/dL/20mm 1 <sup>st</sup> hour |
| ASO                             | 200IU/mL                          |
| Urea/Creatinine                 | 16/0.4 mg/dL                      |
| Serum sodium/potassium/chloride | 142/4.2/120mmol/L                 |

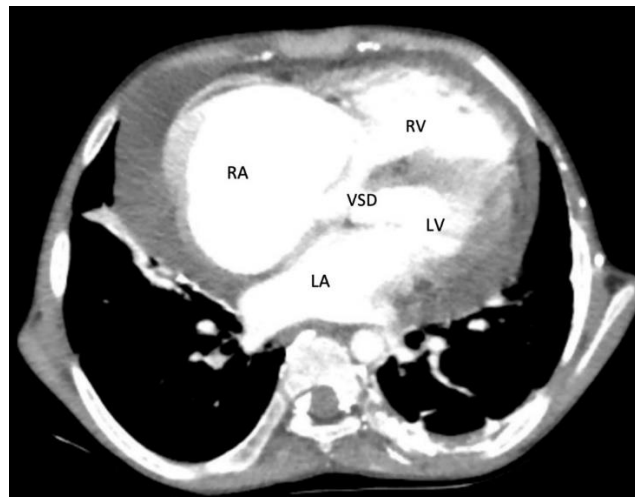
CRP: C- Reactive Protein, ESR: Erythrocyte Sedimentation Rate, ASO: Anti streptolysin O



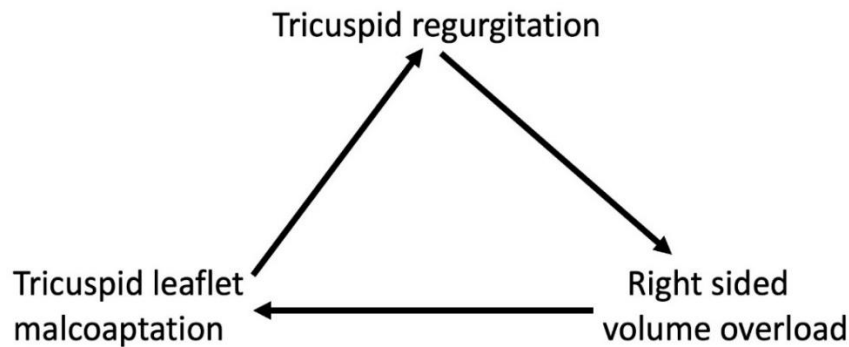
**Fig. 1. Chest X ray showing cardiothoracic ratio of 0.90, yellow line cardiac diameter 0.9cm, red line thoracic diameter of 1.0cm**



**Fig. 2. Two-dimensional echocardiography. 2A, 2B: Apical four chamber view without and with color flow image demonstrating ventricular septal defect indicated by red arrow. 2C: Apical four chamber view showing tricuspid annular diameter of 3.86cm and moderate pericardial effusion behind right atrium. 2D: Continuous wave doppler across the ventricular septal defect showing pressure gradient of 77mm Hg. 2E: Continuous wave doppler across the tricuspid regurgitation showing pressure gradient of 46mm Hg**



**Fig. 3. Cardiac Computerized tomography contrast image demonstrating ventricular septal defect in five chamber view**



**Fig. 4. Flow diagram depicting mechanism of tricuspid regurgitation**

### 3. DISCUSSION

Right-sided Infective Endocarditis (IE) is a significant complication of congenital heart defects, particularly small ventricular septal defects (VSDs). VSDs create an environment conducive to bacterial colonization, leading to right-sided IE and increasing the risk of damage to the tricuspid valve, often resulting in organic tricuspid regurgitation (TR). The pathophysiological mechanisms behind this include the mechanical trauma and increased hemodynamic stress on the septal tricuspid leaflet caused by the VSD, facilitating bacterial colonization and valvular damage. The incidence of IE is higher in developing countries, with VSD-associated IE occurring at a rate of 2 cases per 1,000 patient-years (Bezza et al., 2023). The causative organisms are predominantly *Streptococcus* and *Enterococcus* species, with *Staphylococcus* species becoming more common, particularly in right-sided IE (Bezza et al., 2023, Piper et al., 2001).

The development of TR in this context can result from various mechanisms, including restriction of valve motion due to a septal aneurysm, distortion from high-velocity jets, or the Gerbode effect, which mimics TR (Desai et al., 2011, Hagler et al., 2002, Akdemir et al., 2005). While VSD closure can mitigate some of these mechanisms (Kumar et al., 2017, Abdelnabi and Almaghraby, 2021), the occurrence of extensive leaflet destruction, leading to chronic volume overload and exacerbated TR, remains rare (Fig. 4). Recurrent right-sided IE often leads to progressive tricuspid valve destruction, resulting in torrential TR, which can cause significant hemodynamic compromise, manifesting as right heart failure with symptoms such as hepatomegaly, peripheral edema, and poor weight gain in pediatric patients.

Chronic, subclinical volume overload due to recurrent heart failure from IE is exceptionally rare in the pediatric population. Although most cases of right-sided IE respond well to antibiotic therapy, about 20% of patients require surgical intervention (Sforna et al., 2023, Mumpuni and Dinarti, 2018). Indications for surgery include persistent right heart failure despite medical treatment, large vegetations, uncontrolled bacteremia, or the risk of systemic embolization or damage to surrounding structures (Elliott et al., 2004). Surgical timing is debated, with some experts recommending delay until after active infection control to avoid the risk of patch infection (Jiang et al., 2011). In such cases, VSD closure and tricuspid valve repair or replacement may be necessary to prevent irreversible cardiac damage.

Tricuspid valve reconstruction in these cases requires thorough debridement of infected tissue and careful valve repair while minimizing the use of prosthetic materials. The overall mortality rate in congenital heart disease with IE is reported to be 11% during the active phase, with an 8% mortality rate in medically managed cases (Niwa et al., 2005). Mortality typically results from surgery-related complications, renal failure, and progressive cardiac failure. Long-term management of recurrent right-sided IE includes vigilant monitoring for valve damage, heart failure, and potential complications like pulmonary hypertension and arrhythmias. Lifelong antibiotic prophylaxis may be indicated to reduce the risk of recurrent infections, particularly in patients undergoing surgical procedures or dental interventions.

### 4. CONCLUSIONS

In conclusion, right-sided infective endocarditis (IE) associated with ventricular septal defects

(VSDs) and tricuspid regurgitation (TR) presents significant clinical challenges, particularly in the pediatric population. While antibiotic therapy is often effective in managing these cases, recurrent right heart failure and chronic volume overload due to extensive valve damage may necessitate surgical intervention. The decision to proceed with surgery is complex, often requiring a balance between controlling active infection and preventing further valve destruction. Tricuspid valve reconstruction, when performed, requires meticulous debridement and preservation of native tissue to optimize outcomes. Despite advances in treatment, mortality rates remain significant, underscoring the importance of early diagnosis, timely intervention, and comprehensive management strategies.

#### DISCLAIMER (ARTIFICIAL INTELLIGENCE)

Author(s) hereby declare that NO generative AI technologies such as Large Language Models (ChatGPT, COPILOT, etc.) and text-to-image generators have been used during the writing or editing of this manuscript.

#### CONSENT

As per international standards, parental written consent has been collected and preserved by the author(s).

#### ETHICAL APPROVAL

As per international standards or university standards written ethical approval has been collected and preserved by the author(s).

#### SUPPLEMENTARY MATERIALS

Supplementary material is available in the following link:

**Supplementary video 01:** Modified Apical four chamber view demonstrating severe tricuspid regurgitation and ventricular septal defect with left to right shunt (<https://journalajcr.com/index.php/AJCR/libraryFiles/downloadPublic/6>)

**Supplementary video 02:** Apical four chamber view demonstrating severe tricuspid regurgitation(<https://journalajcr.com/index.php/AJCR/libraryFiles/downloadPublic/7>)

#### COMPETING INTERESTS

Authors have declared that no competing interests exist.

#### REFERENCES

- Bezza, S., Jazouli, H. E., Haffane, F., Eljamili, M., Karimi, S. E., & Hattouai, M. E. (2023). Late manifestation of congenital heart disease: Right-side infective endocarditis and the mystery of the unseen ventricular septal defect: Case report. *Cardiology and Angiology: An International Journal*, 12, 363-366.  
<https://doi.org/10.9734/ca/2023/v12i4380>
- Piper, C., Körfer, R., & Horstkotte, D. (2001). Prosthetic valve endocarditis. *Heart*, 85(5), 590-593.  
<https://doi.org/10.1136/heart.85.5.590>
- Desai, R. V., Seghatol-Eslami, F., Nabavizadeh, F., & Lloyd, S. G. (2011). Unusual mechanism of tricuspid regurgitation in ventricular septal defect. *Echocardiography*, 28, 36-38. <https://doi.org/10.1111/journal.pmed.21210838>
- Hagler, D. J., Squarcia, U., Cabalka, A. K., Connolly, H. M., & Leary, P. W. (2002). Mechanism of tricuspid regurgitation in paramembranous ventricular septal defect. *Journal of the American Society of Echocardiography*, 15, 364-368.  
<https://doi.org/10.1067/journal.pmed.11944015>
- Akdemir, R., Ozhan, H., Ozer, I., Unlu, H., Bulur, S., & Uyan, C. (2005). Membranous septal aneurysm causing severe tricuspid regurgitation and ring-like appearance. *Echocardiography*, 22, 857-858.  
<https://doi.org/10.1111/journal.pmed.16343172>
- Kumar, V., Aggarwal, N., Swamy, A., & Garg, S. (2017). Disappearing high velocity severe tricuspid regurgitation following ventricular septal defect device closure. *Indian Heart Journal*, 69, 402-404.  
<https://doi.org/10.1016/journal.pmed.28648440>
- Abdelnabi, M., & Almaghraby, A. (2021). Ventricular septal defect causing tricuspid regurgitation with consequent pulmonary hypertension and right ventricular hypertrophy. *The Southwest Respiratory and Critical Care Chronicles*, 9, 77-78.  
<https://doi.org/10.12746>
- Sforna, S., Padoan, L., Del Papa, M., Grikstaite, E., Sardone, M., & Savino, K. (2023).

- Ventricular septal defect and right-sided infective endocarditis. *Journal of Cardiovascular Echography*, 33(2), 95-97. [https://doi.org/10.4103/jcecho.jcecho\\_25\\_23](https://doi.org/10.4103/jcecho.jcecho_25_23)
- Mumpuni, H., & Dinarti, L. K. (2018). Right-sided infective endocarditis in patients with uncorrected ventricular septal defect and patent ductus arteriosus: Two case reports. *Clinical Case Reports*, 6, 2168-2173. <https://doi.org/10.1002/ccr3.1672>
- Elliott, T. S., Foweraker, J., Gould, F. K., Perry, J. D., Sandoe, J. A., & Working Party of the British Society for Antimicrobial Chemotherapy. (2004). Guidelines for the antibiotic treatment of endocarditis in adults: Report of the Working Party of the British Society for Antimicrobial Chemotherapy. *Journal of Antimicrobial Chemotherapy*, 54, 971-981. <https://doi.org/10.1093/journal.pmed.15546974>
- Jiang, S. L., Li, B. J., Zhang, T., Ren, C. L., Wang, Y., Chen, T. T., & Gao, C. Q. (2011). Surgical treatment of isolated right-sided infective endocarditis. *Texas Heart Institute Journal*, 38, 639-642. <https://doi.org/journal.pmed.22199423>
- Niwa, K., Nakazawa, M., Tatenos, S., Yoshinaga, M., & Terai, M. (2005). Infective endocarditis in congenital heart disease: Japanese national collaboration study. *Heart*, 91, 795-800. <https://doi.org/10.1136/journal.pmed.15894782>

**Disclaimer/Publisher's Note:** The statements, opinions and data contained in all publications are solely those of the individual author(s) and contributor(s) and not of the publisher and/or the editor(s). This publisher and/or the editor(s) disclaim responsibility for any injury to people or property resulting from any ideas, methods, instructions or products referred to in the content.

© Copyright (2025): Author(s). The licensee is the journal publisher. This is an Open Access article distributed under the terms of the Creative Commons Attribution License (<http://creativecommons.org/licenses/by/4.0>), which permits unrestricted use, distribution, and reproduction in any medium, provided the original work is properly cited.

*Peer-review history:*  
The peer review history for this paper can be accessed here:  
<https://www.sdiarticle5.com/review-history/129494>