



Investigation of Hepatozoon Canis Related Alterations in the Haemato Biochemical Profile of Dogs

Sonika Verma ^{a++*}, Mukesh Kumar Srivastava ^{a#},
Jitendra Tiwari ^{b#}, Alok Kumar ^{c†}, Shruti Bhatt ^{a‡},
Rupam Sachan ^{b++}, Arpana Raikwar ^{a‡} and Shveta Singh ^{a++}

^a Department of Veterinary Medicine, CVSc&AH, DUVASU, Mathura, India.

^b Department of Veterinary Parasitology, CVSc&AH, DUVASU, Mathura, India.

^c Department of Veterinary Gynaecology & Obstetrics, Bihar Veterinary College, BASU, Patna, India.

Authors' contributions

This work was carried out in collaboration among all authors. Author SV collected the samples and conducted the research work, wrote the first draft of the manuscript. Author MKS wrote the protocol for the study and managed the analyses. Author JT performed the statistical analysis and contributed to write the manuscript. Author AK contributed to edited the manuscript. Authors SB and SS helped in collection of samples from dogs and managed the literature searches. All authors read and approved the final manuscript.

Article Information

DOI: <https://doi.org/10.9734/jabb/2024/v27i91333>

Open Peer Review History:

This journal follows the Advanced Open Peer Review policy. Identity of the Reviewers, Editor(s) and additional Reviewers, peer review comments, different versions of the manuscript, comments of the editors, etc are available here: <https://www.sdiarticle5.com/review-history/122379>

Original Research Article

Received: 25/06/2024

Accepted: 29/08/2024

Published: 02/09/2024

⁺⁺ Post Graduate Research Scholar;

[#] Associate Professor;

[†] Assistant Professor;

[‡] PhD Research Scholar;

*Corresponding author: E-mail: vetsonika@gmail.com;

Cite as: Verma, Sonika, Mukesh Kumar Srivastava, Jitendra Tiwari, Alok Kumar, Shruti Bhatt, Rupam Sachan, Arpana Raikwar, and Shveta Singh. 2024. "Investigation of Hepatozoon Canis Related Alterations in the Haemato Biochemical Profile of Dogs". *Journal of Advances in Biology & Biotechnology* 27 (9):603-11. <https://doi.org/10.9734/jabb/2024/v27i91333>.

ABSTRACT

Aims: Hepatozoonosis, caused by a protozoan parasite *Hepatozoon canis*, is important for canine health due to its ability to cause chronic, debilitating disease, and the challenges it presents in terms of diagnosis and management. The present study was conducted to see the effect of *H. canis* infection on various haematological and biochemical parameters as compared to the normal healthy dogs in order to understand the disease pattern and suspecting the disease.

Study Design: The clinically affected dogs that come to the veterinary hospital with symptoms of hepatozoonosis were included in the study. Haematological and biochemical parameters of dogs found positive for hepatozoonosis were analysed. The values of these parameters were subsequently compared to healthy animals in order to identify any significant difference caused by *H. canis*.

Place and Duration of Study: The studied was conducted at Department of Veterinary Medicine, DUVASU Mathura, India. Total 212 blood samples were collected from the dogs that were brought for the treatment in between February 2023 to March 2024.

Methodology: Total 212 dogs were included in the present study out of this 46 dogs were found positive with *H. canis* using PCR based molecular test. These positive animals were subjected to study the changes in biochemical parameters like blood urea nitrogen, creatinine, alkaline phosphatase, alanine transaminase, aspartate amino transferase, total leucocyte count, total erythrocyte count, haemoglobin, haematocrit, erythrocyte indices (MCV, MCH, MCHC), differential leucocyte count, platelet count and platelet indices (MPV, PDW) using autoanalyzer. Student's t-test in Graphpad Prism was used to compare these values to healthy animals.

Results: The study confirms that Hepatozoonosis leads to significant haematological and biochemical changes in dogs. Infected dogs have lower Hb, TEC, and PCV than healthy animals, indicating anaemia. Thrombocytopenia and leukocytosis were also observed in the infected animals. Non-significant differences in MCV, MCH, and MCHC indicate normocytic, normochromic anaemia. Anisocytosis and non-regenerative anaemia is indicated by significant RDW-CV increases with decrease in MCV values. Increased liver-specific enzymes like ALT, AST, and ALP and kidney-related enzymes like BUN and CRT suggest hepatic and renal involvement in disease pathophysiology.

Conclusion: In hepatozoonosis, haemato- biochemical parameters like non-regenerative anaemia, anisocytosis, thrombocytopenia, leukocytosis, low serum protein concentration and increased ALT, AST, ALP and BUN values may be used as non-specific biomarkers. The results can be used in making clinical decisions and monitoring therapeutic responses in cases of hepatozoonosis.

Keywords: *Hepatozoon canis*; canine; haematology; biochemical study; RDW-CV.

1. INTRODUCTION

Hepatozoonosis is a canine parasitic disease caused by protozoa belonging to the *Hepatozoon* genus. Unlike other infections transmitted by vectors, this parasite is mostly spread through the consumption of infected *Rhipicephalus sanguineus* ticks that carry mature oocysts of *H. canis*. Dogs can also get infected by consuming prey animals that are infested with ticks carrying the disease. Furthermore, the transfer of the infection from infected mothers to their offspring has been recorded in puppies [1,2]. The first documented case of *H. canis* infection was reported in India in 1905 [3]. The presence of gamonts in the cytoplasm of leukocytes is the diagnostic stage in dog. Hepatozoonosis is more common in geographical areas, such as India, that provide ideal temperature and

humidity conditions for the proliferation of tick populations.

The *Hepatozoon* parasite is considered to be closely related to other apicomplexan parasites, such as *Plasmodium* spp. and piroplasms, based on its morphology and molecular characterization. The parasite shares similar symptoms with tick-borne infections such as babesiosis and hepatozoonosis, which complicates the diagnosis. The conventional diagnostic techniques, such as microscopy and cytology, frequently fall short in detecting all cases of *H. canis* infections in dogs [4]. Therefore, molecular diagnostics is necessary for reliably identifying such infections. In India, the occurrence of this infection is quite low when compared to other canine hemoparasites. However, this could be attributed to the reduced

sensitivity of microscopic inspection that frequently used for diagnosis.

The clinical symptoms of hepatozoonosis in dogs are not well-defined, which presents difficulties for veterinarians in terms of diagnosing and managing the disease. The clinical condition in dogs can range from a minor or unnoticed infection to a severe illness that might result in mortality [3]. Dogs who have been infected may display many clinical symptoms, including fever, lethargy, weight loss, muscle soreness, and anaemia. The infection eventually progresses to a chronic stage if left untreated, necessitating prolonged therapy and care.

Haemoprotozoan diseases have been demonstrated to result in substantial changes in haematological and biochemical parameters of hosts. Haemato-biochemical study can be crucial in the diagnosis and management of *H. canis* infections, as it provides essential insights into the systemic impact of the parasite on the host. These studies often reveal anemia, leukocytosis, and hyperglobulinemia, elevated liver enzymes, reflecting hepatic involvement, and increased creatine kinase levels, indicating muscle damage, which are critical for assessing the severity of the disease [5].

The current study intended to explore the effect of *H. canis* infection on haematological and biochemical markers in order to better understand the disease pattern. Present study included clinical cases of dogs that were brought to U.P. Pt. Deen Dayal Upadhyaya Pashu Chikitsa Vigyan Vishwavidyalaya Evam Go-Anusandhan Sansthan (DUVASU), Mathura with symptoms of fever, loss of appetite, and lethargy, and were confirmed to have hepatozoonosis through the use of a species-specific PCR assay. The haematological and biochemical characteristics that were identified can serve as non-specific indicators for hepatozoonosis. The results will be helpful in making clinical decisions and monitoring therapeutic responses in suspected cases of dogs.

2. MATERIALS AND METHODS

2.1 Topography of Studied Area

The research was conducted in the Mathura region of western Uttar Pradesh. The region comprised of semi-arid zone of Northern India. The area is situated at 77.6737°E longitude axis and 27.4924°N latitude. The favorable weather

conditions in this region, characterized by high humidity and warm temperatures, contribute to the expansion of tick populations, making it endemic for a range of tick-borne diseases.

2.2 Screening of Dogs for Study

During the study period from February 2023 to March 2024, a total of 212 dogs exhibiting clinical symptoms such as fever, loss of appetite, anaemia, lethargy etc. were brought to the Teaching Veterinary Clinical Complex of Veterinary University DUVASU, Mathura. Animals that tested positive (n=46) for *H. canis* using species-specific PCR were studied for haematological and biochemical changes. Likewise, blood was also collected from the healthy animals as control group. To accomplish this, around 2 ml of blood was obtained from either the cephalic or saphenous vein using vacutainer tubes that contained EDTA. The serum required for biochemical parameter analysis was collected in 5 ml capacity test tubes without any anticoagulant. The study encompassed dogs of all ages, genders, and breeds.

2.3 Haematological Analysis

Hematological parameters like total leucocyte count (TLC), total erythrocyte count (TEC), hemoglobin (Hb), haematocrit (HCT), erythrocyte indices [mean corpuscular volume (MCV), mean corpuscular hemoglobin (MCH), mean corpuscular hemoglobin concentration (MCHC)] differential leucocyte count (Monocytes, Eosinophil, Neutrophil, Lymphocyte), platelet count (PLT), platelet indices [Mean Platelet Volume (MPV), Platelet Distribution Width (PDW) and Platelet Count, and red cell distribution width (RDW-CV and RDW-SD) were done by fully automated hematology analyzer (Ceiltac α , Nihon Kohden).

2.4 Biochemical Analysis

Biochemical studies were carried out with the help of autochem ingeniius analyzer (AKRAY Healthcare Pvt. Ltd.) using diagnostic kits (Span Diagnostics). Various biochemical parameters studied with the serum samples were blood urea nitrogen (BUN), creatinine (CRT), alkaline phosphatase (ALP), alanine transaminase (ALT), aspartate amino transferase (AST), total protein (TP), albumin (ALB). Globulin (GLB) was calculated by subtracting albumin from total protein.

2.5 Statistical Analysis

The values of various parameters were expressed as mean \pm S.E. and data were analyzed by independent samples two tailed t-test using Graphpad Prism software. Values of different haematological parameters in different groups were tested for normality as per Shapiro-Wilk normality test. The level of statistical significance for all comparisons was established at ($P = .05$).

3. RESULTS AND DISCUSSION

3.1 Haematological Analysis

The haematological profile of dogs that tested positive for *H. canis* infection is presented in Table 1 and Fig. 1. The haematological parameters in different groups were tested for normalcy using the Shapiro-Wilk normality test, and no significant differences were found. The average values of TEC, Hb, HCT, and PLT were significantly lower ($P < .05$) in affected dogs compared to healthy control. On the other hand, the average values of TLC, lymphocytes, and RDW-CV were significantly ($P < .05$) higher in affected dogs compared to healthy control. The average values of the other parameters in affected dogs did not show any significant difference compared to those of healthy control dogs.

The reduced values of TEC, Hb, and HCT of the present study align with the results of prior investigations conducted by [5,6,7]. The fluctuations seen in the blood parameters of the canines in this investigation could be attributed to the proliferation of the protozoa in the animal's tissues. The decreased haemoglobin levels can be attributed to impaired protein synthesis resulting from the increasing destruction of hepatocytes caused by *H. canis* infection. *H. canis* infection is supposed to impact the liver of dogs [8,9] have documented reduced haemoglobin levels in dogs afflicted with hepatozoonosis.

The positive cases showed an elevated TLC along with an increase in neutrophils, which is consistent with previous findings by [9,10,11]. The rise in the TLC may be attributed to the ongoing inflammatory alterations caused by the *H. canis* infection. The increase in neutrophils is likely a result of necrosis and inflammation occurring in the spleen, lymph nodes, liver, and lungs due to *H. canis* infection [12]. The changes

seen may be attributed to the proliferation of the parasite in the animal's organs, leading to an inflammatory response that could be exacerbated by concurrent haemoprotozoa infection. The ratio of neutrophil to lymphocyte counts is a straightforward, quick, and dependable way to assess the level of systemic inflammation [13].

Thrombocytopenia has been observed in cases of canine hepatozoonosis by multiple researchers in earlier studies [5,9,14]. Our investigation found no statistically significant disparity in the MCV, MCH, or MCHC values between the infected animals and the healthy animals. This indicates the presence of normocytic normochromic anaemia in the infected animals. The present data align with the findings of previous studies conducted by [15,16], which demonstrated minimal alterations in the average MCV, MCH, and MCHC levels in dogs affected by the infection.

RDW is considered to be a more accurate predictor of anaemia compared to microscopic evidence of anisocytosis, which sometimes lead to incorrect identification [17]. MCV is the primary metric commonly employed to define anaemia and to determine the bone marrow response, in conjunction with the RDW [18]. However, in order to see a change in MCV, a significant number of RBCs with modified volumes is necessary. On the other hand, even a small change in the size of RBCs might affect the RDW [19], which can be used as a possible indicator for diagnosing anaemia. The measures RDW and MCV are essential for classifying anaemia in dogs [20]. Our investigation found that the infected groups had considerably higher RDW-CV values compared to the control group, although the MCV values were within the usual range. A higher RDW-CV and normal MCV levels suggests the presence of non-regenerative anaemia. Previous reports and literature have indicated the existence of non-regenerative anaemia in hepatozoonosis, as mentioned in previous studies [21,22]. Hepatozoonosis is typically regarded as a persistent infection that commonly results in a chronic disease in dogs [23,24,11] also linked non-regenerative anaemia in hepatozoonosis to the prolonged duration of infection.

3.2 Biochemical Analysis

The serum biochemical values of dogs infected with Hepatozoonosis, compared to healthy dogs,

are presented in Table 2 and Fig. 2. The values of the biochemical parameters in separate groups were tested for normalcy using the Shapiro-Wilk normality test, and no significant differences were found. A statistically significant increase ($P < .05$) was observed in the mean values of ALT, AST, ALP, BUN, and globulin in infected dogs compared to the healthy control group. Nevertheless, there was a significant ($P <$

.05) reduction in the levels of total protein and albumin in the serum samples of infected dogs when compared to the healthy animals. The current findings of increased ALT, AST and ALP in hepatozoonosis cases are consistent with earlier studies [25,26]. ALT is a liver-specific enzyme in dogs and elevations in this enzymes can occur as a result of hepatic injury [27].

Table 1. Hematological parameters (mean±SE) of dogs infected with hepatozoonosis

Parameter	Dogs with Hepatozoonosis (n=46)	Healthy dogs (n=10)	P-value
TLC ($\times 10^3/\mu\text{L}$)	16.36±1.29	10.75±0.79	$P < .001$
TEC ($\times 10^6/\mu\text{l}$)	3.71±1.06	6.67±0.44	$P < .001$
Hb (gm/dl)	8.46±0.97	13.80±0.64	$P < .001$
HCT (%)	24.55±4.81	41.30±2.29	$P < .001$
MCV (fL)	62.65±3.81	64.15±1.75	ns
MCH (pg)	22.87±1.89	23.15±0.62	ns
MCHC (gm/dl)	34.39±1.02	34.48±0.44	ns
Monocytes (%)	6.78±1.59	6.17±0.40	ns
Eosinophil (%)	1.93±0.27	2.73±0.54	ns
Neutrophil (%)	54.90±6.09	68.65±0.40	ns
Lymphocyte (%)	39.63±6.93	18.35±1.34	$P < .001$
PLT ($10^5/\mu\text{L}$)	122.95±15.67	351.60±49.53	$P < .001$
MPV (fl)	6.43±0.48	6.79±0.24	ns
PDW (%)	17.23±1.42	18.35±1.34	ns
RDW-CV (%)	15.06±1.15	11.66±1.37	$P < .001$
RDW-SD (fl)	35.41±2.87	33.08±4.15	ns

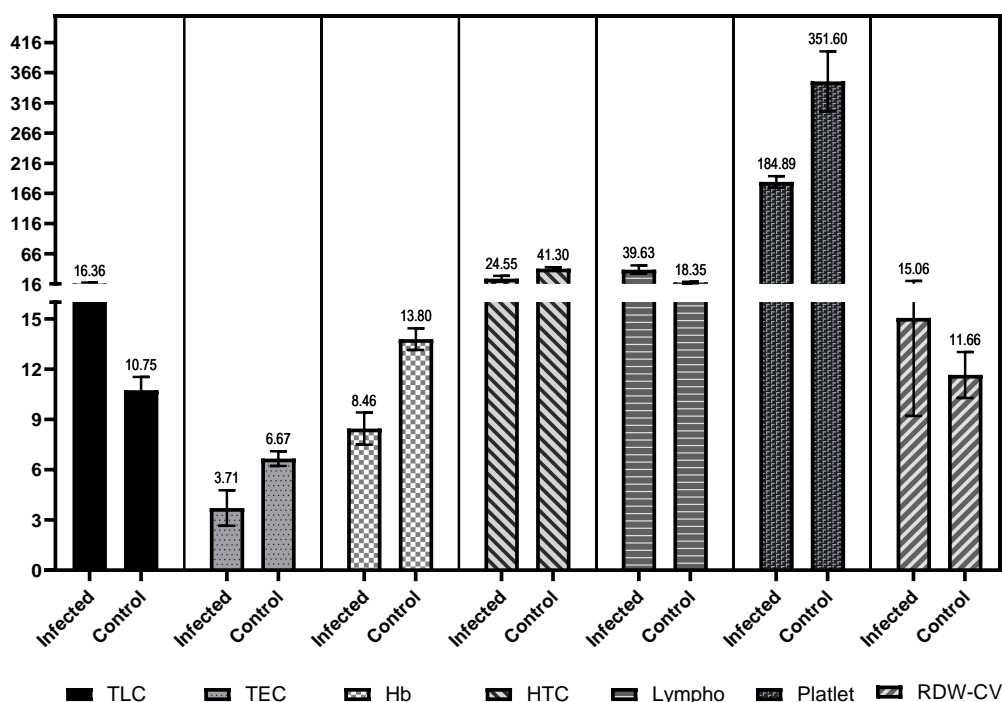


Fig. 1. Level of significantly different haematological parameters in infected vs healthy animals

Table 2. Serum biochemical parameters (mean±SE) of dogs infected with hepatozoonosis

Parameter	Dogs with Hepatozoonosis (n=46)	Healthy dogs (n=10)	P Value
Alanine transaminase (ALT) (IU/L)	126.41±5.36	25.03±1.17	<i>P</i> < .001
Aspartate transaminase (AST) (IU/L)	26.85±1.46	14.64±1.43	<i>P</i> < .001
Alkaline phosphatase (ALP) (IU/L)	290.68±2.44	34.60±1.43	<i>P</i> < .001
Total protein (TP) (gm/dl)	5.39±0.48	6.56±0.20	<i>P</i> < .05
Albumin (ALB) (gm/dl)	1.03±0.11	2.56±0.20	<i>P</i> < .05
Globulin (GLB) (gm/dl)	4.36±0.52	4.00±0.06	<i>P</i> < .05
Blood urea nitrogen (BUN) (mg/dl)	36.32±3.36	23.43±1.03	<i>P</i> < .001
Creatinine (CRT) (mg/dl)	0.69±0.37	0.63±0.06	ns

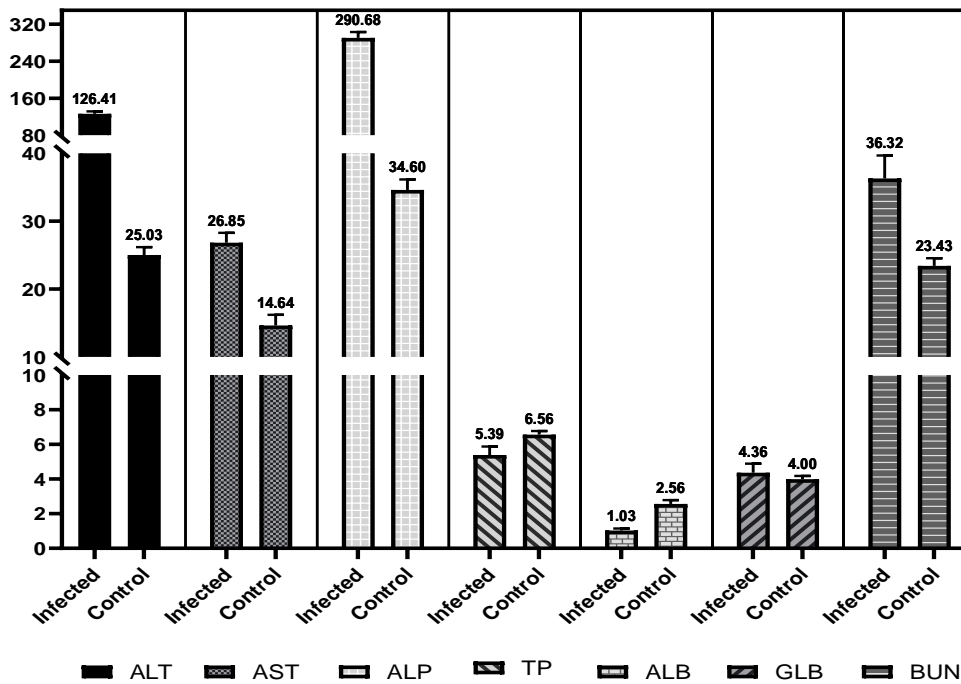


Fig. 2. Level of significantly different biochemical parameters in infected vs healthy animals

The current investigation revealed that, in comparison to the control group, the infected dogs had considerably lower levels of total protein and albumin on the day of presentation. Our findings were consistent with the results of previous studies [8,14]. Hepatozoonosis may result in hypoproteinemia due to renal tissue injury. Hepatozoonosis is associated with the development of protein-losing nephropathy, as documented by [28,29,30]. Hypoalbuminemia is caused by reduced protein consumption, persistent inflammation, or protein-losing nephropathy [31,32] reported that Hypoproteinemia may result from heightened hepatocyte destruction, as *H. canis* is known to significantly impact the liver and spleen.

The present investigation demonstrated a statistically significant increase in BUN levels in animals infected with *H. canis*. The observed elevation in BUN levels in this study suggests potential kidney damage, specifically to the glomeruli, which play a crucial role in the filtration process. *H. canis* has previously been implicated as a potential cause of glomerulonephritis due to its schizogony process, which also occurs in the kidney [28].

4. CONCLUSION

Haemato-biochemical study can be crucial in the diagnosis and management of *H. canis* infections, as it provide essential insights into the systemic impact of the parasite on the host. The

findings of the present study suggest that hepatozoonosis has a significant impact on the blood and biochemical characteristics of infected dogs, anaemia, anisocytosis, thrombocytopenia, leukocytosis, low serum protein concentration and increased ALT, AST, ALP and BUN values. An elevated RDW in infected dogs suggests the existence of anisocytosis and non-regenerative anaemia. A lack of considerable variation in MCV, MCH, and MCHC suggests the presence of normocytic, normochromic anaemia. Abnormally high levels of ALT, AST, ALP and BUN reflecting liver and kidney involvement in the disease. Clinicians can utilize these haemato-biochemical parameters to anticipate and evaluate the likelihood of hepatozoonosis and to monitor the therapeutic responses against the parasite.

DISCLAIMER (ARTIFICIAL INTELLIGENCE)

Author(s) hereby declare that NO generative AI technologies such as Large Language Models (ChatGPT, COPILOT, etc) and text-to-image generators have been used during writing or editing of manuscripts.

ETHICAL APPROVAL

The blood was collected from the diseased dogs and healthy control animals under the ethical standards and guidelines of the Institutional Animal Ethics Committee (IAEC) and due permission was received from the ethical committee of the University via voucher no. IAEC/23-1/6 dated 25-10-2019.

ACKNOWLEDGEMENTS

Authors are thankful to the Vice-Chancellor DUVASU Veterinary University for providing necessary facilities for conducting this research.

COMPETING INTERESTS

Authors have declared that no competing interests exist.

REFERENCES

1. Murata T, Inoue M, Tateyama S, Taura Y, Nakama S. Vertical transmission of *Hepatozoon canis* in dogs. *J Vet Med Sci.* 1993;55(5):867-8. DOI: 10.1292/jvms.55.867. PMID: 8286548
2. Schäfer I, Müller E, Nijhof AM, Aupperle-Lellbach H, Loesenbeck G, Cramer S, Naucke TJ. First evidence of vertical

Hepatozoon canis transmission in dogs in Europe. *Parasit Vectors.* 2022 Aug 23;15(1):296.

DOI: 10.1186/s13071-022-05392-7. PMID: 35999592; PMCID: PMC9396588

3. Craig TM. Hepatozoonosis. In: C. Greene C, editor. *Infectious Diseases of the Dog and Cat.* 2nd ed. W. B. Saunders, Philadelphia; 1990.
4. Chisu V, Giua L, Bianco P, Masala G, Sechi S, Cocco R, Piredda I. Molecular survey of *Hepatozoon canis* infection in domestic dogs from sardinia, Italy. *Vet Sci.* 2023 Oct 31;10(11):640. DOI: 10.3390/vetsci10110640. PMID: 37999463; PMCID: PMC10674782
5. Voyvoda H, Pasa S, Uner A. Clinical Hepatozoon *canis* infection in a dog in Turkey. *J Small Anim Pract.* 2004 Dec;45(12):613-7. DOI: 10.1111/j.1748-5827.2004.tb00184.x. PMID: 15600273; PMCID: PMC7166916
6. Singh K, Singh H, Singh NK, Kashyap N, Sood NK, Rath SS. Molecular prevalence, risk factors assessment and haemato-biochemical alterations in hepatozoonosis in dogs from Punjab, India. *Comp Immunol Microbiol Infect Dis.* 2017 Dec;55:53-58. DOI: 10.1016/j.cimid.2017.10.001. Epub 2017 Oct 18. PMID: 29127993
7. Revathi P, Bharathi V, Muthukrishnan M. Molecular epidemiology, characterisation of *Hepatozoon canis* in dogs as well as in ticks and haemato-biochemical profile of the infected dogs in Chennai. *Indian J Anim Res.* 2022;1:1-8.
8. Hervás J, Carrasco L, Sierra MA, Méndez A, Gómez-Villamandos JC. Ultrastructural findings in natural canine hepatozoonosis. *Zentralbl Veterinarmed B.* 1997 Apr;44(2):119-25. DOI: 10.1111/j.1439-0450.1997.tb00957.x. PMID: 9151537
9. Vojta L, Mrljak M, Beck R. Haematological and biochemical parameters of canine hepatozoonosis in Croatia. *Vet. Arhiv.* 2012;82:359-370.
10. Gavazza M, Bizzeti R, Papini G. Observations on dogs found naturally infected with *Hepatozoon canis* in Italy. *Rev. Med. Vet.* 2003;154:565-571.
11. Chhabra S, Uppal SK, Singla LD. Retrospective study of clinical and hematological aspects associated with dogs naturally infected by *Hepatozoon canis* in Ludhiana, Punjab, India. *Asian Pac J Trop Biomed.* 2013 Jun;3(6):483-6.

- DOI: 10.1016/S2221-1691(13)60100-8.
PMID: 23730562; PMCID: PMC3644577
12. Gaunt SD. Extreme neutrophilic leucocytosis. In: Feldman BF, Zinkel JG, Jain NC editors. Schalm's veterinary haematology. 5th Ed. Lippincott, Williams & Wilkins, Baltimore; 2000.
 13. Zahorec R. Ratio of neutrophil to lymphocyte counts--rapid and simple parameter of systemic inflammation and stress in critically ill. Bratisl Lek Listy. 2001;102(1):5-14. English, Slovak. PMID: 11723675.
 14. Baneth G, Vincent-Johnson N editors. Hepatozoonosis in arthropod-borne infectious diseases of the dog and cat. CRC Press; 2016.
 15. Qamar M, Malik MI, Latif M, Ain QU, Aktas M, Shaikh RS, Iqbal F. Molecular detection and prevalence of *hepatozoon canis* in dogs from Punjab (Pakistan) and Hematological Profile of Infected Dogs. Vector Borne Zoonotic Dis. 2017 Mar;17(3):179-184. DOI: 10.1089/vbz.2016.1999. Epub 2016 Nov 14. PMID: 27841956
 16. Zoaktafi E, Sharifiyazdi H, Derakhshandeh N, Bakhshaei-Shahrbabaki F. Detection of *Hepatozoon spp.* in dogs in Shiraz, southern Iran and its effects on the hematological alterations. Mol Biol Res Commun. 2023;12(2):87-94. DOI: 10.22099/mbr.2023.47151.1821. PMID: 37520468; PMCID: PMC10382900
 17. Žvorc Z, Rafaj RB, Kuleš J, Mrljak V. Erythrocyte and platelet indices in babesiosis of dogs. Vet Arhiv. 2010;80:259-267.
 18. Neiger R, Hadley J, Pfeiffer DU. Differentiation of dogs with regenerative and non-regenerative anaemia on the basis of their red cell distribution width and mean corpuscular volume. Vet Rec. 2002;150(14):431-4. DOI: 10.1136/vr.150.14.431. PMID: 11993971
 19. Martinez C, Mooney CT, Shiel RE, Tang PK, Mooney L, O'Neill EJ. Evaluation of red blood cell distribution width in dogs with various illnesses. Can Vet J. 2019 Sep;60(9):964-971. PMID: 31523082; PMCID: PMC6697020
 20. de Souza AM, de Jesus Pereira J, Campos SD, Bacellar DT, de Almeida Torres Filho R, de Barros Macieira D et al. Behavior of red cell distribution width (RDW) in a population of anemic and non-anemic dogs from an ambulatory care unit. Rev Bras de Ciên Vet. 2017;24(1):18-21.
 21. Mundim AV, Morais IA, Tavares M, Cury MC, Mundim MJ. Clinical and hematological signs associated with dogs naturally infected by *Hepatozoon sp.* and with other hematozoa: A retrospective study in Uberlândia, Minas Gerais, Brazil. Vet Parasitol. 2008 May 6;153(1-2):3-8. DOI: 10.1016/j.vetpar.2008.01.018. Epub 2008 Jan 19. PMID: 18304739
 22. Paiz LM, Silva RC, Satake F, Fraga TL. Hematological disorders detected in dogs infected by *Hepatozoon canis* in a municipality in Mato Grosso do Sul State, Brazil. Arq Bras Med Vet Zootec. 2016 Sep;68:1187-94.
 23. Little SE, Allen KE, Johnson EM, Panciera RJ, Reichard MV, Ewing SA. New developments in canine hepatozoonosis in North America: a review. Parasit Vectors. 2009;26(2)Suppl 1:S5. DOI: 10.1186/1756-3305-2-S1-S5. PMID: 19426444; PMCID: PMC2679397
 24. Otranto D, Dantas-Torres F, Weigl S, Latrofa MS, Stanneck D, Decapariis D et al. Diagnosis of *Hepatozoon canis* in young dogs by cytology and PCR. Parasit Vectors. 2011;13(4):55. DOI: 10.1186/1756-3305-4-55. PMID: 21489247; PMCID: PMC3083373
 25. Barton CL, Russo EA, Craig TM, Green RW. Canine hepatozoonosis: A retrospective study of 15 naturally occurring cases. J Am Anim Asso. 1985;21:125-34.
 26. Kraft W, editor. Klinische labordiagnostik in der tiermedizin. Schattauer Verlag; 2005.
 27. Abraham P. Oxidative stress in paracetamol-induced pathogenesis: (I). Renal damage. Indian J Biochem Biophys. 2005 Feb;42(1):59-62. PMID: 23923583
 28. Baneth G. Perspectives on canine and feline hepatozoonosis. Vet Parasitol. 2011 Sep 8;181(1):3-11. DOI: 10.1016/j.vetpar.2011.04.015. Epub 2011 Apr 19. PMID: 21620568
 29. Vincent-Johnson N. Canine and feline hepatozoonosis. In: Sykes JE editor. Canine and feline infectious disease. Elsevier Saunders, St. Louis, Missouri; 2014.
 30. Littman MP. Protein-losing nephropathy in small animals. Vet Clin North Am Small Anim Pract. 2011 Jan;41(1):31-62. DOI: 10.1016/j.cvsm.2010.09.006. Epub 2010 Dec 16. PMID: 21251510

31. Medici EM, Heseltine J. American canine hepatozoonosis. *Compendium*. 2008;30(11):E1-9.
32. Klopfer U, Newman M, Nobel T. Hepatozoon canis in dogs in Israel. *Refug Vet*. 1973;30:116–120.

Disclaimer/Publisher's Note: The statements, opinions and data contained in all publications are solely those of the individual author(s) and contributor(s) and not of the publisher and/or the editor(s). This publisher and/or the editor(s) disclaim responsibility for any injury to people or property resulting from any ideas, methods, instructions or products referred to in the content.

© Copyright (2024): Author(s). The licensee is the journal publisher. This is an Open Access article distributed under the terms of the Creative Commons Attribution License (<http://creativecommons.org/licenses/by/4.0>), which permits unrestricted use, distribution, and reproduction in any medium, provided the original work is properly cited.

Peer-review history:

The peer review history for this paper can be accessed here:

<https://www.sdiarticle5.com/review-history/122379>