



Does Abdominoplasty Add Morbidity to Incisional Hernia Repair? Case Series and Review of the Literature

Amine El Harti ^{a*}, Sara Sabur ^a, Ahlam Youssfi ^a, Sarah Karti ^a, Driss Erguibi ^b and Mounia Diouri ^a

^a National Burn Center and Plastic Surgery Department CHU Ibn Rochd, Faculté de Médecine et Pharmacie de Casablanca, Hassan 2 University, Morocco.

^b General Surgery Department Aile 3, CHU Ibn Rochd, Faculté de Médecine et Pharmacie de Casablanca, Hassan 2 University, Morocco.

Authors' contributions

This work was carried out in collaboration among all authors. All authors read and approved the final manuscript.

Article Information

Open Peer Review History:

This journal follows the Advanced Open Peer Review policy. Identity of the Reviewers, Editor(s) and additional Reviewers, peer review comments, different versions of the manuscript, comments of the editors, etc are available here: <https://www.sdiarticle5.com/review-history/106405>

Case Study

Received: 06/07/2023
Accepted: 08/09/2023
Published: 11/09/2023

ABSTRACT

This study presents a case series of five obese female patients with significant incisional hernias. All cases underwent a combined procedure involving incisional hernia repair and abdominoplasty. No postoperative complications were observed, and patients achieved satisfactory functional and cosmetic outcomes. The study suggests the safety and effectiveness of this approach, emphasizing potential improvements in patients' quality of life and aesthetics. Additionally, a comprehensive review of the literature underscores the significance of this combined approach in managing incisional hernias in obese individuals. Further research is needed to validate these findings in larger patient cohorts, highlighting the importance of considering abdominoplasty during incisional hernia repair in this population.

*Corresponding author: E-mail: drelharti@gmail.com;

Keywords: Abdominoplasty; incisional hernia repair; morbidity; obesity; case series; cosmetic outcomes; complications.

ABBREVIATIONS

BMI : Body Mass Index;
Nbre : Number;
Cm : Centimeters.

1. INTRODUCTION

Incisional hernias are a common complication following abdominal surgeries, often associated with obesity and other risk factors [1]. These hernias not only present functional challenges but can also have a significant impact on the patient's quality of life due to their adverse cosmetic effects [2]. The management of incisional hernias has evolved over the years, with various surgical techniques aimed at achieving optimal outcomes [3-5].

Abdominoplasty, a surgical procedure designed to address excess abdominal skin and fat, has gained popularity in recent years [6]. The potential benefits of combining abdominoplasty with incisional hernia repair in obese patients with large hernias have been a topic of debate [7]. While some argue that this combined approach may lead to increased morbidity, others believe it can offer improved cosmetic results and patient satisfaction [8,9].

This study presents a case series of five female patients, all with a history of obesity and post-pregnancy laparotomies, all of whom had large postoperative incisional hernias. We investigate whether the addition of abdominoplasty to incisional hernia repair in these patients results in elevated morbidity and assess the functional and

cosmetic outcomes. This research aims to contribute to the existing body of knowledge regarding the safety and effectiveness of this combined approach.

2. CASE PRESENTATION

In this study, we carefully selected five female patients aged between 40 and 56 years, each exhibiting a body mass index (BMI) exceeding 30 kg/m² (30-39). These patients shared a common medical history marked by obesity, previous cesarean sections, and laparotomies. Their primary concern revolved around the presence of large postoperative incisional hernias, which manifested in various regions, including the midline, peri-umbilical area, and lateral regions. In three cases, cutaneous hypotrophy was also observed.

To ensure the suitability of these patients for the combined procedure, our preoperative preparations were meticulous (Table 1). This encompassed respiratory physiotherapy to optimize lung function and thorough pulmonary assessments. Utilizing the Caprini risk assessment score, our patients fell within the moderate risk category, with scores ranging from 3 to 6.

The surgical intervention involved a dual-pronged approach, combining retromuscular prefascial prosthetic reinforcement with abdominoplasty. It's noteworthy that liposuction was not concurrently performed during these procedures.

Table 1. Demographic and clinical data of patient

	Nbre
Age (years)	46 yege (40 and 56)
BMI	30 kg/m ² (30-39).
Prior surgery	
Cesarean (Pfannesteil)	3 cases
Laparotomy	1 case
Infraumbilical laparotomy	1 case
Cutaneous hypotrophy	3 cases
Prior attempts to repair hernia	3 cases
Location	
Midline periumbilical	3 cases
Midline infraumbilical	1 case
Midline and lateral	1 case
Defect size (cm)	> 10 cm
Caprini risk assessment score	4 (3-6)

Surgical Technique: Drawing of a standard abdominoplasty with or without umbilical transposition patient standing before before entering the operating room (Fig. 1).

The surgical procedure begins with the patient under general anesthesia and endotracheal intubation. Proper positioning is crucial, with a rolled cushion placed under the knees, and systematic anti-thrombotic compression stockings are applied.

The lower incision is carefully placed in the lowest skin crease above the pubic hairline and continued onto the superficial fascia of the anterior rectus sheath. The abdominal flap is then elevated deep to Scarpa's fascia, all while ensuring the preservation of optimal lymphatic drainage.

The next step involves identifying and handling the hernia sac. The sac is liberated, meticulously opened (Figs. 2, 3), and its contents are reintegrated into their original position. The omentum is spread out, and a thorough examination of the posterior aspect is conducted to identify any secondary herniations or areas of weakness; the hernia is then reduced.

The retrorectus spaces are entered bilaterally and extended both superiorly and inferiorly, from the symphysis pubis to the xiphoid. The posterior sheath is closed in the midline with an absorbable running 0 monofilament suture. A lightweight macroporous polypropylene-coated titanium mesh is placed over the posterior rectus fascia (Figs. 4, 5). The abdominal muscles are sutured together. This mesh placement is followed by suturing of the aponeurotic plane.

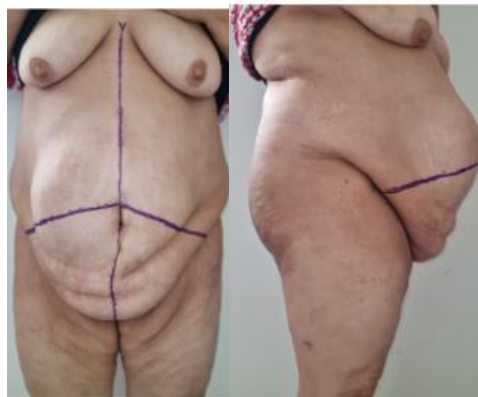

Fig. 1. The drawing of a standard abdominoplasty

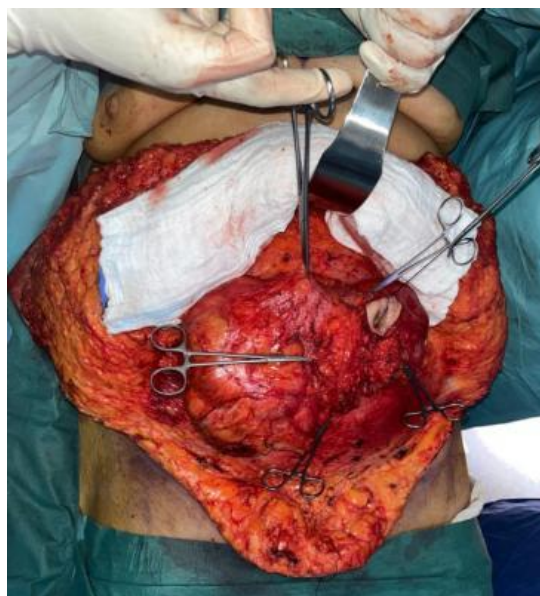

Fig. 2. The sac is liberated, meticulously opened

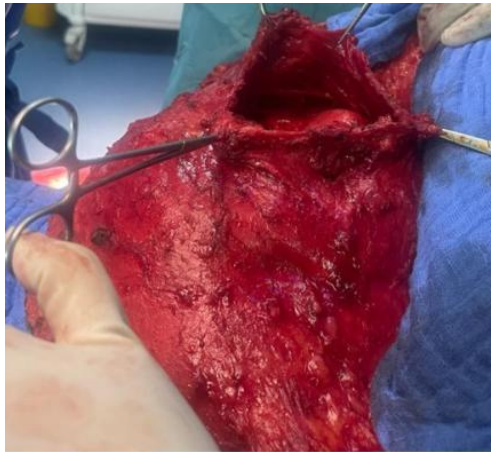


Fig. 3. Contents are reintegrated into their original position the posterior fascia is dissected from its adjacent structures

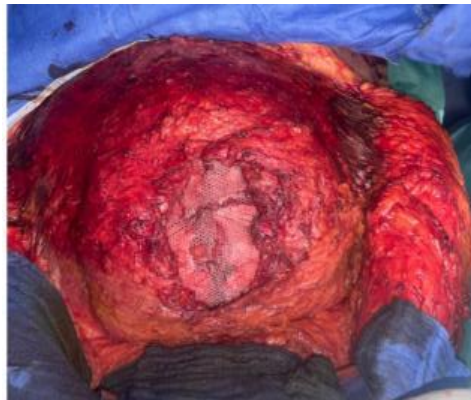

Fig. 4. Polypropylene-coated mesh is placed together over the posterior rectus fascia.

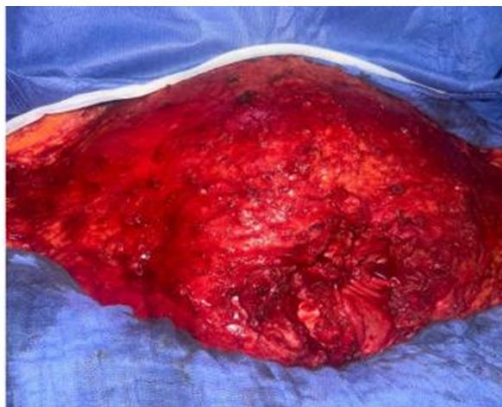

Fig. 5. The abdominal muscles are sutured followed by suturing of the aponeurotic plane

Subumbilical dissection continues, extending up to the costal margins and reaching the xiphoid process in the midline (Fig. 6). However, lateral dissection is less extensive, following a bell-shaped pattern, ensuring a precise and tailored approach to each patient's unique anatomy.

Depending on the condition of the abdominal wall, the surgical team may decide to perform aponeurotic plication using absorbable sutures, enhancing the overall structural integrity of the abdominal wall.

The patient's position is then adjusted to a semi-sitting one, facilitating the alignment of the upper and lower edges of the abdominal wall, a crucial step in achieving the desired outcome.

Excess skin is carefully resected, and the skin is meticulously closed over double Redon drains, promoting efficient fluid drainage during the early postoperative period (Fig. 7).

The dressing is a comprehensive one, incorporating elastic compression that covers the entire dissection area up to the epigastric region, supporting postoperative recovery (Fig. 8).

Early mobilization of the patient is initiated as early as the morning following the surgery, contributing to improved postoperative outcomes. Additionally, prophylactic heparin therapy is administered to reduce the risk of thrombotic

complications. Finally, the drains are removed between the 2nd and 3rd postoperative day if they produce less than 30 cc of fluid, ensuring the patient's comfort and recovery. This meticulously executed surgical technique aims to combine hernia repair with abdominoplasty, providing patients with both functional and cosmetic benefits while minimizing postoperative morbidity and complications.

The postoperative outcomes were exceptionally favorable, with no recorded complications among any of the patients (Fig. 9). All individuals experienced significant improvements in both functional and cosmetic aspects. In a singular instance, one patient required a planned umbilicoplasty as part of her personalized treatment plan. During the follow-up period spanning 1 to 3 years, there were no reports of complications or hernia recurrences.

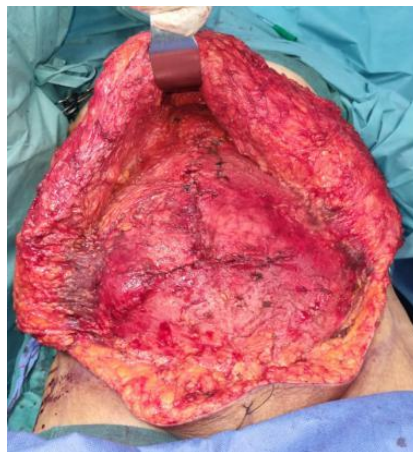

Fig. 6. Dissection extending up to the costal resected a margins and the xiphoid process

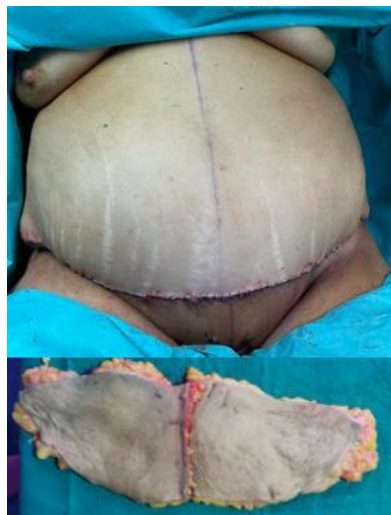

Fig. 7. The skin is closed and excess skin neo-umbilicoplasty will be performed later in this case

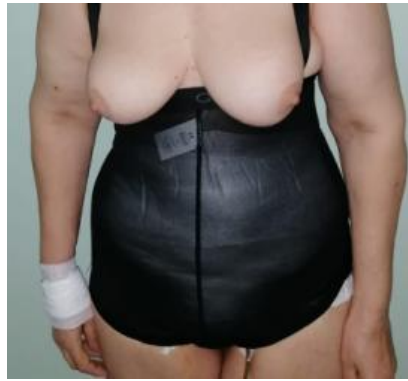

Fig. 8. Elastic compression

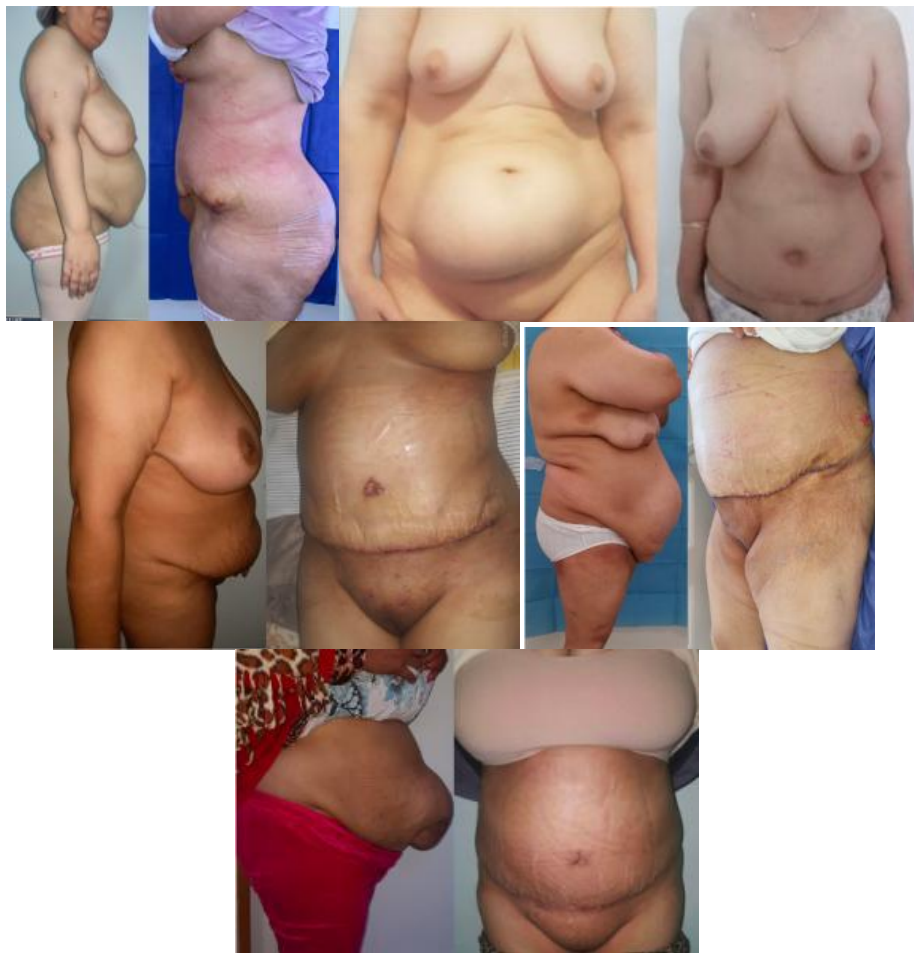

Fig. 9. Photo before and after surgery of the 5 cases

3. DISCUSSION AND LITERATURE REVIEW

In our case series of five female patients with large incisional hernias, we set out to determine whether the addition of abdominoplasty to hernia repair results in increased morbidity. Our findings indicate that this combined approach can be

performed safely with satisfactory functional and cosmetic outcomes.

Patients in our study had a history of obesity, Pfannenstiel cesarean sections, laparotomy, and presented with large postoperative incisional hernias. These hernias were located in various abdominal regions, including the midline

periumbilical, infraumbilical, and lateral regions, and were often accompanied by cutaneous hypotrophy in 3 out of 5 cases, which led us to propose this combined technique.

Our surgical intervention involved retromuscular prefascial prosthetic reinforcement combined with abdominoplasty, without concurrent liposuction. Early mobilization, preventive heparin therapy, and careful drain management were key components of our postoperative care protocol.

Importantly, none of the patients experienced complications, demonstrating the safety of our approach. Moreover, all patients achieved satisfactory functional and cosmetic outcomes, with a low risk of complications or hernia recurrences during the follow-up period ranging from 1 to 3 years.

However, our findings should be interpreted cautiously due to the small sample size, so we conducted a literature review of combining abdominoplasty with incisional hernia repair.

Abdominoplasty offers the potential advantage of covering the hernia repair with undisturbed anatomical planes, thereby reducing the risk of infection. It allows a thorough assessment of the abdominal wall before determining the appropriate surgical technique [2]. However, historically, surgeons have been hesitant to combine these two procedures during a single operation due to concerns about increased operative time, potential compromise of abdominal skin and fat vascularity, delayed healing, and their potential negative impact on outcomes [7]. Nevertheless, not all surgeons share these concerns.

Some studies have shown potential benefits of combining abdominoplasty with hernia repair. For example, Hughes et al. demonstrated that performing an abdominoplasty concurrently with hernia repair can reduce the incidence of wound complications and the risk of hernia recurrence [10]. Reid and Dumanian also reported a reduction in wound infection rates in such cases [11]. Another study by Karthikesalingam et al. suggested that preexisting scars did not significantly increase the risk of complications [12].

Many plastic surgeons are cautious about using meshes to reinforce the abdominal wall due to concerns about infection, dehiscence, extrusion,

and associated pain that may necessitate mesh removal. However, recent studies have explored the use of meshes during abdominoplasty with promising results, showing no significant complications or increased recurrence of abdominal bulge when meshes are placed in the retromuscular plane [13,14].

Patient selection is of paramount importance when considering the combination of hernia repair and abdominoplasty. The success and safety of these procedures hinge on identifying well-suited candidates. Surgeons must carefully assess patients for factors such as overall health, BMI, smoking history, and previous abdominal surgeries. Selecting patients with appropriate characteristics and expectations is crucial to achieving optimal outcomes and minimizing potential risks [8,9,15]. A comprehensive preoperative evaluation ensures that patients are well-informed about the procedure, have realistic expectations, and are mentally and physically prepared for the surgery. Additionally, patient selection plays a pivotal role in maintaining the balance between achieving cosmetic enhancements and addressing functional concerns, ultimately leading to improved patient satisfaction and quality of life [8,9,15].

Our experience supports the idea that concomitant hernia repair with mesh placement during abdominoplasty does not substantially increase risks or alter the postoperative course. This contradicts the outdated notion that aesthetics and prosthetic mesh are incompatible. Abdominoplasty, often seen as primarily an aesthetic procedure [6], has been shown to offer numerous benefits for patients beyond cosmetic improvement. These benefits include the removal of excess skin, improved hygiene, reduced skin infections, enhanced muscular tone, better posture, lumbar spine stabilization, scar reduction, increased self-esteem, improved quality of life, reduced anxiety, and improved personal relationships [6,16]. Patients often desire these changes, and the combination of hernia repair and abdominoplasty can offer them significant advantages.

Rios-Diaz AJ et al. demonstrated that combining abdominoplasty with hernia repair can improve patient satisfaction [17], particularly in terms of appearance, hygiene, and self-confidence. Similarly, a prospective study by Saarniemi et al. found that abdominoplasty significantly improved various aspects of patients' quality of life, body satisfaction, sexual functioning, self-esteem, and mental health [18].

Our study echoed these findings, with patients reporting improved quality of life and satisfaction. This combination surgery approach had a positive impact on patients' lives, reducing back pain, improving dressing, local hygiene, walking, incontinence, and constipation [19]. We observed substantial advantages for patients undergoing combined surgery, making it a highly recommendable option for well-selected patients [8,9,15].

4. CONCLUSION

Our case series suggests that for patients with large incisional hernias, the addition of abdominoplasty to hernia repair can be a safe and effective approach, yielding satisfactory functional and cosmetic outcomes. This combined procedure may provide an improved quality of life for patients, although additional research is needed to confirm these findings.

CONSENT

As per international standard or university standard, patient(s) written consent has been collected and preserved by the author(s).

ETHICAL APPROVAL

As per international standard or university standard written ethical approval has been collected and preserved by the author(s).

COMPETING INTERESTS

Authors have declared that no competing interests exist.

REFERENCES

1. Campanelli G. Incisional hernia repair: still a complex matter. *Hernia*. 2021 Apr;25(2):253.
2. Campanelli G. Incisional hernia, quality of life and the need for tailored surgery. *Hernia*. 2023 Aug;27(4):727.
3. Deerenberg EB, Henriksen NA, Antoniou GA, Antoniou SA, Bramer WM, Fischer JP, et al. Updated guideline for closure of abdominal wall incisions from the European and American Hernia Societies. *Br J Surg*. 2022 Nov 22;109(12):1239-1250.
4. Li J, Wang Y, Wu L. The Comparison of eTEP and IPOM in Ventral and Incisional Hernia Repair: A Systematic Review and Meta-analysis. *Surg Laparosc Endosc Percutan Tech*. 2022 Jan 17;32(2):252-258.
5. Zhang Q, Fu X, He K, Chen H, Zheng Y, Feng X, Yao Q. A new technique for the 3D reconstruction of the incisional hernia: A pilot study. *Clin Imaging*. 2020 Nov; 67:91-94.
6. Regan JP, Casaubon JT. Abdominoplasty. 2023 Jul 24. In: *StatPearls Treasure Island (FL): StatPearls Publishing; 2023 Jan*.
7. Shermak MA. Abdominoplasty with Combined Surgery. *Clin Plast Surg*. 2020 Jul;47(3):365-377.
8. Alfredo Moreno-Egea, Álvaro Campillo-Soto, and German Morales-Cuenca. Does Abdominoplasty Add Morbidity to Incisional Hernia Repair? A Randomized Controlled Trial. *Surg Innov* 2016 Oct;23(5):474-80.
9. Simon S, Thaller SR, Nathan N. Abdominoplasty combined with additional surgery: a safety issue. *Aesthet Surg J*. 2006;26:413-416.
10. Hughes KC, Weider L, Fischer J, et al. Ventral hernia repair with simultaneous panniculectomy. *Am Surg*. 1996;62:678-681.
11. Reid RR, Dumanian GA. Panniculectomy and the separation-of-parts hernia repair: a solution for the large infraumbilical hernia in the obese patient. *Plast Reconstr Surg*. 2005;116:1006-1012.
12. Karthikesalingam A, Kitcat M, Malata CM. Abdominoplasty in patients with and without pre-existing scars: a retrospective comparison. *J Plast Reconstr Aesthet Surg*. 2011;64:369-374.
13. Ogbuanya AU, Nnadozie UU, Onah LN, Anyanwu SNC, Mmeke AA. Anterior abdominal wall reconstruction with mesh implants: indications and limitations in a developing tropical economy. *Pan Afr Med J*. 2020 Sep 15;37:57.
14. East B, Plencner M, Otahal M, Amler E, de Beaux AC. Dynamic creep properties of a novel nanofiber hernia mesh in abdominal wall repair. *Hernia*. 2019 Oct;23(5):1009-1015.
15. Koolen PG, Ibrahim AM, Kim K, et al. Patient selection optimization following combined abdominal procedures: analysis of 4925 patients undergoing panniculectomy/ abdominoplasty with or without concurrent hernia repair. *Plast Reconstr Surg*. 2014;134:539e-550e.
16. Iljin A, Antoszewski B, Durczyński A, Lewandowicz E, Strzelczyk J. Long-Term Results of Incisional Hernia Repair with

- Concomitant Abdominoplasty in Postbariatric Patients. *Pol Przegl Chir.* 2016 May 1;88(3):147-54.
17. Rios-Diaz AJ, Morris MP, Elfanagely O, Cunning JR, Davis H, Shakir S, Broach RB, Fischer JP. Impact of Panniculectomy and/or Abdominoplasty on Quality of Life: A Retrospective Cohort Analysis of Patient-Reported Outcomes. *Plast Reconstr Surg.* 2022 Oct 1;150(4):767e-775e.
18. Saariniemi KM, et al. Abdominoplasty improves quality of life, psychological distress, and eating disorder symptoms: A prospective study. *Plast Surg Int.* 2014; 2014:197232.
19. Moreno-Egea A, Campillo-Soto Á, Morales-Cuenca G. Does abdominoplasty add morbidity to incisional hernia repair? A Randomized Controlled Trial. *Surg Innov.* 2016 Oct;23(5):474-80.

© 2023 El Harti et al.; This is an Open Access article distributed under the terms of the Creative Commons Attribution License (<http://creativecommons.org/licenses/by/4.0>), which permits unrestricted use, distribution, and reproduction in any medium, provided the original work is properly cited.

Peer-review history:

The peer review history for this paper can be accessed here:
<https://www.sdiarticle5.com/review-history/106405>