

Joubert Syndrome with Renal and Cerebral Manifestations: A Case Series of Three Siblings

SUSHANT KUMAR¹, ASHOK BHAT²

ABSTRACT

Joubert syndrome is a rare genetic disorder. Marie Joubert made the first official diagnosis of the syndrome in 1969. It is characterised by aberrant neurodevelopment and a complex midbrain-hindbrain malformation which can be seen on the Magnetic Resonance Imaging (MRI) as molar tooth sign. The present case series reports three siblings from a consanguineous marriage. The first child had delayed developmental milestones, ataxia, mental retardation and presented with advanced renal failure and succumbed to uremic complications. The second and third siblings also had similar clinical findings and the diagnosis of Joubert syndrome was confirmed by the presence of molar tooth sign on MRI. The presence of renal failure in them was detected earlier than the first sibling with favourable outcome in both. The characteristic symptoms of Joubert syndrome include developmental delay, intellectual disability, ocular abnormalities, and lack of control over voluntary movements. Each sibling of an affected individual has a 25% chance of developing the disease, a 50% chance of being an asymptomatic carrier, and a 25% chance of being not affected and not being a carrier. Renal involvement occurs in approximately one third of patients. In the present case series, all the siblings were affected by the syndrome and developed renal failure which is extremely rare. Failure to evaluate the renal function in these patients can result in delayed presentation with adverse outcome as seen in the first sibling. The case series highlights the importance of considering this disorder in the differential diagnosis of chronic kidney disease, especially in cases with a family history and other suggestive symptoms and the need for early recognition and management of the disorder, as early intervention and supportive care can improve the patient's quality of life and prognosis.

Keywords: Developmental delay, Mental retardation, Molar tooth sign, Ocular abnormality, Renal failure

INTRODUCTION

An uncommon genetically heterogeneous illness with autosomal recessive inheritance is Joubert syndrome [1]. It is characterised by aberrant eye movements, developmental delay, and respiratory irregularities [2], as well as a characteristic brainstem and cerebellum malformation known as the "molar tooth sign" on MRI [2]. Numerous additional neurological, intellectual, physical, and organ involvement symptoms are frequently present along with it. Here, we provide a series of cases involving three siblings who were born into the same consanguineous union and who displayed the typical Joubert syndrome signs, such as missed developmental milestones, mental retardation, visual abnormalities, and chronic renal illness. This case study series intends to draw attention to the rarity of the presentation and importance of early treatment.

CASE SERIES

Case 1

A 12-year-old female child presented to the emergency in an unconscious state. She was the first child to parents with consanguineous marriage. She was born by normal vaginal delivery. The developmental milestones were markedly delayed. She could sit with support at three years and walk with support at seven years. Her speech was impaired, and she had history of difficulty in coordinating her limb movements. She also had history of nocturnal enuresis.

On physical examination, patient was comatose and had rapid deep breathing. Her blood pressure was 96/70 mmHg with pulse rate of 110/min. The laboratory evaluation showed serum creatinine of 9 mg/dl and urea of 220 mg/dl. She also had anaemia (Hb 7.8 g/dl) and severe metabolic acidosis (Bicarbonate 9 mEq). Ultrasound showed bilateral shrunken echogenic kidneys. Patient was initiated

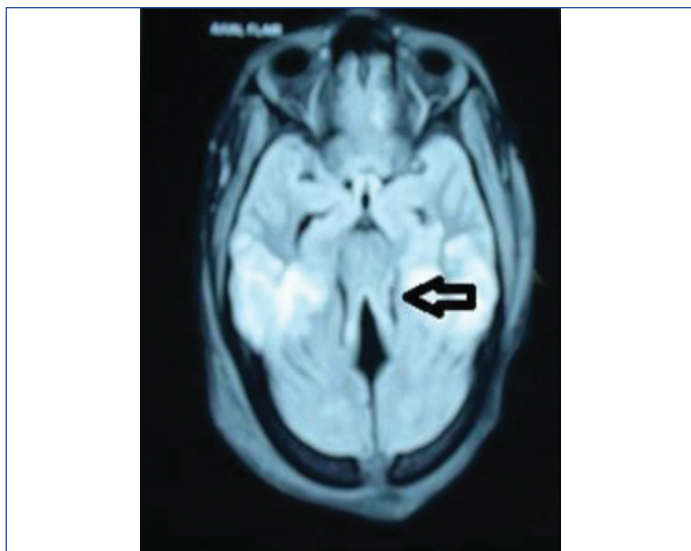
on emergency haemodialysis but developed status epilepticus and succumbed to death. Although no radiological confirmation (MRI) was available, the patient was clinically diagnosed with Joubert syndrome with renal manifestation based on her history of delayed milestones, ataxia, speech abnormalities and evaluation of her younger siblings who showed classical symptoms and signs of Joubert's syndrome.

Case 2

An 11-year-old female younger sibling of case 1 was brought to Nephrology outpatient department with complaint of polyuria and nocturnal enuresis. She was born at term by vaginal delivery. There was history of delayed milestones. She could sit by the age of two years and walk by seven years. Her mother also had noticed that her gait was abnormal, had slurring of speech and abnormal eye movements. On examination, she had a broad forehead, nystagmoid movement of eyes, hypotonia in all limbs and broad-based ataxic gait. There was no oedema, and her blood pressure was normal. Her IQ test revealed a below average score of 70.

The patient's serum creatinine was 8 mg/dL and urea was 140 mg/dL. She had anaemia (Hb 8.4 gm/dL). Ultrasound showed small contracted kidneys with raised echogenicity. Axial images from a brain MRI revealed an abnormally deep interpeduncular fossa, thick, elongated, and poorly aligned superior cerebellar peduncles, and absence of cerebellar vermis, which appeared as a "molar tooth" [Table/Fig-1]. Based on clinical findings, presence of molar tooth sign on MRI and the presence of renal failure, she was diagnosed as a case of Joubert syndrome with renal involvement.

She was initiated on maintenance haemodialysis and supportive care in the form of speech therapy and physiotherapy. Later, she underwent kidney transplantation and is currently doing well on maintenance immunosuppression.



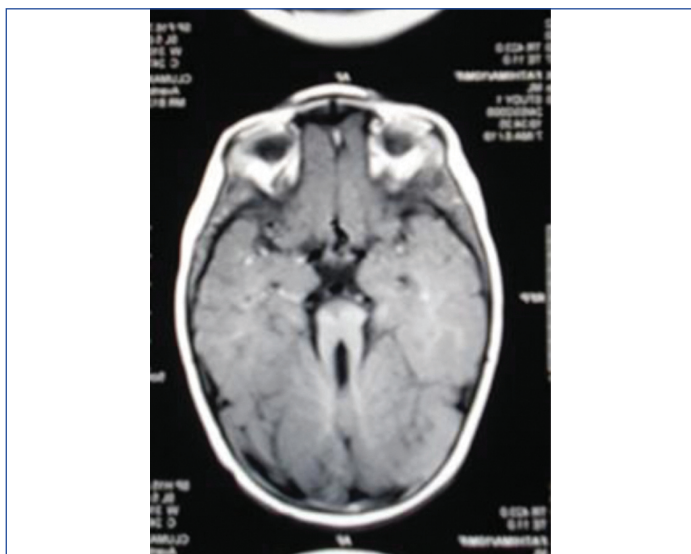
[Table/Fig-1]: MRI axial image-molar tooth sign (case 2).

Case 3

The youngest sibling six-year-old female was brought to the outpatient for evaluation by her parents. She too was born by a normal vaginal term delivery. Her developmental milestones were also delayed she could sit without support by one year and walk at four years. There was slurring of speech.

On examination, she had facial dysmorphism, nystagmus, ataxic gait like her elder sibling. Her blood pressure was normal, and she had no oedema.

Laboratory evaluation showed renal insufficiency with urea of 48 mg/dl and serum creatinine of 2.4 mg/dL. MRI imaging showed the characteristic molar tooth sign [Table/Fig-2]. Ultrasound showed normal sized kidneys with mild raised echogenicity.



[Table/Fig-2]: MRI axial image-molar tooth sign (case 3).

She was initiated on supportive care and physiotherapy and was educated in a special school. Over a period of three years, her serum creatinine progressively worsened and reached to 8 mg/dL by the age of nine years. She was then initiated on maintenance haemodialysis and subsequently underwent kidney transplantation. One year after transplantation she has normal graft function and is on maintenance immunosuppression.

DISCUSSION

Joubert syndrome is a rare genetic disorder characterised by autosomal recessive inheritance. The incidence of this disorder is reported to be 1:100000. The three clinical criteria for diagnosis of Joubert syndrome include Molar tooth sign on MRI, hypotonia/

ataxia, developmental delay/intellectual disability. There are 34 pathogenic gene variants which cause this syndrome of which 33 are autosomal recessive in inheritance and one is X linked [3]. A unique pattern of brain malformation seen on MRI is known as the molar tooth sign. It is due to a combination of midline cerebellar vermis hypoplasia, deepened interpeduncular fossa and elongated superior cerebellar peduncles [2,4]. It is a ciliopathic disorder due to mutations in genes involved in cilia formation and function [5]. Several central nervous system, ophthalmologic, renal, hepatic abnormalities have been reported in Joubert syndrome [6]. Renal disease has been reported in approximately 30% of subjects [7]. Cystic dysplasia and juvenile nephronophthisis are the two causes of renal failure [8]. Cystic dysplasia manifests at birth as immature kidneys with foetal lobulations and multiple cysts on ultrasound. In contrast, juvenile nephronophthisis has microscopic cysts and patient manifests with polyuria, polydipsia, anaemia and renal insufficiency progressing to end stage renal disease by late 1st decade or early 2nd decade of life [9,10].

In this case series, three siblings born to a consanguineous marriage presented with developmental delay, mental retardation, ocular abnormalities, and chronic kidney disease. The second and third siblings were diagnosed with Joubert syndrome based on the characteristic molar tooth sign on MRI and clinical findings. The first sibling could not undergo an MRI due to her early death, but her clinical presentation strongly suggested Joubert syndrome.

There have been individual case reports of renal involvement in Joubert syndrome. Cytic dysplasia and nephronophthisis causing renal failure has been described [11]. Chronic tubulointerstitial nephritis has also been reported in a post mortem biopsy [12], however all three siblings having renal failure is rare and has not been reported. The renal involvement seen in the three siblings highlights the importance of considering this disorder in the differential diagnosis of chronic kidney disease, especially in cases with a family history and other suggestive symptoms. Considering the absence of cysts on ultrasound imaging, history of polyuria in the siblings and echogenic contracted kidneys and end stage renal disease in second decade of life in first two siblings and late 1st decade of life in the third sibling, the kidney involvement could have been possibly due to juvenile nephronophthisis. However, this could not be confirmed by kidney biopsy or genetic analysis. This case series also highlights the need for early recognition of chronic kidney disease and management of the same in this disorder, as early intervention and supportive care can improve the patient's quality of life and prognosis as seen in the second and third siblings.

CONCLUSION(S)

Chronic kidney disease is frequently seen in patients with Joubert syndrome. Early recognition and management can significantly improve the patient's prognosis and quality of life. In this case series, all three siblings developed renal disease where the elder sibling succumbed to death. However, early initiation of treatment of the other two siblings significantly improved their health and quality of life. Further research is needed to increase our understanding of the underlying mechanisms and to develop new therapeutic strategies for this disorder.

REFERENCES

- [1] Alam S, Khatoon F, Khan N. Joubert syndrome: A case report. *Bulletin of Faculty of Physical Therapy*. 2021;26(1):01-03. Doi:10.1186/s43161-021-00039-7.
- [2] Maria BL, Quisling RG, Rosainz LC, Yachnis AT, Gitten J, Dede D, et al. Molar tooth sign in Joubert syndrome: clinical, radiologic, and pathologic significance. *J Child Neurol*. 1999;14(6):368-76. Doi: 10.1177/088307389901400605.
- [3] Parisi M, Glass I. Joubert Syndrome. 2003 Jul 9 [Updated 2017 Jun 29]. In: Adam MP, Mirzaa GM, Pagon RA, et al., editors. *GeneReviews*® [Internet]. Seattle (WA): University of Washington, Seattle; 1993-2023. Available from: <https://www.ncbi.nlm.nih.gov/books/NBK1325/>
- [4] Maria BL, Boltshauser E, Palmer SC, Tran TX. Clinical features and revised diagnostic criteria in Joubert syndrome. *J Child Neurol*. 1999;14(9):583-91. Doi: 10.1177/088307389901400906.

- [5] Parisi MA, Doherty D, Chance PF, Glass IA. Joubert syndrome (and related disorders) (OMIM 213300). *Eur J Hum Genet.* 2007;15(5):511-21. Doi: 10.1038/sj.ejhg.5201648.
- [6] Gleeson JG, Keeler LC, Parisi MA, Marsh SE, Chance PF, Glass IA, et al. Molar tooth sign of the midbrain-hindbrain junction: occurrence in multiple distinct syndromes. *Am J Med Genet A.* 2004;125A(2):125-34. Doi: 10.1002/ajmg.a.20437.
- [7] Saraiva JM, Baraitser M. Joubert syndrome: A review. *Am J Med Genet.* 1992;43(4):726-31. Doi: 10.1002/ajmg.1320430415.
- [8] Satran D, Pierpont ME, Dobyns WB. Cerebello-oculo-renal syndromes including Arima, Senior-Löken and COACH syndromes: more than just variants of Joubert syndrome. *Am J Med genet.* 1999;86:459-69.
- [9] Saunier S, Salomon R, Antignac C. Nephronophthisis. *Curr Opin Genet Dev.* 2005;15(3):324-31. Doi: 10.1016/j.gde.2005.04.012.
- [10] Hildebrandt F, Nothwang HG, Vossmerbäumer U, Springer C, Strahm B, Hoppe B, et al. Lack of large, homozygous deletions of the nephronophthisis 1 region in Joubert syndrome type B. APN Study Group. *Arbeitsgemeinschaft für Pädiatrische Nephrologie. Pediatr Nephrol.* 1998;12(1):16-19.
- [11] Sönmez F, Güzünler-şen M, Yılmaz D, Cömertpay G, Heise M, Çırak S, et al. Development of end-stage renal disease at a young age in two cases with Joubert syndrome. *Turk J Pediatr.* 2014;56(4):458-61.
- [12] Shamsudheen M, Das U, Taduri G, Guditi S, Karthik R, Thakur R. A case of Joubert Syndrome with chronic kidney disease. *Indian J Nephrol.* 2021;31(1):61-63. Doi: 10.4103/ijn.IJN_287_19.

PARTICULARS OF CONTRIBUTORS:

1. Professor, Department of Nephrology, Kasturba Medical College, Manipal Academy of Higher Education, Mangalore, Karnataka, India.
2. Associate Professor, Department of Nephrology, Kasturba Medical College, Manipal Academy of Higher Education, Mangalore, Karnataka, India.

NAME, ADDRESS, E-MAIL ID OF THE CORRESPONDING AUTHOR:

Ashok Bhat,
Associate Professor, Department of Nephrology, KMC Hospital,
Ambedkar Circle, Mangalore, Karnataka, India.
E-mail: ashokbhatdoc@gmail.com

PLAGIARISM CHECKING METHODS: [Jain H et al.]

- Plagiarism X-checker: Mar 09, 2023
- Manual Googling: Apr 01, 2023
- iThenticate Software: Apr 21, 2023 (9%)

ETYMOLOGY: Author Origin**EMENDATIONS:** 6**AUTHOR DECLARATION:**

- Financial or Other Competing Interests: None
- Was informed consent obtained from the subjects involved in the study? Yes
- For any images presented appropriate consent has been obtained from the subjects. Yes

Date of Submission: **Feb 21, 2023**Date of Peer Review: **Apr 12, 2023**Date of Acceptance: **Apr 25, 2023**Date of Publishing: **Jun 01, 2023**