

Severe Acute Necrotising Pancreatitis Presenting as Pancreaticocutaneous Fistula: A Rare Complication

JANHAVI NITIN MAHAJAN¹, KEYUR KISHOR SABOO², YOGESH KAUTIKRAO KAKDE³, SOURYA ACHARYA⁴, SUNIL KUMAR⁵



Keywords: Necrostomy, Pancreatic duct, Fistula, Necrosis

Dear Editor,

Pancreatic glandular necrosis is the most common contributor to severe acute pancreatitis. When necrosis is present, the mortality and morbidity that come with acute pancreatitis are significantly higher, with associated infection in the necrotic area. Pancreatic fistulas generated by a ruptured pancreatic duct can develop following the surgery. In 15-23% of instances, pancreatic fistulas aggravate necrotising pancreatitis [1].

Treatment can range from early surgical debridement ("necrosectomy") to aggressive intensive medical care [2].

This letter is about a 36-year-old male, who came to the casualty with complains of pain in abdomen radiating to his back and associated with distension of abdomen, nausea and 8-10 episodes of vomiting since five days. The patient was a chronic alcoholic. There were no other co-morbidities. He was admitted to the Intensive Medical Care Unit.

On physical examination, the patient was afebrile, tachycardia was present, and abdomen was tender. Investigations revealed serum amylase to be 800 U/L, serum lipase 1400 U/L, total leucocyte count 12.2×10^9 /L, platelets 1.62 lac, and serum calcium 6mg/dl. Ultrasonography (abdomen and pelvis) was suggestive of acute pancreatitis, hepatomegaly with grade II fatty liver, and mild splenomegaly.

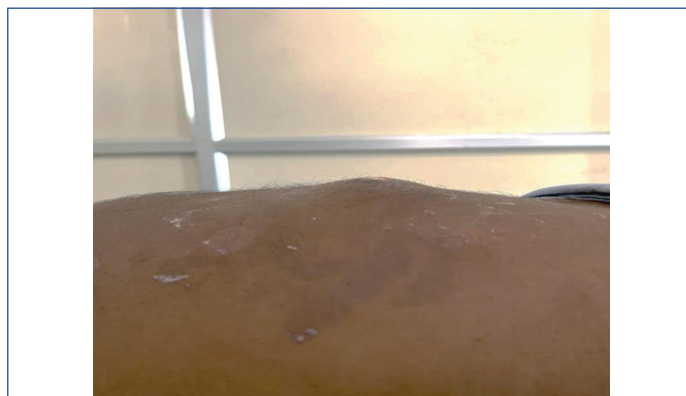The patient was kept nil by mouth and was started on fluid resuscitation, injection Meropenem 1 gm i/v thrice a day, injectable metronidazole 100 ml thrice a day, injection tramadol 100 ml i.v. thrice a day, pancreatin minimicrospheres capsules 25000-10000-10000 IU thrice a day, multivitamin with L-Methionine, and selenium yeast tablets twice a day.

Contrast-enhanced CT abdomen revealed bulky pancreas throughout its course and peri-pancreatic fat stranding and fluid collection abutting lesser curvature of stomach suggestive of acute pancreatitis with necrotic collection, modified CT severity index score was 10.

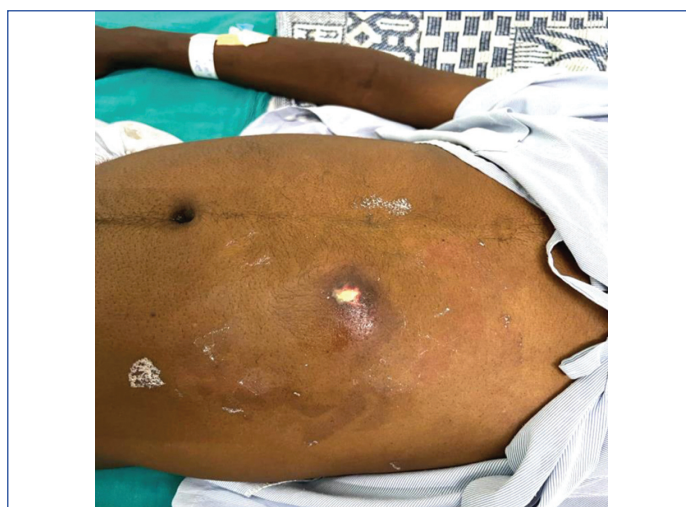Interventional Radiologist's opinion was taken in view of necrotic collection. An USG-guided catheter was inserted, and 300 ml output was obtained in five days. The drain was removed when there was less than 20 mL output per day. The patient developed anterior abdominal wall swelling within three days after the drain was removed [Table/Fig-1].

Local examination revealed pus draining through the catheter insertion site along with anterior abdominal wall swelling [Table/Fig-2]. As the abdominal distension increased CECT abdomen was repeated. It revealed acute pancreatitis with necrotic collection in subcutaneous and intramuscular plane of anterior abdominal wall, in the left hypochondriac and supra umbilical region communicating through a tract [Table/Fig-3].

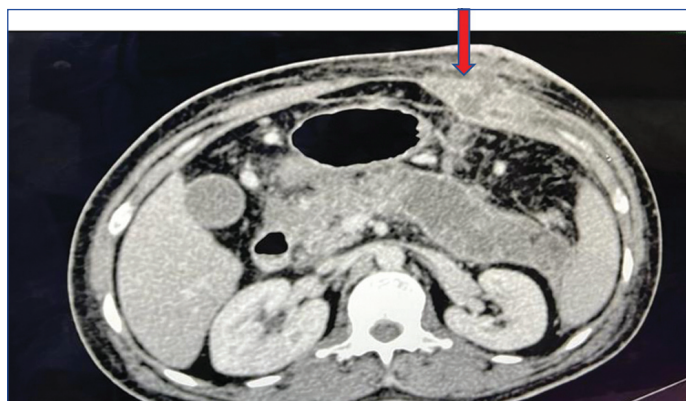The patient was planned for incision and drainage and 50 cc of necrotic material was drained [Table/Fig-4].



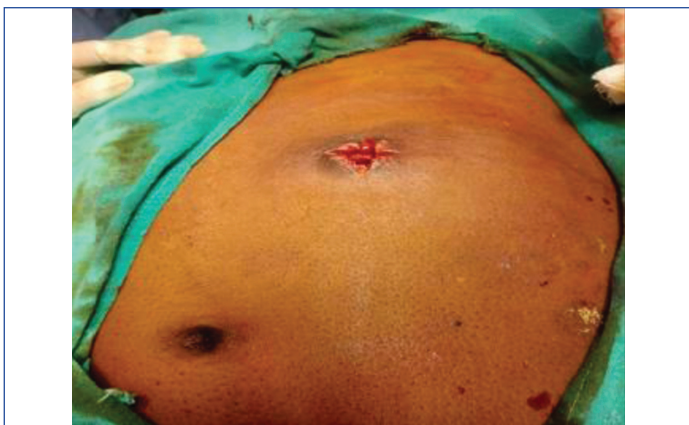
[Table/Fig-1]: Showing anterior abdominal wall swelling.



[Table/Fig-2]: Showing pus draining through the swelling.



[Table/Fig-3]: CECT abdomen: Peripherally enhancing collection in subcutaneous and intramuscular plane of anterior abdominal wall in left hypochondriac and supra umbilical region if 4.2x2.6x3.9 cm. The collection is communicated with the pancreatic collection through a linear tract passing inferior to greater curvature of stomach and closely abducting the peri gastric collateral vessel.



[Table/Fig-4]: Showing intraoperative incision and drainage.

Describe patients condition before discharge and is awaiting follow-up after one month.

This case reports an uncommon complication that happened during the treatment of a reasonably frequent acute surgical illness. Enteroatmospheric fistulas are known to have a notably higher fatality rate than their analogue, enterocutaneous fistulas [3-5]. Pancreaticatmospheric fistulas may present in similar pattern and is associated with high mortality (28.6%) [3]. When compared to

primary open necrosectomy, the Patients with Acute Necrotizing Pancreatitis (PANTER) study found that the minimally invasive step-up method lowered the rate of complications and mortality. In this way, more than one-third of patients were effectively treated with percutaneous drainage only [6].

Management of severe acute necrotizing pancreatitis necessitate multidisciplinary approaches, including resuscitative and supportive measures, as well as prompt management of fistula drainage for optimal wound management with eventual wound coverage and fistula closure.

REFERENCES

- [1] Vasiliadis K, Papavasiliou C, Al Nimer A, Lamprou N, Makridis C. The role of open necrosectomy in the current management of acute necrotizing pancreatitis: a review article. *International Scholarly Research Notices*. 2013;2013:579435.
- [2] Ho HS, Frey CF. Gastrointestinal and pancreatic complications associated with severe pancreatitis. *Arch Surg*. 1995;130(8):817-23.
- [3] Adkins AL, Robbins J, Villalba M, Bendick P, Shanley C. Open abdomen management of intra-abdominal sepsis. *Am Surg*. 2004;70(2):137-40.
- [4] Schein M, Decker GA. Gastrointestinal fistulas associated with large abdominal wall defects: experience with 43 patients. *Br J Surg*. 1990;77(1):97-100.
- [5] Teixeira PG, Inaba K, Dubose J, Salim A, Brown C, Rhee P, et al. Enterocutaneous fistula complicating trauma laparotomy: a major resource burden. *Am Surg*. 2009;75(1):30-32.
- [6] Van Santvoort HC, Besselink MG, Bakker OJ, Hofker S, Boermeester MA, Dejong CH, et al. A step-up approach or open necrosectomy for necrotizing pancreatitis. *N Engl J Med*. 2010;362(16):1491-502.

PARTICULARS OF CONTRIBUTORS:

1. Junior Resident, Department of Medicine, Datta Meghe Institute of Medical Sciences, Wardha, Maharashtra, India.
2. Junior Resident, Department of Medicine, Datta Meghe Institute of Medical Sciences, Wardha, Maharashtra, India.
3. Junior Resident, Department of Medicine, Datta Meghe Institute of Medical Sciences, Wardha, Maharashtra, India.
4. Professor and Head, Department of Medicine, Datta Meghe Institute of Medical Sciences, Wardha, Maharashtra, India.
5. Professor, Department of Medicine, Datta Meghe Institute of Medical Sciences, Wardha, Maharashtra, India.

NAME, ADDRESS, E-MAIL ID OF THE CORRESPONDING AUTHOR:

Janhavi Nitin Mahajan,
DMIMS Hostel, Sawangi, Wardha, Maharashtra, India.
E-mail: drjanhvimahajan96@gmail.com

PLAGIARISM CHECKING METHODS: [Jan H et al.]

- Plagiarism X-checker: Sep 06, 2022
- Manual Googling: Sep 28, 2022
- iThenticate Software: Oct 18, 2022 (10%)

ETYMOLOGY: Author Origin

AUTHOR DECLARATION:

- Financial or Other Competing Interests: None
- Was Ethics Committee Approval obtained for this study? NA
- Was informed consent obtained from the subjects involved in the study? NA
- For any images presented appropriate consent has been obtained from the subjects. No

Date of Submission: **Aug 25, 2022**
Date of Peer Review: **Sep 19, 2022**
Date of Acceptance: **Nov 18, 2022**
Date of Publishing: **May 01, 2023**