



A Functional and Radiological Outcome Analysis of Hip Forage Procedure, done for Early Stages(Ficat and Arlet Grade 1 and 2A) of Avascular Necrosis of Head of Femur

**Shubham Padmawar ^{a#}, Dr. Suhas Landge ^{a#}, Prateek Upadhyay ^{a*†}
and Mitali Madhusmita ^{b‡}**

^a Department of Orthopaedics, Jawaharlal Nehru Medical College, Datta Meghe Institute of Medical Sciences(Deemed to be University), Wardha, Maharashtra, India.

^b Department of Medicine, NKP Salve Institute Of Medical Sciences, Nagpur, Maharashtra, India.

Authors' contributions

This work was carried out in collaboration among all authors. All authors read and approved the final manuscript.

Article Information

DOI: 10.9734/JPRI/2021/v33i54B33770

Editor(s):

(1) Dr. Rafik Karaman, Al-Quds University, Palestine.

Reviewers:

(1) Naveen babu, Sri Maruti Multispeciality Hospital, India.

(2) Ilker Ilhanlı, Ondokuz Mayıs University, Turkey.

Complete Peer review History, details of the editor(s), Reviewers and additional Reviewers are available here:

<https://www.sdiarticle5.com/review-history/78022>

Original Research Article

Received 27 September 2021

Accepted 01 December 2021

Published 11 December 2021

ABSTRACT

Background: Avascular necrosis of the femoral head is a severe disease and causes osteoarthritis of the hip joint in young adults. Early diagnosis leads to better prognosis and therapeutic success.

Aim: To study pain, radiological outcome & functional outcome post hip forage procedure in patients of avascular necrosis of head of femur (Ficat and Arlet grade 1 and grade 2A).

Study Design: This was a prospective observational study.

Place and Duration of Study: Conducted in the Department of Orthopaedics, Dr. D.Y. Patil Medical College, Hospital and Research Centre, Nerul, Navi Mumbai over a period of 2 years from 2015 to 2017

Methodology: We included 50 patients (39 males, 11 females) with Avascular necrosis of

Assistant Professor;

† Post Graduate Resident;

‡ Senior Resident;

*Corresponding author: E-mail: prateekrpp.upadhyay@gmail.com;

unilateral or bilateral head of femur (Grade 1 and Grade 2A), clinical, radiological and functional (with the help of Harris hip score) examination was done at 6 months and 12 months follow up post operatively.

Results: Out of the 50 patients, pre-operatively, 60% reported moderate pain, 20% mild pain and 20% severe pain. At follow-up, 36% patients reported slight pain, 26% mild pain, 26% moderate pain, 8% marked pain, and no pain was reported by 4% patients. Pre-operatively, no limp was seen in 34% patients, while 66% patient had a limp. At follow-up, 70% patient had a limp and no limp in 30% patients. Before surgery, support (cane use) was required by 6% patients, while at follow-up, support was noted by 12% patients. Preoperative mean Harris Hip Score was 63.6, while that at follow-up it was 74.74. Radiological worsening of the disease occurred only in 38% of the patients which suggests that disease progression was delayed in most patients (62%). 2% patients had a complication of foot drop.

Conclusion: Avascular necrosis of femoral head is more common in young males. Core decompression by multiple drilling and/or core decompression with fibular strut grafting are equally effective in pre collapse stages (stage 1 and stage 2A) with better functional and radiological outcomes and hence these procedures can play a vital role in delaying the disease progression.

Keywords: Avascular necrosis; core decompression; fibular strut graft; forage procedure; ficat and arlet classification; osteonecrosis.

ABBREVIATIONS

AVN : Avascular Necrosis
ANFH : Avascular Necrosis of the Femoral Head
HHS : Harris Hip Score
SCFE : Slipped Capital Femoral Epiphysis
ONFH : Osteonecrosis of Femoral Head
THR : Total Hip Replacement

1. INTRODUCTION

Avascular necrosis (AVN) is a pathology that occurs due to a significant decrease in perfusion to the bone combined with an increase in intraosseous pressure [1]. Local or systemic AVN is possible. Primary necrosis of the medial condyle, vertebra, and other small bones are all examples of local AVN. Systemic AVN, on the other hand, appears as a multifocal epiphyseal necrosis or bone infarction [2]. In young adults, AVN is a serious illness that develops osteoarthritis of the hip joint. It is more common in middle-aged patients, ranging between the ages of 30 and 60 [3]. As these are people's productive years, it is a huge economic burden and impacts on the workforce. In addition, 30% to 70% of individuals have both hips involved [4]. Avascular Necrosis of the Femoral Head (ANFH) causes bone cell death, which impairs the repair of microfractures in the femoral head [3]. Loss of perfusion to the head of femur eventually leads to bone marrow and osteocytes death, resulting in the collapse of the necrotic segment [1]. 3/4th of all AVN cases had femoral head collapse after three years of presentation [5]. The exact aetiology of AVN has yet to be determined [2]. In

1934, Phemister proposed the vascular abnormalities to play a major role in the development of ANFH, claiming that embolism and thrombosis can contribute to the development of ANFH [6]. Jones et al discovered a significant frequency of thrombophilic and hypofibrinolytic coagulation disorders in osteonecrosis patients [7]. Intraluminal obliteration of blood vessels caused by small lipid emboli, sickle cells, nitrogen bubbles (Caisson sickness), or localised clotting caused by procoagulant abnormalities are some of the hypothesised processes. Extraluminal obliteration can also be caused by increased marrow fat or raised marrow pressure. Several genetic and environmental factors contribute to the development of AVN [2]. AVN can also occur as a side effect of slipped capital femoral epiphysis (SCFE), which causes significant discomfort, femoral head deformity, and disability [8]. From Gaucher's disease, steroid therapy, ionising radiation, hyperuricemia, alcohol overdose, pancreatitis, to pregnancy, all might be contributory factor towards AVN [4]. Bony necrosis is caused by a lack of arterial supply, obstruction of venous drainage, compression of capillaries in the bone marrow and intraluminal capillary obstruction [4]. Recurrent ischemic attacks on bone are thought to be preceded by an increase in intraosseous pressure, most likely due to oedema, according to current pathophysiology models. Damage to the intraosseous venules and capillaries resulted, resuming a vicious cycle similar to that of the extremities' compartment syndrome [4]. Magnetic resonance imaging (MRI) acts as a great

precision tool for localizing the size and position of necrotic segment; this is important because the risk of collapse is largely reliant on it [2]. Early detection of AVN has been demonstrated to result in a better prognosis and therapeutic success. If neglected, avascular necrosis of the femoral head (ANFH) leads to secondary hip arthritis in 70-80% of patients. In order to keep the hip joint from deteriorating further, it's critical to have a diagnosis and therapy as soon as possible [9]. Many studies have advised treatments based on the symptoms along with Ficat and ARCO classifications [4]. The aim of these therapies is to keep the hip's range of motion and prevent the femoral head from collapsing [8]. If treatment begins early in the condition, non-operative or joint-preserving treatments can improve outcomes [9]. The structural integrity of the subchondral plate in patients with early stages of AVN (i.e., Ficat and Arlet stage I and II), is retained by therapeutic options such as core decompression, avascular or vascularized bone grafting, and different femoral osteotomies. When the femoral head collapses (>2 mm) or there is subsequent degeneration, hip preservation measures become ineffective, and arthroplasty becomes the only viable treatment option. Total Hip Replacement (THR) becomes the only effective therapeutic option as the condition progresses (Ficat and Arlet stages III and IV) [1,9]. The Ficat and Arlet stage must be determined because the treatment and its success are dependent on it; this is evidenced by the fact that, aside from the treatments discussed previously, surface replacement and THR are only advised for patients with stage III lesions [4]. However, due to a lack of data on the outcomes of ANFH treatment modalities in an Indian setting, we organised a study to address this gap. This study was planned with an aim to assess the feasibility of the use of FORAGE procedure (minimally invasive drilling procedure or fibula strut grafting) in ANFH patients and to collect information on its effect of pain, functional and radiological outcome.

2. MATERIALS AND METHODS

The purpose and rationale of the study as well as their role as participants was explained to all patients in the study. All patients gave their written informed consent before being enrolled in the trial. This was a prospective observational study of 50 patients, conducted in the Department of Orthopaedics, Dr. D.Y. Patil Medical College, Hospital and Research Centre,

Nerul, Navi Mumbai over a period of 2 years from 2015 to 2017. This study was conducted in patients of either gender with avascular necrosis head of femur grade 1 and grade 2a fulfilling the eligibility criteria of the study.

2.1 Study Selection Criteria

Inclusion Criteria:- Patients with AVN head of femur grade1 and grade 2A according to Ficat and Arlet classification and patients of either sex older than 18 years and below 50 years of age. Exclusion Criteria: - Patients with AVN head of femur grade 2B, grade 3 and grade 4 (Ficat and Arlet classification) and Patients unwilling to consent.

2.2 Study Procedure

Patients were called for follow-up at 6 and 12 months after surgery during the research. At every visit, thorough clinical and radiological examinations were performed. During the first visit at 6 months period post-operatively, X-ray of pelvis with both hips and MRI of Hip was done. Then only MRI was repeated at 12-month follow-up. Each patient completed a standardized questionnaire to assess subjective characteristics such as pain, functional impairments, and occupational limitations (using Harris Hip score). Harris hip score is meant to evaluate various hip limitations and modalities of therapy in an adult population in domains such as pain, function, absence of deformity, and range of movement. The pain domain assesses the degree of pain, as well as its impact on daily activities and the requirement for pain medication. Daily activities and gait are categorized into the function domain. Hip flexion, adduction, internal rotation, and extremity length discrepancy are measured in the deformity domain, whereas hip range of motion is measured in the range of motion domain. A score of 70 indicates a poor result; 70–80 indicates a fair result, 80–90 indicates a good result, and 90–100 indicates an excellent result. Examining the hip joint for deformity, pain, aberrant mobility, and measuring range of motion were all part of the objective assessment. Pain was measured using Visual analogue scale (VAS) wherein a scale of 0mm to 100mm was marked and each patient was asked to mark the intensity of perception of pain. This was further classified as 0mm – no pain, 1mm to 25mm – slight pain, 26mm to 50mm – mild pain, 51mm to 75mm – moderate pain, 76mm to 100mm – severe pain. The radiographic evaluation was done to monitor the healing of AVN of femur

head in form of X-ray of pelvis with both hip and MRI of hip. Hip range of movements, abduction and adduction, flexion and extension, internal rotation and external rotation, ability to do day-to-day activities were used to assess the functional outcome. Ficat and Arlet classification was used to classify the disease which is as follows:

Stage I Normal

Stage II Sclerotic or cystic lesions

A) No crescent sign

B) Subchondral collapse (crescent sign) without flattening of the femoral head

Stage III Flattening of femoral head

Stage IV Osteoarthritis with decreased joint space with articular collapse.

2.3 Operative Procedures

Core decompression with multiple drill holes- Supine on a fracture table, with the injured leg in

mild internal rotation and the contralateral leg in abduction. An image intensifier was utilised to validate anteroposterior and lateral visibility of the femoral head and neck. Under imaging guidance, a 5 cm incision was made from the tip of the greater trochanter to the lesser trochanter, the Vastus lateralis was divided to expose the femur, and the diseased area of the femur head was drilled with a 4.5 mm drill bit. Multiple drill bits decompress necrotic bone under image guiding.

Core decompression and Fibula strut grafting Patient positioned supine on fracture table with affected leg in slight internal rotation and contralateral leg in abduction. 12 cm incision taken over lateral aspect of leg, Fibular graft harvested, Graft measurement done . Following the similar above approach, Core decompression is done and femoral neck is prepared for femoral strut with a reamer , fibular strut graft is placed in the prepared tract.

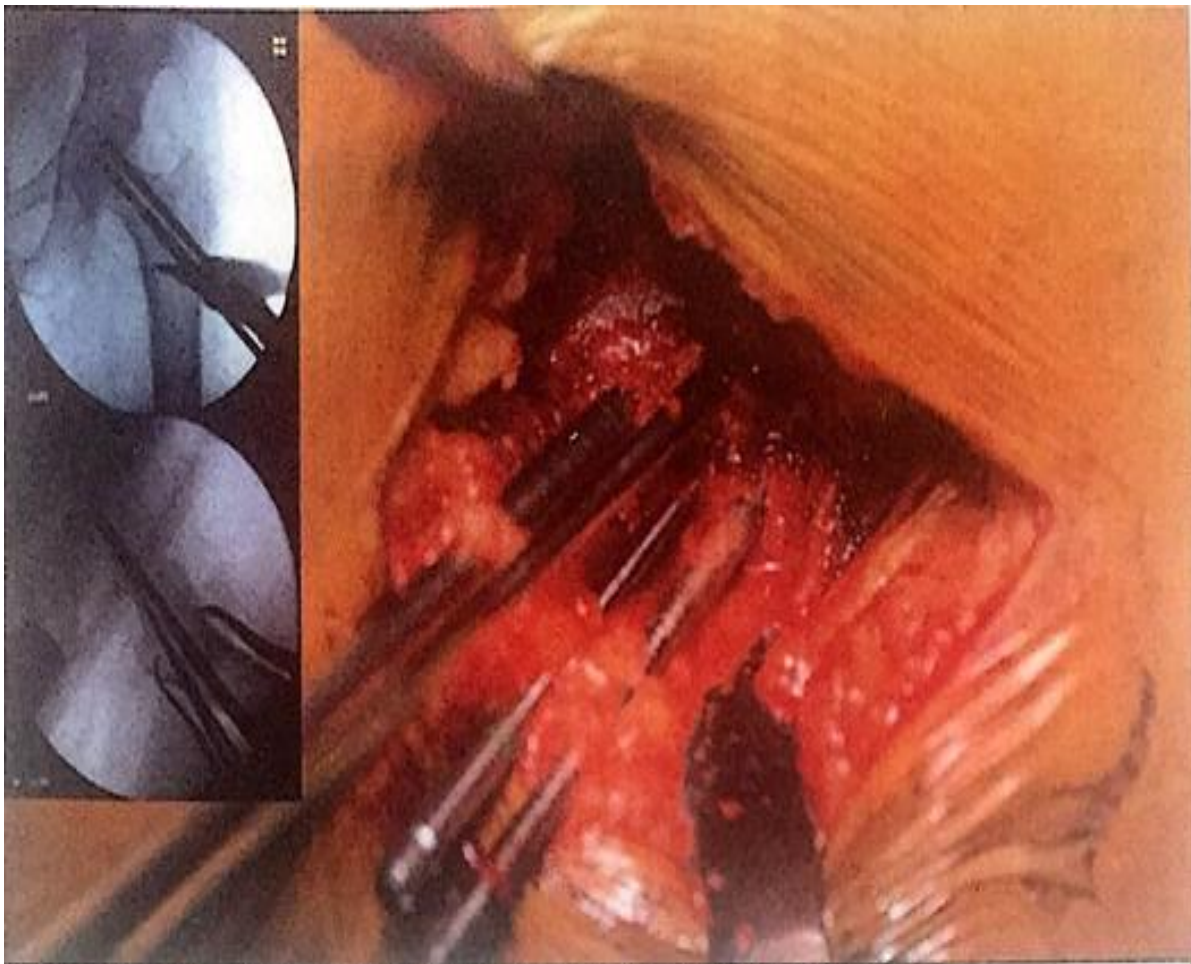


Fig. 1. Shows Decompression of necrotic bone by multiple drill bits under image guidance

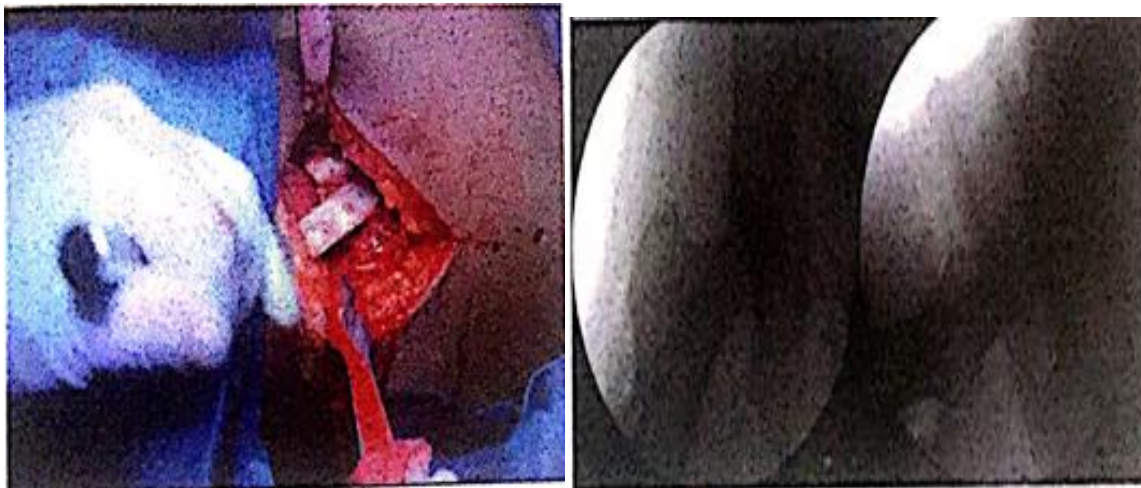


Fig. 2. Shows Placement of fibular strut graft in the prepared tract

3. RESULTS

The categorical data was analysed using the Chi-square test. For parametric correlation analysis, the Pearson correlation test was employed, whereas for non-parametric correlation analysis, the Spearman correlation test was utilised.

Preoperative and follow-up limp was compared using the chi-square test. We observed a

statistically significant improvement ($P= .01035$) between preoperative and follow-up limp among our patients.

Preoperative and follow-up support was compared using the chi-square test. No statistically significant difference ($P = .29$) was observed between preoperative and follow-up support among our patients.

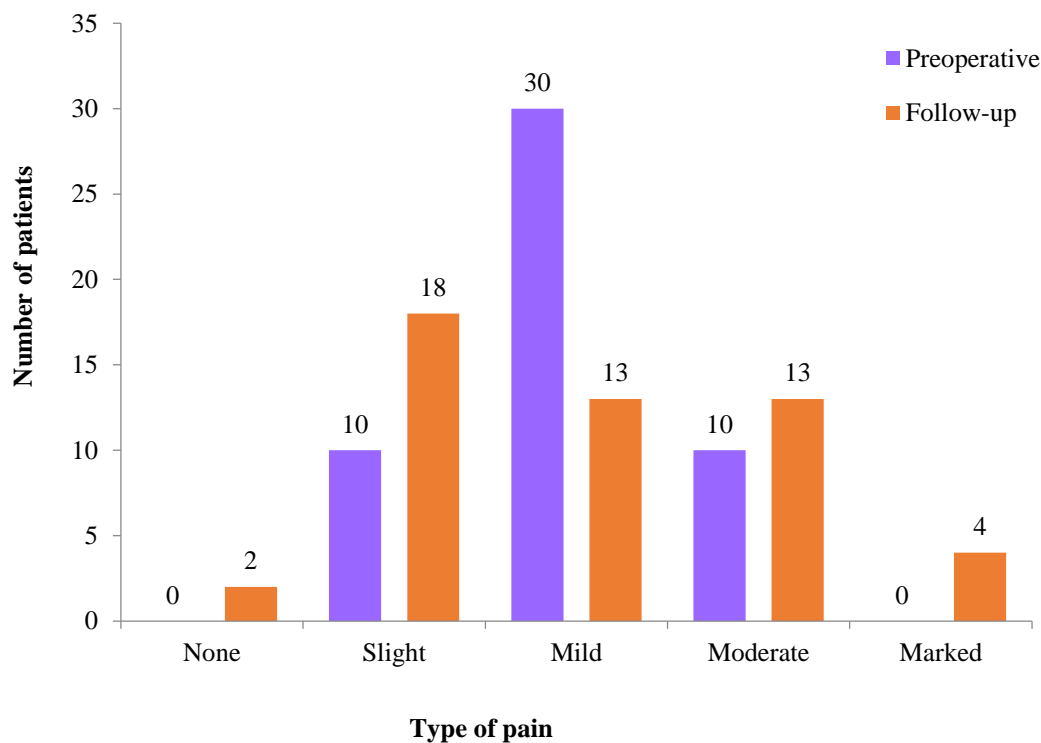


Fig. 3. Shows comparison between preoperative and follow-up pain

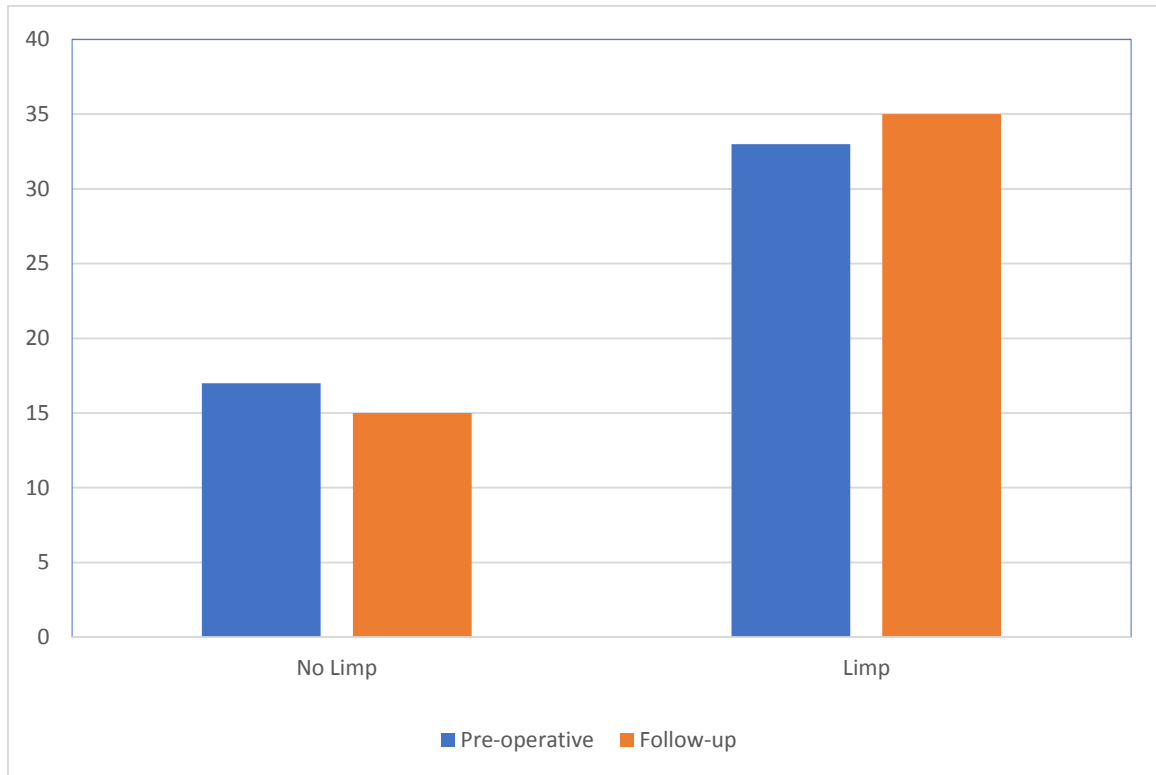


Fig. 4. Shows comparison between preoperative and follow-up limp

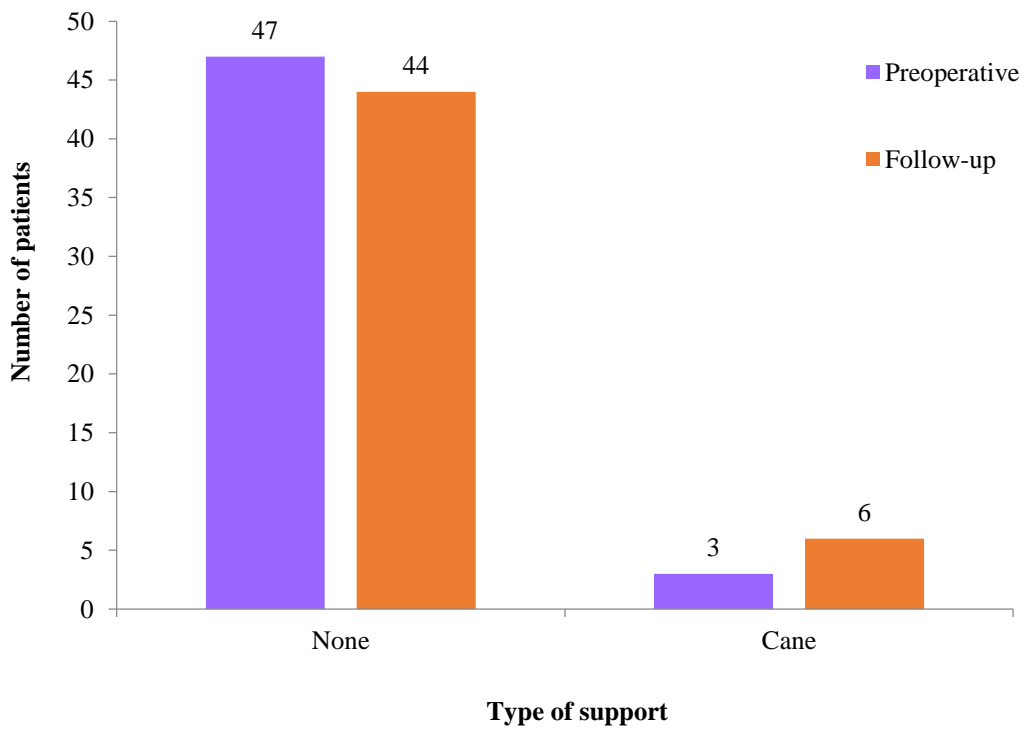


Fig. 5. Shows comparison between preoperative and follow-up support

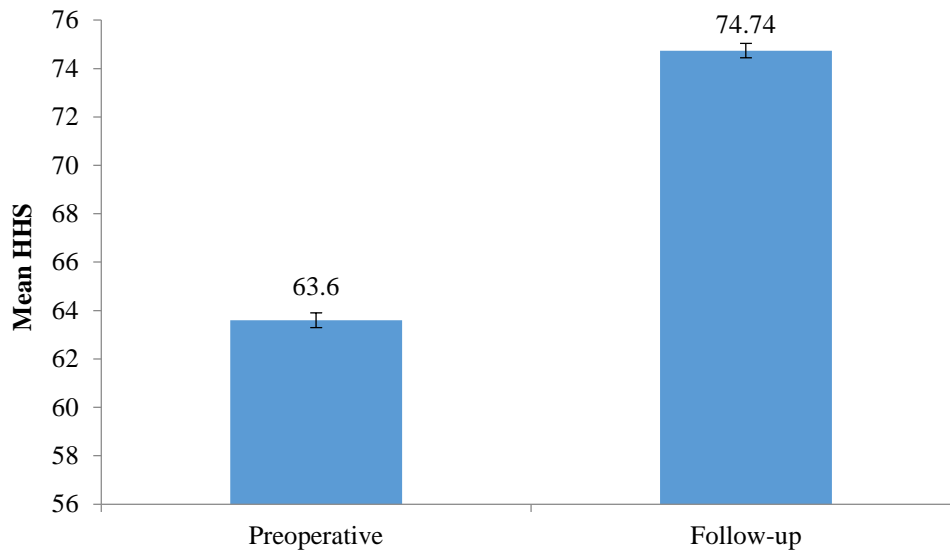


Fig. 6. Shows comparison between preoperative and follow-up mean HHS

Table 2. Comparison between preoperative and follow-up radiologic score

Radiologic score	Preoperative		Follow-up	
	Right	Left	Right	Left
1	10	13	4	7
2A	23	27	23	18
2B	0	0	5	9
3	0	0	1	4
Nil	17	10	17	12

The above figure shows an overall increase in the Harris Hip score which is indicative of a better functional outcome post decompression. Preoperative and follow-up mean HHS was compared using the t-test. A statistically significant difference ($P < .0001$) was observed between the mean preoperative and follow-up HHS scores among our patients.

Above table shows that radiological worsening of the disease occurred only in 38% of the patients which suggests that disease progression was delayed in most patients (62%)

4. DISCUSSION

ANFH is a chronic, potentially debilitating condition with a comprehensive array of aetiologies and a poorly understood pathogenesis. A consensus concerning the ideal algorithm to treat patients at different phases of the illness is lacking. During the early stages, joint preserving procedures like percutaneous drilling or core decompression might perfusion to the necrotic area by decreasing the intraosseous

pressure, consequently relieving pain and enhancing function [10]. The Ficat and Arlet system was the first classification system for ANFH [11]. Because the subchondral plate's structural integrity is still preserved in patients with early stages of AVN (i.e. ficat and arlet stage 1 and 2A), joint-preserving operations could be used primarily [12]. Multiple small drilling for core decompression was presented in 2003 as a safe, minimally invasive, and successful treatment for ANFH, with findings showing a decreased rate of collapse (14.3 percent) compared to typical core decompression procedures (45 percent) 3 years following surgery [13]. The present study was designed to evaluate the feasibility of forage procedure (use of minimally invasive drilling procedure or fibular strut grafting) in ANFH patients and to collect information on its effect of pain, functional and radiological outcome.

We observed idiopathic risk factors in most of our study patients (60%; 30/50), followed by alcohol (16%; 8/50) patients, trauma (12%; 6/50), and smoking and steroids in 6% (3/50) patients each. Majority (12/20) of the patients evaluated by

Shah et al were alcoholics, 1 patient had AVN after chronic steroid use, 1 was infected with HIV and no cause could be identified in 6/20 patients [14].

Similar risk factors were identified by *Yoon et al*: alcoholism (20/31 patients), steroid overdose (10/31 patients) and idiopathic (9/31 patients) [15]. The distribution of similar risk factors leading to AVN reported by *Maniwa et al* were: idiopathic (8/19), steroid related (7/19), alcohol (1/19), trauma (1/19) among others [16]. According to Marker et al., alcohol consumption and corticosteroid use have been widely highlighted as risk factors in several research [12].

In the present study, pre-operatively, most patients (60%; 30/50) reported moderate pain, while 20% (10/50) patients each reported mild and marked pains. At follow-up, 36% (18/50) patients reported slight pain, 26% (13/50) patients each reported mild and moderate pains, 8% (4/50) reported marked pain, while no pain was reported by 4% (2/50) patients.

Out of 28 hips treated by *Shah SN et al*, 15 of the 20 patients presented within 6 months of the onset of pain; 26 hips reported relief in pain instantaneously post-surgery. At 3 months follow-up, 22 hips had complete pain relief with no pain in 19 hips at 6 months and final follow-up [14].

The preoperative mean HHS among our study patients was 63.6 ± 8.94 , while that at follow-up was 74.74 ± 14.69 ; a statistically significant difference ($p < 0.0001$) was observed between the mean preoperative and follow-up HHS among our patients, indicating a significant improvement. *Kim et al* reported the average preoperative and last HHS as 86.7 to 73.7 in the core decompression group as compared to 87.0 and 74.6 in the multiple drilling group [13]. *Shah SN et al* found that, of the 20 hips that improved, the average preoperative HHS was 71.18 which increased to 88.23 at final follow-up. Whereas for the remaining 8 hips that did not show improvement the average preoperative HHS was 58.03 that reduced to 47.68 at final follow-up, indicating deterioration [14].

In the present study, among the patients with right hip involvement: radiologic score of 1 was seen in 10 patients preoperatively and in 4 patients at follow-up; radiologic score of 2A was seen in 23 patients preoperatively which

remained the same at follow-up; radiologic score of 2B was not seen in any patients preoperatively but in 5 patients at follow-up; radiologic score of 3 was not seen in any patients preoperatively but in 1 patient at follow-up; nil radiologic score was seen in 17 patients preoperatively as well as at follow-up. Among those patients with left hip involvement: radiologic score of 1 was seen in 13 patients preoperatively and in 7 patients at follow-up; radiologic score of 2A was seen in 27 patients preoperatively and in 18 patients at follow-up; radiologic score of 2B was not seen in any patients preoperatively but in 9 patients at follow-up; radiologic score of 3 was not seen in any patients preoperatively but in 4 patients at follow-up; nil radiologic score was seen in 10 patients preoperatively and in 12 patients at follow-up. In the study by *Shah SN et al*, grading was done as per the Ficat & Arlet grading system: there were 13 hips (46.42%) of grade I, 11 hips (39.28%) of grade IIA and 4 hips (14.28%) were grade IIB [13]. In the study by *Maniwa et al*, 10/26 hips had stage I while 16 had stage II of the disease. Using the Ficat criteria, they observed that 65.4% hips had very good or good results [15]. *Yoon TK et al* observed 17/39 hips with Ficat grade I, 14/39 hips with Ficat grade 2 and 8/39 hips with Ficat grade 3 [15].

5. CONCLUSION

Young males are more likely to develop avascular necrosis of the femoral head. When performed in the early stages of disease (stages 1 and 2A), core decompression by repeated drilling or core decompression with fibular strut grafting are equally successful in lowering pain and increasing the patient's capacity to do daily activities. It was also discovered that radiological results improved in a few individuals after the operation, indicating that early interventions may have the potential to prevent disease development and the necessity for replacement surgery. The information gathered in this study will aid clinicians in determining the appropriate course of action in the future.

CONSENT AND ETHICAL APPROVAL

Following permission from the Institutional Ethics Committee, the study was launched. (Ref.No. PDDYPMC/Ethics/PG Dissert/2015). As per international standard or university standard guideline patient's has been collected and preserved by the authors.

COMPETING INTERESTS

Authors have declared that no competing interests exist.

REFERENCES

1. Rackwitz L, Eden L, Reppenhagen S, Reichert JC, Jakob F, Walles H et al. Stem cell-and growth factor-based regenerative therapies for avascular necrosis of the femoral head. *Stem cell research & therapy*. 2012;3(1):1-9.
2. Lafforgue P. Pathophysiology and natural history of avascular necrosis of bone. *Joint Bone Spine*. 2006;73(5):500-7.
3. Pouya F, Kerachian MA. Avascular necrosis of the femoral head: are any genes involved?. *Archives of bone and joint surgery*. 2015;3(3):149.
4. Schmitt-Sody M, Kirchhoff C, Mayer W, Goebel M, Jansson V. Avascular necrosis of the femoral head: inter-and intraobserver variations of Ficat and ARCO classifications. *International orthopaedics*. 2008;32(3):283-7.
5. Agarwala S, Shah S, Joshi VR. The use of alendronate in the treatment of avascular necrosis of the femoral head: follow-up to eight years. *The Journal of bone and joint surgery*. British volume. 2009;91(8):1013-8.
6. Phemister DB. Fractures of the neck of femur, dislocations of hip, and obscure vascular disturbances producing aseptic necrosis of head of femur. *Surg Gynecol Obstet.* 1934;59:415-40.
7. Jones LC, Mont MA, Le TB, Petri M, Hungerford DS, Wang P, Glueck CJ. Procoagulants and osteonecrosis. *The Journal of rheumatology*. 2003;30(4):783-91.
8. Mullins MM, Sood M, Hashemi-Nejad A, Catterall A. The management of avascular necrosis after slipped capital femoral epiphysis. *The Journal of bone and joint surgery*. British volume. 2005;87(12):1669-74.
9. Tripathy SK, Goyal T, Sen RK. Management of femoral head osteonecrosis: Current concepts. *Indian journal of orthopaedics*. 2015;49(1):28-45.
10. Issa K, Pivec R, Kapadia BH, Banerjee S, Mont MA. Osteonecrosis of the femoral head: the total hip replacement solution. *The bone & joint journal*. 2013;95(11_Supple_A):46-50.
11. Ficat RP. Idiopathic bone necrosis of the femoral head. Early diagnosis and treatment. *The Journal of bone and joint surgery*. British volume. 1985;67(1):3-9.
12. Marker DR, Seyler TM, Ulrich SD, Srivastava S, Mont MA. Do modern techniques improve core decompression outcomes for hip osteonecrosis?. *Clinical orthopaedics and related research*. 2008;466(5):1093-103.
13. Kim SY, Kim DH, Park IH, Park BC, Kim PT, Ihn JC. Multiple drilling compared with standard core decompression for the treatment of osteonecrosis of the femoral head. In *Orthopaedic proceedings*. The British Editorial Society of Bone & Joint Surgery. 2004;86(SUPP_II):149-149
14. Shah SN, Kapoor CS, Jhaveri MR, Golwala PP, Patel S. Analysis of outcome of avascular necrosis of femoral head treated by core decompression and bone grafting. *Journal of clinical orthopaedics and trauma*. 2015;6(3):160-6.
15. Yoon TR, Song EK, Rowe SM, Park CH. Failure after core decompression in osteonecrosis of the femoral head. *International orthopaedics*. 2001;24(6):316-8.
16. Maniwa S, Nishikori T, Furukawa S, Kajitani K, Iwata A, Nishikawa U, Ochi M. Evaluation of core decompression for early osteonecrosis of the femoral head. *Archives of orthopaedic and trauma surgery*. 2000;120(5-6):241-4.

© 2021 Padmawar et al.; This is an Open Access article distributed under the terms of the Creative Commons Attribution License (<http://creativecommons.org/licenses/by/4.0>), which permits unrestricted use, distribution, and reproduction in any medium, provided the original work is properly cited.

Peer-review history:
The peer review history for this paper can be accessed here:
<https://www.sdiarticle5.com/review-history/78022>